

‘Complex epilepsy phenotype associated with chromosome 2q.24.2-2q24.3 deletion involving sodium channel gene cluster.’

Rima Madan^{1*} (rima.madan@yale.edu), Fiorella S. Guido^{2*} (guidof@upstate.edu), Nicole Brescia² (brescian@upstate.edu)

ORCID ID: 0000-0002-4353-5940

¹ Department of Pediatric Neurology, Yale School of Medicine, New Haven, Connecticut

² Department of Neurology, SUNY Upstate Medical University, Syracuse, NY

*Co-first authors contributed equally to the work

The authors have no conflicts of interest to disclose. Written informed consent was obtained from the parent to publish this report in accordance with the journal's patient consent policy.

Key Clinical Message:

The 2q chromosome region encodes the cluster of sodium channel genes important in severe childhood epilepsy phenotypes. Our case examines the extent that 2q24.3-24.3 gene deletions contribute to our patient's complex medically refractory epilepsy and supports the use of fenfluramine and ketogenic diet as an effective treatment for these patients.

INTRO:

The 2q24.2-24.3 chromosome region encodes the cluster of sodium channel genes, which are important in severe childhood epilepsy phenotypes such as Dravet syndrome and migrating partial seizures of infancy.¹ Dravet syndrome is a treatment-resistant developmental epileptic encephalopathy that is characterized by multiple types of seizures including bouts of debilitating status epilepticus.² SCN1A variants are a frequent cause of Dravet Syndrome, and variants of other genes in the cluster (SCN2A and SCN3A) have also been implicated in complex epilepsy phenotypes.³ However, the role of other genes within the cluster (SCN7A and SCN9A) or in segments proximal to it have not clearly been delineated.¹ Due to the large size of chromosome 2, partial monosomy of the long arm yields many specific phenotypes including delayed growth, mental retardation, early myoclonic seizures, and even dysmorphic facial features.⁴

While many typical cases of Dravet syndrome do not involve SCN2A and SCN3A, complex epilepsy phenotypes shared with migrating partial seizures of infancy were associated with deletions of the whole sodium channel gene cluster.¹ Treatment options for both Dravet syndrome and complex epilepsy phenotypes are limited. These patients often have medically refractory epilepsy, even with multimodal therapy.⁵ The ketogenic diet is known to be useful in cases where pharmacological treatment or surgery was ineffective. The anticonvulsant mechanisms of the ketogenic diet are not completely understood, but it is based on the concept that ketone bodies act as an alternative source of energy in the brain in place of glucose. Brain tissue under the influence of a ketogenic diet is thought to be more resistant to metabolic stress, thus increasing the seizure threshold.⁶

Another promising therapy emerging for treatment resistant seizures is the drug fenfluramine. The mechanisms of action are under active investigation, however it is known that fenfluramine is a potent serotonin-releasing agent with activity at several 5-HT receptor subtypes.⁷ Reports in zebrafish model of Dravet syndrome shows fenfluramine restores dendritic arborization, suggesting its potential for reduction in seizure activity.⁷ In 2020, fenfluramine was approved for treatment of Dravet syndrome in the USA and Europe based on the results of 3 clinical trials that demonstrated reduction of the number monthly convulsive seizures by 54% to 65% compared to placebo.⁷ This suggests that fenfluramine is an important new treatment option for patients with Dravet syndrome and potentially other developmental and epileptic encephalopathies.⁷ However, there is little information about the potential efficacy of the combination of the ketogenic diet and fenfluramine in patients with complex epilepsy phenotypes involving larger deletions of chromosome 2.

Our report demonstrates the extent of the deletion within the 2q24.3-24.3 chromosome region influences the severity of the complex phenotype of our patient with Dravet Syndrome.

Additionally, our case adds to the literature that the combination of fenfluramine and the ketogenic diet is an effective treatment for patients with medically refractory epilepsy.

METHODS:

Extensive genetic, metabolic, and electrodiagnostic studies were undertaken. A SNP-microarray showed a 4,259 kbp deletion of the long arm of chromosome 2 at band q24.2-24.3 in 98% of our patient's cells. According to the Invitae epilepsy panel, the 14 deleted genes include SCN1A, SCN2A, SCN3A, SCN7A, SCN9A, IFIH1, GCA, KCNH7, FIGN, COBLL1, GRB14, SLC 38A11, GALNT3, and TTC21B. Additionally, a 118 kbp deletion of the short arm of chromosome X at band p11.23 was also detected, including ZNF630 and SSX6.

The Case:

Our patient is a 2 year old ex-39 week male who is a product of nonconsanguineous parents via in vitro fertilization and a surrogate pregnancy. His pregnancy and birth history are significant for placenta previa that self-resolved, being born via c-section due to breech presentation and requiring observation in the NICU for 1 night due to low oxygen saturation without requiring respiratory support. He has no history of CNS infection, head trauma or family history of epilepsy or developmental impairments.

His seizures began as febrile seizures at 6 months of age and have become intractable. Previously, he had clusters of focal motor seizures occurring up to 60 times a month at his worst. His seizures are characterized by the patient crying out with his bilateral arms and legs stiffening and shaking, followed by oxygen desaturation and apnea for 30 seconds up to 2 minutes. These seizures were exacerbated by fluctuation in body temperature. He failed levetiracetam, topiramate, phenobarbital, cannabidiol and valproic acid. Titration of clobazam resulted in reduction of seizures to approximately 10 seizures per month. However, he developed excessive somnolence, tolerance to benzodiazepines making rescue medications less effective and continued to have status epilepticus characterized by clusters of seizures accompanied by apnea every 3 to 4 weeks requiring hospitalization and intubation.

At 20 months, he was started on the classic ketogenic diet at a 4:1 ratio and generated and maintained adequate ketosis. A few weeks later, at 21 months he was started on fenfluramine and the dose was subsequently optimized. His seizures have reduced to clusters of 3-4 seizures every 4-6 weeks (>50% reduction) that are no longer accompanied by apnea and are responsive to rescue midazolam. He no longer requires hospitalizations for status epilepticus and his and his family's quality of life has greatly improved. Developmentally, he is gastrostomy tube dependent, non-verbal, non-ambulatory and has significant hypotonia, dysphagia, and profound global developmental delay.

The patient's plasma amino acids, creatinine kinase, and lipid panel were normal. His electromyography study was borderline normal, displaying several motor units in the tongue as larger than normal without significant reduced recruitment. Repeat electromyography study was done, which was normal. Due to the focal onset of seizures, MRI brain was done, which was unremarkable.

Table 1 demonstrates multiple cases with complex epilepsy phenotypes that share similar genetic deletions to our patient.

	Case 1 ¹	Case 2 ¹	Case 3 ¹	Case 4 ¹	Case 5 ¹	Case 6 ⁸	Case 7 ⁹	Our Case
Age of onset	3 mo	1 mo	2 mo	7 mo	4 mo	2 mo	9 mo	6 mo
Age at last follow-up	5 yr 8 mo	2 yr 5 mo	1 yr 3 mo	2 yr 9 mo	9 yr 8 mo	3 mo. Expired.	9 mo	1 yr 9 mo
Hypotonia	-	-	-	-	-	+	+	+
Seizure type	MF, autonomic	MF, My, TC	MF, HC, autonomic	TC Fever HC Fever	HC, TC	MMPSI	None	FM
Multifocal EEG	+	+	+	-	+	+	+	+
Seizure outcome	refractory	refractory	refractory	response to LEV	refractory	refractory	N/A	refractory
Brain MRI	progressive diffuse atrophy	mild diffuse atrophy	mild diffuse atrophy	normal	mild diffuse atrophy	mildly enlarged ventricles, age delated myelination	normal	normal
Chromosomal Deletion	2q24.3	2q24.3	2q24.3	2q24.3	2q24.3	2q22.1- q33.3	2q24.2- q24.3	2q24.2- q24.3
Deletion size by CGH array	8.4 Mb	4.3 Mb	1.5 Mb	0.2 Mb	0.2 Mb	10.4 Mb	5.2 Mb	4.259 Mb
Deleted Genes	SCN1A, SCN2A, SCN3A, SCN 7A, SCN 9A	SCN1A, SCN2A, SCN3A, SCN 7A, SCN 9A	SCN1A, SCN2A, SCN3A, SCN 7A, SCN 9A	SCN1A	SCN1A, SCN9A	SCN1A, SCN2A, SCN3A, SCN 7A, SCN 9A, GRB14, COBLL1, GALNT3, + 44 other genes	SCN2A, SCN3A, ITGB6; TBR1; SLC4A10; KCNH7	SCN1A, SCN2A, SCN3A, SCN 7A, SCN 9A, IFIH1,GCA, KCNH7, FIGN, GRB14, COBLL1, SLC38A11, GALNT3, TTC21B Xp11.23 L→ ZNF630, SSX6

Table 1: Characteristics of patients with 2q24.3 deletion

Key: CGH, comparative genomic hybridization; TC, tonic-clonic seizure; FC, focal clonic seizure; HC, hemiclonic seizure; MF, multifocal seizures; My, myoclonic seizure; LEV, levetiracetam; FM, focal motor; MMPSI, malignant migrating partial seizures in infancy

Our patient's video EEG findings at 11 months in Figures 1 and 2 display focal seizure activity over the left and right parietal regions. During this study, he had five clinical seizures originating over the left parietal region, and one clinical seizure originating over the right parietal region. All seizures occurred during wakefulness and were characterized by bilateral tonic arm

extension and an ictal cry. He would often pick at his blankets or grabbed at his left hand with his right hand. Our figure shows frequent independent spike/sharp and wave discharges over the biparietal, bioccipital, and bitemporal regions. As well as occasional, simultaneous spike and wave discharges over the bilateral parieto-occipital regions.

EEG FINDINGS

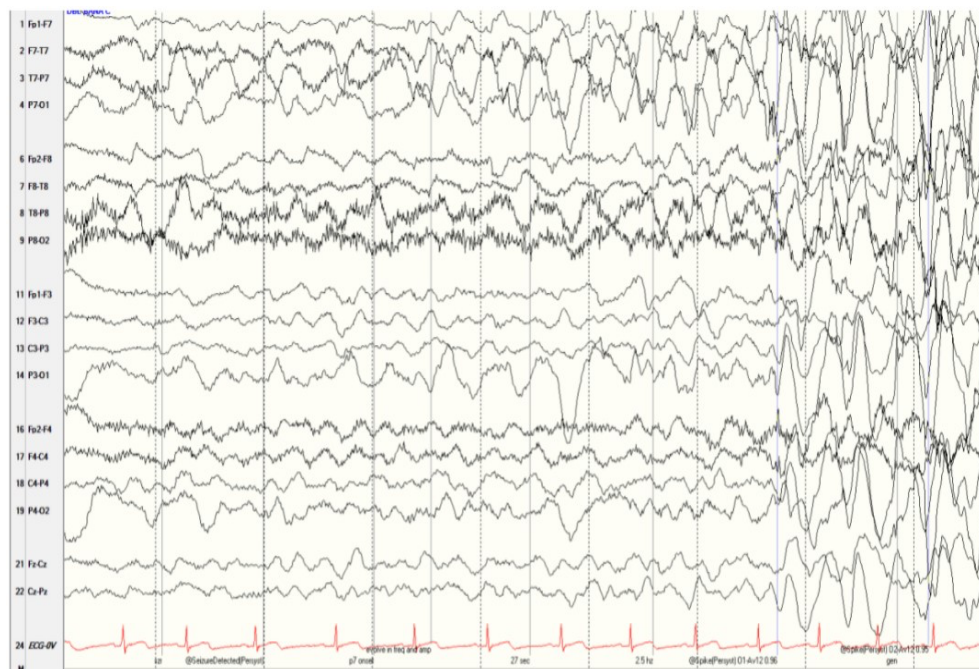


Figure 1: Focal seizure with origin over left parietal region (12/25/19)

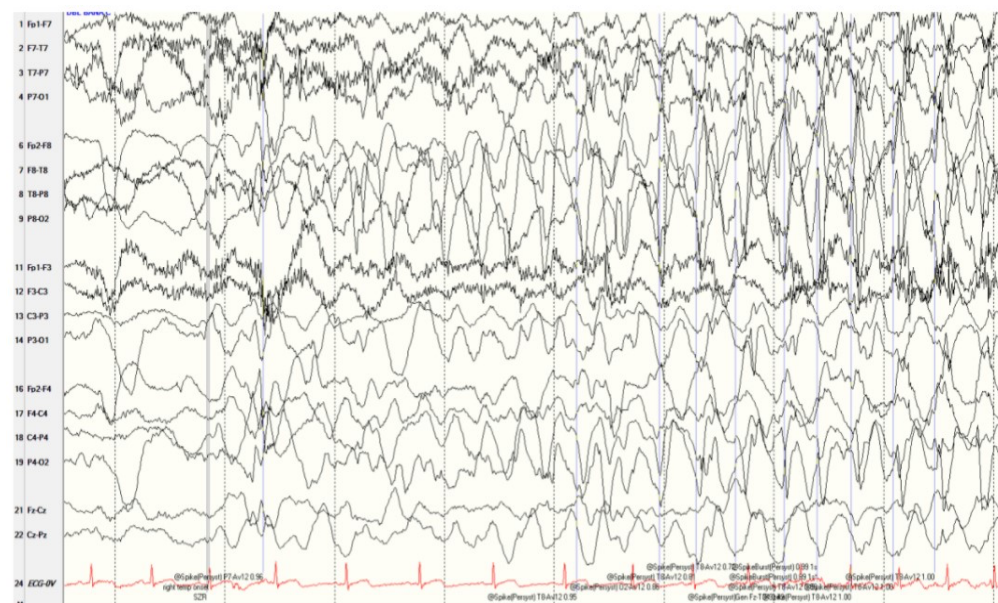


Figure 2: Focal seizure with origin over right parietal region (12/25/19)

DISCUSSION

Based on other children reported in the literature, the extent of the 2q24.2-2q24.3 deletion likely plays a role in the severity of our patient's presentation. Patients who have different deletions within this region of chromosome 2 have demonstrated a variety of clinical presentations, including generalized hypotonia occurring with or without seizures.⁹ There are also patients exhibiting larger deletions of the 2q24.3-2q31.1 region who have atonic and hypomotor seizures.³ Most cases of Dravet Syndrome arise from SCN1A variants. However, it is crucial to identify other genes that may contribute to the complexity of the patient's epileptic phenotype in order to guide additional therapeutic strategies.¹⁰ Precision medicine and targeted gene therapy can offer higher therapeutic value for our patients, allowing us to set a new standard for treatment of devastating conditions such as Dravet syndrome.⁷ Our case report contributes to the limited body of literature that segments near and within the sodium channel gene cluster may have important clinical implications in patients with complex epilepsy phenotypes.

Our case also supports the use of fenfluramine and ketogenic diet as an effective treatment for patients with medically refractory epilepsy. Fenfluramine can significantly reduce convulsive seizure frequency, and is generally well tolerated.² The severity of Dravet syndrome can cause patients and their families to experience a poor quality of life, and existing literature supports fenfluramine's favorable benefit-risk profile.^{5,7} It is important to note that the efficacy of fenfluramine may be attributable to the high number of patients who share common genetic etiology, considering that up to 85% of patients with Dravet syndrome have mutations in the SCN1A gene.⁷ Furthermore, the ketogenic diet can also significantly reduce and, in some cases, eliminate seizures in patients with medically refractory epilepsy.⁶ An important limitation of our case report is that the fenfluramine and ketogenic diet were started within a few weeks of each other and so it is difficult to assess which was more effective for our patient. Our patient's quality of life was significantly improved with the introduction of this drug and dietary therapy, and these should be considered as an addition to current antiepileptic regimens.

Authorship Contributions

Rima Madan, MD and Fiorella Guido MS4: acquisition and interpretation of the data, drafting the manuscript, and creating figures

Nicole Brescia, MD: supervising physician, responsible for interpretation of data, editing manuscript, and overseeing case report

References

1. Lim BC, Hwang H, Kim H, et al. Epilepsy phenotype associated with a chromosome 2q24.3 deletion involving SCN1A: Migrating partial seizures of infancy or atypical Dravet syndrome?. *Epilepsy Res.* 2015;109:34-39. doi:10.1016/j.epilepsyres.2014.10.008
2. Lagae L, Sullivan J, Knupp K, et al. Fenfluramine hydrochloride for the treatment of seizures in Dravet syndrome: a randomised, double-blind, placebo-controlled trial. *Lancet.* 2019; 394(10216):2243-2254. doi:10.1016/S0140-6736(19)32500-0
3. Okumura, A., Yamamoto, T., Kurahashi, H., & Takasu, M. Epilepsies in Children with 2q24. 3 Deletion/Duplication. *Journal of Pediatric Epilepsy.* 2015; 4(01), 008-016.

4. Takatsuki S, Nakamura R, Haga Y, et al. Severe pulmonary emphysema in a girl with interstitial deletion of 2q24.2q24.3 including ITGB6. *Am J Med Genet A*. 2010; 152A(4):1020-1025. doi:10.1002/ajmg.a.33362
5. Lagae L, Brambilla I, Mingorance A, Gibson E, Battersby A. Quality of life and comorbidities associated with Dravet syndrome severity: a multinational cohort survey. *Dev Med Child Neurol*. 2018; 60(1):63-72. doi:10.1111/dmcn.13591
6. Ułamek-Kozioł M, Czuczwar SJ, Januszewski S, Pluta R. Ketogenic Diet and Epilepsy. *Nutrients*. 2019; 11(10):2510. <https://doi.org/10.3390/nu11102510>
7. Sullivan J, Helen Cross J. Raising the bar: Fenfluramine sets new treatment standards for Dravet syndrome. *Epilepsy Behav*. 2021; 121(Pt A):108061. doi:10.1016/j.yebeh.2021.108061
8. Davidsson J, Collin A, Olsson ME, Lundgren J, Soller M. Deletion of the SCN gene cluster on 2q24.4 is associated with severe epilepsy: an array-based genotype-phenotype correlation and a comprehensive review of previously published cases. *Epilepsy Res*. 2008; 81(1):69-79. doi:10.1016/j.epilepsyres.2008.04.018
9. Zhao P, Mao B, Cai X, et al. 2q24 deletion in a 9-month old girl with anal atresia, hearing impairment, and hypotonia. *Int J Pediatr Otorhinolaryngol*. 2018; 109:96-100. doi:10.1016/j.ijporl.2018.03.031
10. Steel D, Symonds JD, Zuberi SM, Brunklaus A. Dravet syndrome and its mimics: Beyond SCN1A. *Epilepsia*. 2017; 58(11):1807-1816. doi:10.1111/epi.13889