

Case report: Sporotrichoid lymphocutaneous pattern in a fish-merchant under immunosuppressant medications: Clues to differential diagnoses

Khadka DK¹, Acharya R², Agrawal S³

^{1,2,3} Department of Dermatology and Venereology, B.P Koirala Institute of Health Sciences, Dharan, Nepal

Correspondence

Ripala Acharya, Department of Dermatology and Venereology, B.P Koirala Institute of Health Sciences, Dharan, Nepal.

Email: ripalaacharya@gmail.com

Funding information: None

Abstract: *Sporotrichoid-lymphocutaneous-pattern is classically seen in sporotrichosis, though also present in other infections like atypical mycobacteriosis and leishmaniasis. Cutaneous atypical mycobacterial infection presents as localized lesions in immunocompetent and is widespread in immunosuppressed patients. Here, we present a case of sporotrichoid-lymphocutaneous infection due to atypical mycobacteria, in a fish-seller under immunosuppressants.*

Keywords: *Sporotrichoid, lymphocutaneous pattern, atypical mycobacterium, mycobacterium marinum*

Introduction

Most cases of nodular lymphangitis or sporotrichoid lesions are the result of infectious and noninfectious diseases. Sporotrichoid lymphocutaneous infections are characterized by suppurative inflammatory nodules along the lymphatic vessels. This is the classic feature of sporotrichosis though other infections such as nocardiosis, atypical mycobacteriosis, and leishmaniasis, can also present with this clinical pattern¹. Mycobacterium marinum is an atypical mycobacterium found in both freshwater and saltwater. Mycobacterium marinum infection is commonly referred to as “fish tank granuloma,” which commonly affects aquarium workers, swimmers, anglers, or marine enthusiasts. Infections typically present with subcutaneous nodules and lymphangitis². Although diagnosis is confirmed by isolation and identification of the organism in practice diagnosis remains largely presumptive based on clinic-histological features and the response to treatment³. Here, we present a case of sporotrichoid lymphocutaneous infection in a female fish handler on immunosuppressive medications.

Case report

A 45-year-old female shopkeeper from the hilly district of Eastern Nepal was presented to our Dermatology outpatient department with erythematous painful nodules over the left hand, forearm,

and arm along the radial border for 10 days and swelling of the left hand for 5 days. She had a history of pain over the left arm and forearm in the past 10 months for which she was treated with oral corticosteroids, methotrexate, and hydroxychloroquine from nearby health facilities and hospitals. She denied any history of trauma prior to the appearance of lesions.

On examination, there were 6 tender erythematous nodules with the local rise in temperature present along the radial border of the left hand, forearm, and arm with oedema of the left hand extending from proximal third of fingers to wrist joint (fig 2).

Investigations showed normal Complete blood count, blood sugar, chest X-ray, urine routine microscopy and serum cortisol levels with positive CRP although the RA factor and Serology (HIV, Hep B, Hep C) were negative. Liver transaminases (AST and ALT) were only mildly increased (1.6 times) and Vitamin D level low (21.6). The wound swab culture was sterile, and the microfilaria test was negative. An incisional skin biopsy was done and sent for histopathological examination and tissue culture for both bacteria and fungus.

The diagnosis of Sporotrichoid lymphocutaneous pattern secondary to infection (probably streptococcal infection or sporotrichosis or atypical mycobacteria) was made. She was started on oral antibiotics (cefixime and doxycycline), analgesics, chymosin, and other supporting medications.

On her follow-up visit, there was persistent discharge from the nodules with mild tenderness. New lesions were appearing in a similar linear fashion along the ulnar border of the left hand and forearm. Later, her skin biopsy reports showed lymphohistiocytic collection admixed with neutrophils and activated macrophages forming epithelioid aggregate and ill-defined granuloma with Acid Fast Bacilli (AFB) stain positive for bacteria. However, the Slit skin smear for *M. leprae* and sputum for AFB were negative. Culture revealed no growth. Further inquiry into the patient's occupation revealed her occupation as a fish handler in her shop. On this background a revised provisional diagnosis of Sporotrichoid lymphocutaneous pattern secondary to atypical mycobacterial infection probably *Mycobacterium marinum* was made and the patient was started on per oral tab Ethambutol 800mg once daily and tab clarithromycin 500 mg twice daily along with cap Doxycycline 100mg twice daily. After 2 months of treatment, the patient responded with complete resolution of cutaneous lesions with scarring and no new lesions appearance since the start of treatment (fig.3). The treatment was continued for further 6 months. There was no recurrence with complete resolution of lesions at the end of 8 months which continued in the 1 month follow up after stoppage of treatment. The patient is still kept in regular follow up.

Discussion

A sporotrichoid pattern, or nodular lymphangitis, describes a distinctive clinical presentation in which inflammatory nodules spread linearly along the path of lymphatic drainage. It can be caused by infectious and non-infectious etiologies. Acute infection is generally caused by streptococcal or staphylococcal bacteria. Chronic infection is generally due to fungal (esp. Sporotrichosis), atypical mycobacteria, or Leishmaniasis. It is the classic manifestation of sporotrichosis caused by *Sporothrix schenckii*, but it can also

result from cutaneous inoculation with *Mycobacterium*, *Leishmania*, or *Nocardia* species, as well as several other inflammatory and neoplastic conditions.

Nearly 80% of the *Sporothrix schenckii* affected patients present the lymphocutaneous form². Similarly, Nontuberculous mycobacteria are an important cause of sporotrichoid lymphocutaneous infections with the most prominently associated species being *Mycobacterium marinum*¹. In a case series, about 25% of cases with *Mycobacterium marinum* infection showed sporotrichoid pattern³. Up to 25% of patients with skin or soft tissue infections related to *N. brasiliensis* will develop sporotrichoid lesions¹. In the Old World, sporotrichoid leishmaniasis has mainly been associated with *L. major* ZCL with incidence ranges from 1.7% to 22 %⁴. Few cases of neoplasm in the sporotrichoid fashion have been reported like keratoacanthoma, epithelioid sarcoma, Langerhans cell histiocytosis, lymphoma, melanoma , peripheral nerve sheath tumor, and squamous cell carcinoma⁵.

Characteristics of main differential diagnoses for nodular lymphangitis is given in table no.1

Table 1: Characteristics and clues to main differential diagnosis diagnoses of Nodular lymphangitis

Agent	Risk factor	Incubation period	Primary lesion	Lymphadenitis	Systemic symptoms	Pathology/culture
<i>Sporothrix schenckii</i>	Gardening (roses), corn crop, soil contact, sphagnum moss, animal scratches (cats) or bites	1 week–3 months	Painless ulcerated nodule.	Occasional	No	Granulomatous infiltrate with asteroid bodies and elongated yeast/Culture (Sabouraud agar at 32 °C
<i>Mycobacterium marinum</i>	Aquariums, fish-handling (fresh and saltwater fish), swimming in oceans, lakes, pools.	1–6 weeks	mildly tender, often ulcerated nodule, with scant seropurulent exudate.	Occasional	No	Suppurative granulomas/Culture on Lowenstein Jensen or Middlebrook agar at 30–32 °C.
<i>Nocardia brasiliensis</i> / <i>N. asteroides</i>	Soil exposure, botanicals, cat scratch.	3 days–6 weeks	Tender nodules commonly ulcerated with mild to abundant purulent drainage	Common	Mild	Granulomas and sulphur granules, giant cells, abscess formation/Culture in most media.
<i>Leishmania brasiliensis</i>	Residence in or travel to endemic areas.	2–24 weeks	Painless, well-demarcated shallow ulcer with indurated borders.	Occasional	No	Amastigotes within histiocytes/Culture on tissue biopsy or impression smears usually in Nicolle-Novy-MacNeal medium or animals
<i>Francisella tularensis</i>	Hunting and other rural outdoor activities, transmitted through ticks, deer flies, wild mammals (rabbits, squirrels, voles), cats.	1–6 days	Painful ulcerated papule with suppuration.	always	Moderate-severe	Granulomatous reaction, multinucleated giant cells, epithelioid cells, neutrophils with focal necrosis/Serology, culture isolation with safety hood.
<i>Staphylococcus aureus</i>		4–10 days	Nodular lesions, frequently abscessed, with drainage of purulent fluid.	-	-	Botryomycotic grains/Culture on most media.

The diagnostic approach for infective nodular lymphangitis is shown in figure 1.

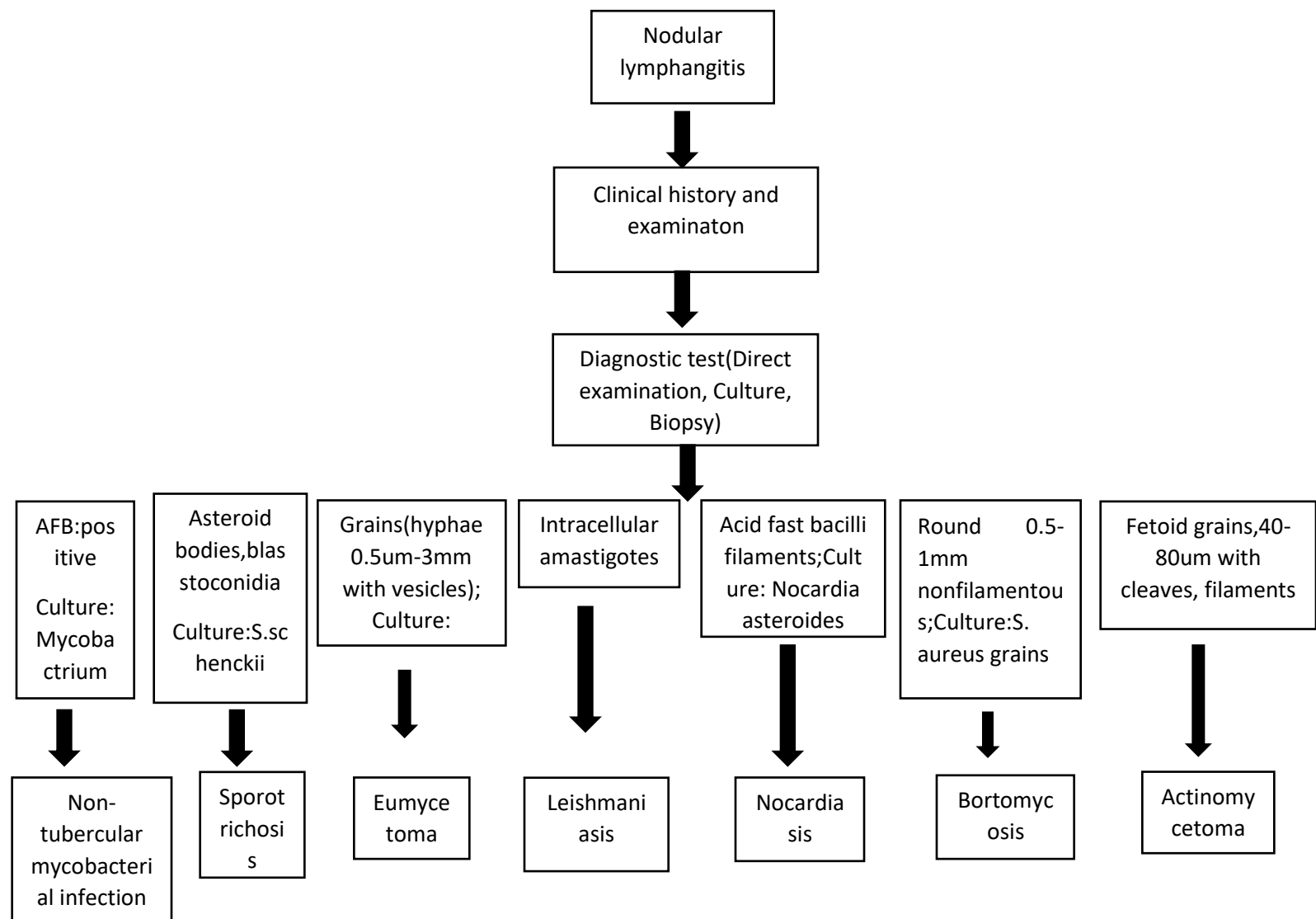


Fig 1: Diagnostic approach in nodular lymphangitis

In our present case, on the basis of clinicopathological correlation, we made a diagnosis of *Mycobacterium marinum* infection which is a non-tuberculous mycobacterium found in non-chlorinated water, with worldwide prevalence. It is the most common atypical *Mycobacterium* that causes opportunistic infection in humans³. *Mycobacterium marinum* is a non-motile acid-fast bacillus, that grows at 30-32°C (86-89.6°F). It grows best on Lowenstein-Jensen media. The clinical presentation varies depending upon the immune status of the individuals. The immunocompetent patients typically present with localized lesions as a solitary, red-to-violaceous plaque or nodule with an overlying crust or verrucous surface infection, whereas

immunosuppressed patients may present with widespread cutaneous lesions as inflammatory nodules, pustules, ulcers or abscesses, in a sporotrichosis type of distribution or widespread lesions or with signs of systemic infection³. Mycobacteria are notorious for not growing in culture even under the most ideal conditions. Recently polymerase chain reaction (PCR) testing on swabs of ulcers or tissue biopsies is considered as the diagnostic test for atypical mycobacteria, this facility is not available freely. Therefore, if the history and physical examination suggest *M. marinum* infection, empiric treatment should be strongly considered even in the absence of biopsy or culture confirmation⁶.

The mainstay of treatment in *M. marinum* infection is antimicrobial therapy. The effective antimicrobials include tetracyclines, fluoroquinolones, macrolides (eg, clarithromycin), rifampicin and sulfonamides (cotrimoxazole). However, because of rarity of disease, very few studies are available regarding efficacious treatment of *Mycobacterium marinum* infection. The duration of therapy is also not well defined, but treatment of skin and soft-tissue infections should be continued for 1-2 months after resolution of symptoms and lesions. Therefore, the treatment duration is typically 3-4 months, longer if deeper structures are involved. Some authors have suggested a minimum duration of 6 months. In some cases, a treatment duration of up to 2 years has been reported. Combination treatment with 2 active agents is preferred, although success has been obtained with single-agent approach. Spontaneous resolution of *M. marinum* infection has been reported.

Aubry et al, 2002 noted that in the past, *M. marinum* has been treated with tetracyclines, sulfamethoxazole and trimethoprim, rifampin plus ethambutol, clarithromycin, levofloxacin, and amikacin. Eighty-seven percent of the patients in their study were cured after therapy that included clarithromycin, rifampin, or tetracyclines. There were also treatment failures with the same antibiotics². **Krooks, J. et al, 2018** reported that the patient initially responded completely to minocycline oral 100mg twice daily for 12 weeks but after 1 month of discontinuation of minocycline, there was recurrence of lesion. Treatment with clarithromycin (500mg twice a day) and ethambutol (15mg/kg once a day) was started leading to the resolution of the lesions in 2 weeks. The treatment was then continued for two more months⁷. This demonstrates that longer duration of treatment is required to avoid recurrences in cases of *M. marinum* infections.

Similarly, Fleming, P. 2017 reported a 52-year-old immunocompetent male with *Mycobacterium marinum* infection in sporotrichoid pattern treated with doxycycline 100 mg orally twice daily for three months. The initial response was excellent but longer follow up was not done.⁸

Our case is unique in that the patient might have exposure to the pathogen as she used to handle raw freshwater fish in her shop. The pathogen found in freshwater i.e. *Mycobacterium marinum* might have inoculated into her skin via minor trauma in her skin unnoticed by the patient while handling the fish.

Though there is no strong evidence and guidelines regarding treatment of *Mycobacterium marinum* infection. In available case reports, combination therapy had shown better response than the monotherapy. Also, in the immunosuppressed patients there is chance of disseminated lesions

with severe presentation requiring more than two drugs combination and, in such cases, treatment with only two drugs have shown relapse of disease on longer follow up requiring addition of the third drug (**Pak-Leung Hoet al, 2001 and Petrini B,2006**)^{9,10}. Hence, in our case, the patient was immunosuppressed, hence we started on three drugs combination to prevent relapse and dissemination of disease. Also, though the patient responded completely in 2 months of treatment against *Mycobacterium marinum*, we continued the treatment for up to 8 months to avoid recurrence.

Table 2: Different case reports of sporotrichoid *Mycobacterium marinum* infection

Author	N o. of ca se	Patient status	Clinical presentation	Diagnosis	Treatment	Duration of treatment	Treatment Response	Follow-up period
Ljungberg et al, 1987 ¹¹	2	Immunocompetent	Sporotrichoid spread in upper extremity	Culture ; biopsy	Case 1: rifampicin+ethambutol+surgery Case 2: cotrimoxazole	Case1: 8 months Case 2; 4 weeks	Case 1: completely healed in last month of therapy Case 2: resolution in weeks of treatment	Case 1:10 months Case 2; 12 months
Preya kullavanija ya, et al. 1993 ¹²	1	-	Sporotrichoid pattern in Lt Upper extremity	Culture +ve, biopsy: suggestive, afb -ve)	Antitubercular drugs(HRZES)	4-5 months	Complete resolution with scars after 2-3 months of therapy	-
A. Feddersen, 1996 ¹³	1	3 years old	Sporotrichoid nodules in right upper extremity	culture, biopsy	rifampin (1x 300 mg) and clarithromycin (2x125 mg) [4-6]. Protionamid (62.5 mg-125 mg-62.5 rag)	-	Regression after 3 weeks of treatment though incomplete	
Ryan et al, 1997 ¹⁴	5	Immunocompetent	Sporotrichoid nodules	Biopsy: consistent, afb -ve)	Minocycline	2-3 months	Complete resolution	
Rebecca C et al, 1997 ¹⁵	1	27 months old boy	Sporotrichoid nodules in face	Culture confirmed	Oral clarithromycin (30 mg/kg per day) and rifampin (10 mg/kg per day).	5 months	gradual resolution of the lesions with minimal residual scarring	
Saadatmand et al, 1999 ¹⁶	1	Immunocompetent	Sporotrichoid nodules in right upper extremity, bursitis	biopsy, culture	Minocycline	6 months	Responded in 2 months of therapy	

Bhatty MA, 2000 ¹⁷	2	Diabetic,	Sporotrichoid	Culture	→i) Ciprofloxacin 500 mg twice daily and rifampicin 600 mg twice daily →ii) oral doxycycline 100 mg once daily and ciprofloxacin 500mg twice daily	3 months and 2 months respectively	Complete cure	-
Fernando Torres, 2001 ¹⁸	1	Lung transplant patient under immunosuppressants, Fish tank exposure	4 nodules in right hand and forearm	culture +ve, biopsy: AFB-ve)	ethambutol 800 mg/day, azithromycin 500 mg/day, and minocycline 100 mg	12 months	Complete resolution	Till 6 months after therapy completion
Aubry et al, 2002 ²	16	-	Sporotrichoid	culture confirmed	Clarithromycin, ethambutol, cyclines, rifampicin alone or in combination	Avg: 3.5 months	15 → complete cure 1 → treatment failure	-
Lewis, F et al, 2003 ¹⁹	7	1 diabetic	sporotrichoid	culture, tissue AFB, biopsy	1: clarithromycin + rifampicin excisional bx 6: Clarithromycin + ethambutol	2-4 months	Complete resolution	
Mirjam Belić, 2006 ²⁰	1	immunocompetent	Verrucous painless nodules in right upper extremity in sporotrichoid fashion	culture	rifampicin, ethambutol, and clarithromycin	6 months	Complete resolution with residual scars	
Streit M, 2006 ²¹	1	On oral immunosuppressants	EN like lesions in right upper extremity	Culture; tissue AFB +ve)	Ethambutol + clarithromycin 4 months Later doxycycline added due to recurrence	4 months + few months	Dramatic improvement w/ b recurrence of newer lesions	

Schwendiman MN et al (2009) ⁵	1	Immunocompetent, Aquarium cleaner	Subcutaneous nodules with sporotrichoid spread in rt. Hand and forearm	biopsy -acid-fast bacilli +, Culture confirmed)	four months of doxycycline without resolution→ 4 months of clarithromycin 500 mg twice daily and ethambutol 1200 mg daily	4 months + 4 months	Monotherapy→ no response Combination therapy→ complete resolution in 2 months of therapy	-
Fleming p. et al,2017 ⁸	1	Immunocompetent, Fish tank exposure present	erythematous and ulcerative papulonodules, left index finger to his upper arm in a sporotrichoid pattern	presumptive on Biopsy: dermal granulomatous inflammation with multinucleate giant cells, lymphocytes, histiocytes and plasma cells, AFB stain: negative)	doxycycline, 100 mg orally twice daily	3 months	excellent	-
Present case report,2022	1	on immunosuppressants, Fish handler	Sporotrichoid pattern of erythematous tender nodules on left hand and forearm	Mycobacterium marinum(biopsy: suggestive, with AFB positive)	Ethambutol 800mg od + Clarithromycin 500mg bd+ Doxycycline 100mg bd	8 months	Complete resolution with residual scar	9 months

Conclusion

Sporotrichoid lesions are caused by infectious and noninfectious diseases. A detailed clinical history (triggering factor, the epidemiological context, immune status of patient, progression and evolution of lesion) and a careful physical examination with the help of investigations like cultures, histopathology, and will allow the initiation of a specific therapy in the majority of patients. As, in our case, detailed history and relevant investigations led to the diagnosis and proper treatment with satisfactory and effective response in the patient.

ACKNOWLEDGMENTS

There are no acknowledgements for this case report.

CONFLICT OF INTEREST

The authors have no conflicts of interest.

AUTHOR CONTRIBUTIONS

DKK involved in manuscript preparation and literature search, RA involved in manuscript preparation and served as a correspondence author. SA involved in concept, manuscript editing, guidance, and final approval.

CONSENT

A written consent was obtained from the patient for the publication of the case and images.

DATA AVAILABILITY STATEMENT

We agree to make the manuscript available to general people and are also ready to provide other necessary data regarding the manuscript in case required.

ORCID

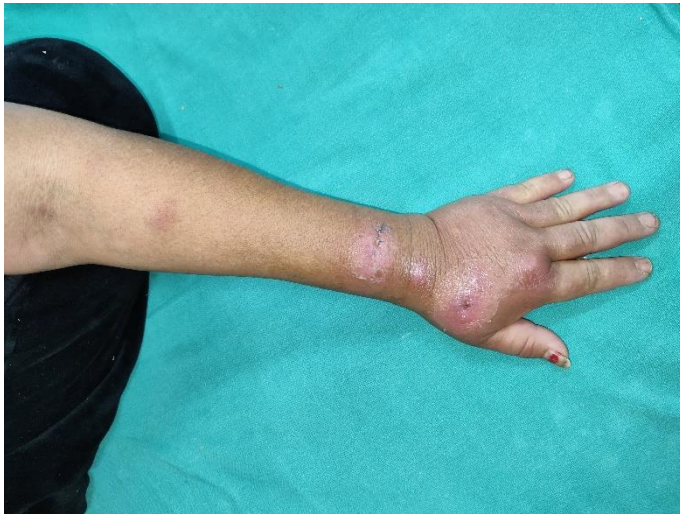<https://orcid.org/0000-0002-4040-5569>

REFERENCES

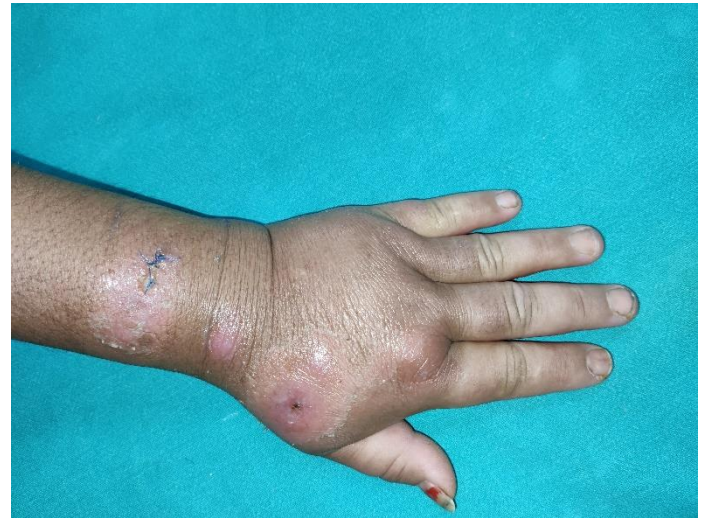1. Tirado-Sánchez A, Bonifaz A. Nodular lymphangitis (Sporotrichoid lymphocutaneous infections). clues to differential diagnosis. *J Fungi*. 2018;4(2).
2. Aubry A, Chosidow O, Caumes E, Robert J, Cambau E. Sixty-three cases of *Mycobacterium marinum* infection: clinical features, treatment, and antibiotic susceptibility of causative isolates. *Archives of internal medicine*. 2002 Aug 12;162(15):1746-52.
3. Rallis E, Koumantaki-Mathioudaki E. Treatment of *Mycobacterium marinum* cutaneous infections. *Expert opinion on pharmacotherapy*. 2007 Dec 1;8(17):2965-78.
4. Ben M, Saghrouni F, Saadi-Ben Y, Ghariani N, Yaacoub A, Ach H, et al. Sporotrichoid Cutaneous Leishmaniasis in Central Tunisia: Epidemiological and Clinical Aspects. *Leishmaniasis - Trends Epidemiol Diagnosis Treat*. 2014;
5. Schwendiman MN, Johnson RP, Henning JS. Subcutaneous nodules with sporotrichoid spread. *Dermatol Online J*. 2009;15(5):9–12.
6. Abudu B, Cohen PR. Sporotrichoid Keratoacanthomas: Case Report and Review of Neoplasms Presenting in a Sporotrichoid Pattern. *Cureus*. 2018;(August).
7. Krooks J, Weatherall A, Markowitz S. Complete resolution of *Mycobacterium marinum* infection with clarithromycin and ethambutol: a case report and a review of the literature. *The Journal of Clinical and Aesthetic Dermatology*. 2018 Dec;11(12):48.
8. Fleming P, Keystone JS. *Mycobacterium marinum* infection with sporotrichoid spread from fish tank exposure. *CMAJ*. 2017 Jan 16;189(2):E76-.
9. Ho PL, Ho P, Fung BK, Ip WY, Wong SS. A case of disseminated *Mycobacterium marinum* infection following systemic steroid therapy. *Scandinavian journal of infectious diseases*. 2001 Jan 1;33(3):232-3
10. Petrini B. *Mycobacterium marinum*: ubiquitous agent of waterborne granulomatous skin infections. *European Journal of Clinical Microbiology and Infectious Diseases*. 2006 Oct;25(10):609-13.

11. Ljungberg B, Christensson B, Grubb R. Failure of doxycycline treatment in aquarium-associated *Mycobacterium marinum* infections. *Scandinavian journal of infectious diseases*. 1987 Jan 1;19(5):539-43.
12. KULLAVANIJAYA P, SIRIMACHAN S, BHUDDHAVUDHIKRAI P. *Mycobacterium marinum* cutaneous infections acquired from occupations and hobbies. *International Journal of Dermatology*. 1993 Jul;32(7):504-7.
13. Feddersen A, Kunkel J, Jonas D, Bhakdi S, Husmann M, Engel V. Infection of the upper extremity by *Mycobacterium marinum* in a 3-year-old boy—Diagnosis by 16S-rDNA analysis. *Infection*. 1996 Jan;24(1):47-8.
14. Ryan JM, Bryant GD. Fish tank granuloma—a frequently misdiagnosed infection of the upper limb. *Emergency Medicine Journal*. 1997 Nov 1;14(6):398-400.
15. Brady RC, Sheth A, Mayer T, Goderwis D, Schleiss MR. Facial sporotrichoid infection with *Mycobacterium marinum*. *The Journal of pediatrics*. 1997 Feb 1;130(2):324-6.
16. Saadatmand B, Poulton JK, Kauffman CL. *Mycobacterium marinum* with associated bursitis. *Journal of cutaneous medicine and surgery*. 1999 Apr;3(4):218-20.
17. Bhatti MA, Turner DP, Chamberlain ST. *Mycobacterium marinum* hand infection: case reports and review of literature. *British journal of plastic surgery*. 2000 Mar 1;53(2):161-5.
18. Torres F, Hodges T, Zamora MR. *Mycobacterium marinum* infection in a lung transplant recipient. *The Journal of heart and lung transplantation*. 2001 Apr 1;20(4):486-9.
19. Lewis FM, Marsh BJ, von Reyn CF. Fish tank exposure and cutaneous infections due to *Mycobacterium marinum*: tuberculin skin testing, treatment, and prevention. *Clinical Infectious Diseases*. 2003 Aug 1;37(3):390-7.
20. Belic M, Miljkovic J, Marko PB. Sporotrichoid presentation of *Mycobacterium marinum* infection of the upper extremity. A case report. *ACTA DERMATOVENEROLOGICA ALPINA PANONICA ET ADRIATICA*. 2006 Sep 1;15(3):135.
21. STREIT M, BOHLEN LM, HUNZIKER T et al. : Disseminated *Mycobacterium marinum* infection with extensive cutaneous eruption and bacteremia in an immunocompromised patient. *Eur. J. Dermatol.* (2006) 16 (1): 79 -83.

Illustrations



(i)



(ii)

Fig 2 (i) and (ii) : Initial presentation with multiple erythematous nodules in sporotrichoid lymphocutaneous pattern in left hand and forearm

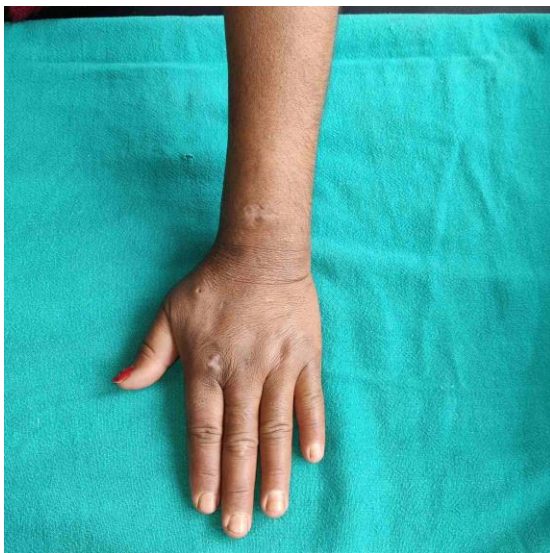

Fig 3: Complete resolution of lesions at 6 months of Clarithromycin, ethambutol and doxycycline