

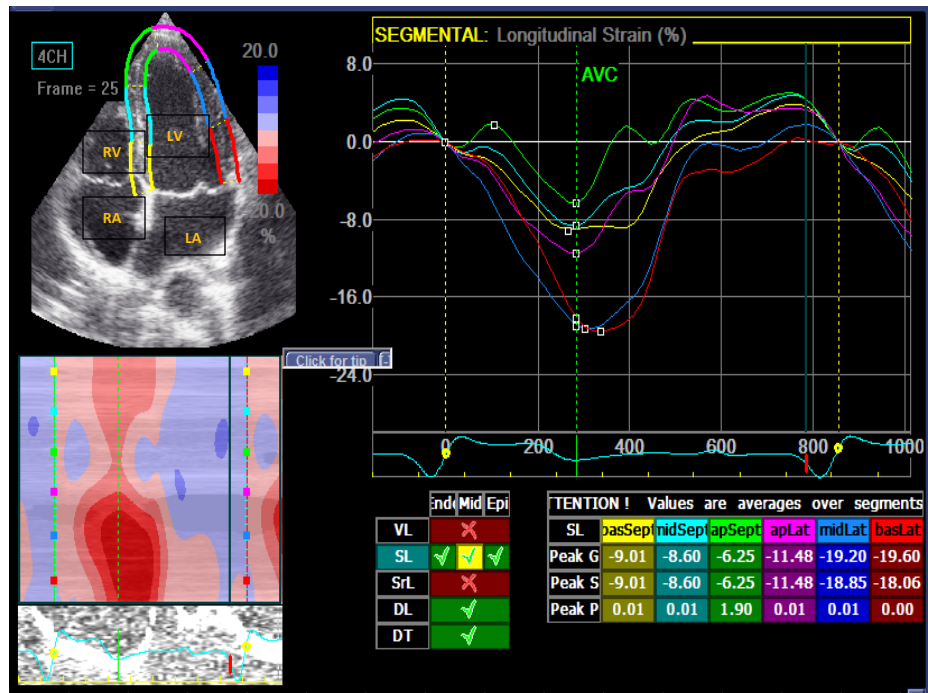Figure 1: 2-D speckle tracking echocardiography in apical 4 chamber view in patient during AS-VP mode (group I)

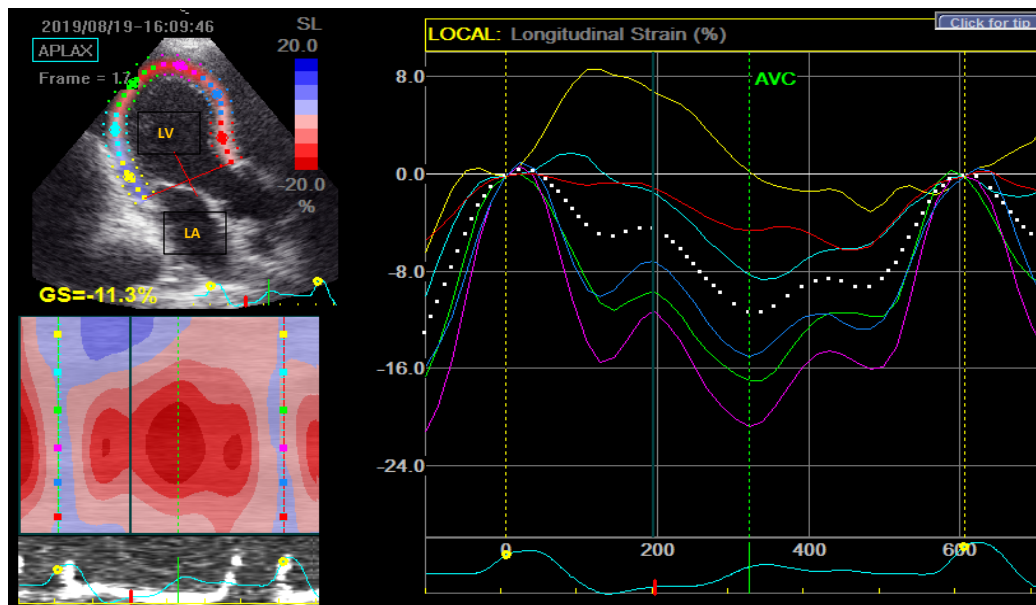


Figure 2: 2-D speckle tracking echocardiography in apical long axis view in patient during AP-VP mode (group II)

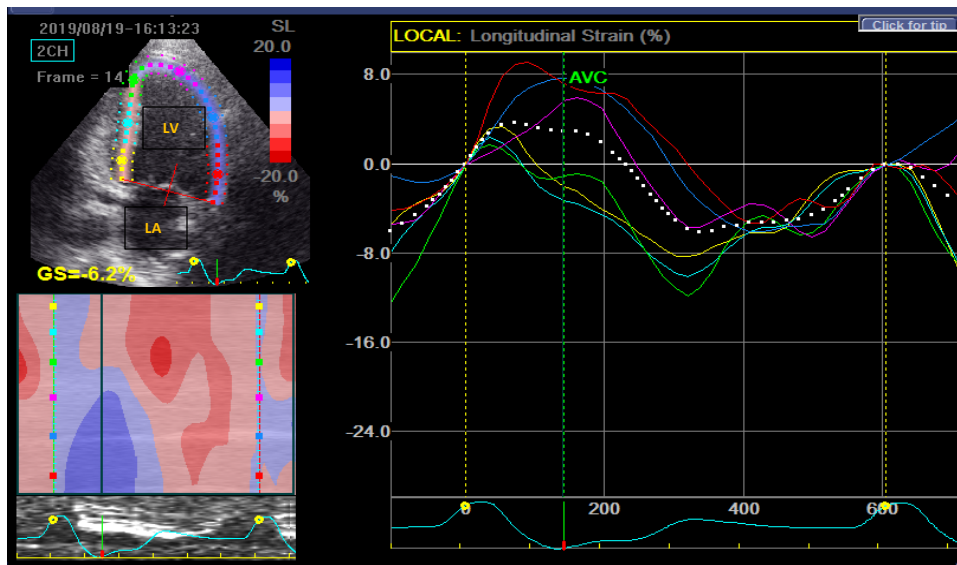
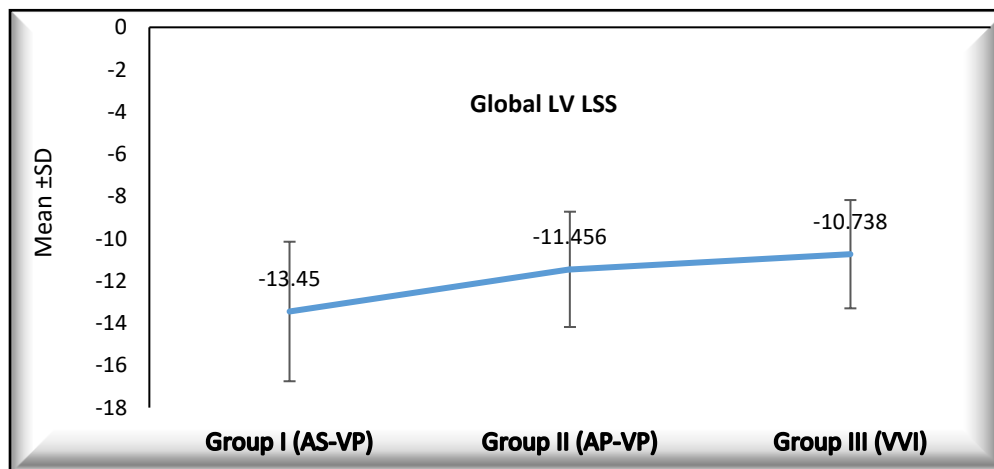


Figure 3: 2-D speckle tracking echocardiography in apical 2 chamber view in patient during VVI mode (group III)



LV LSS: Left ventricular longitudinal systolic strain

Figure 4: Linear comparison between the patients during AS-VP mode (group I), AP-VP mode (group II) and during VVI mode (group III) regarding global LV longitudinal systolic strain

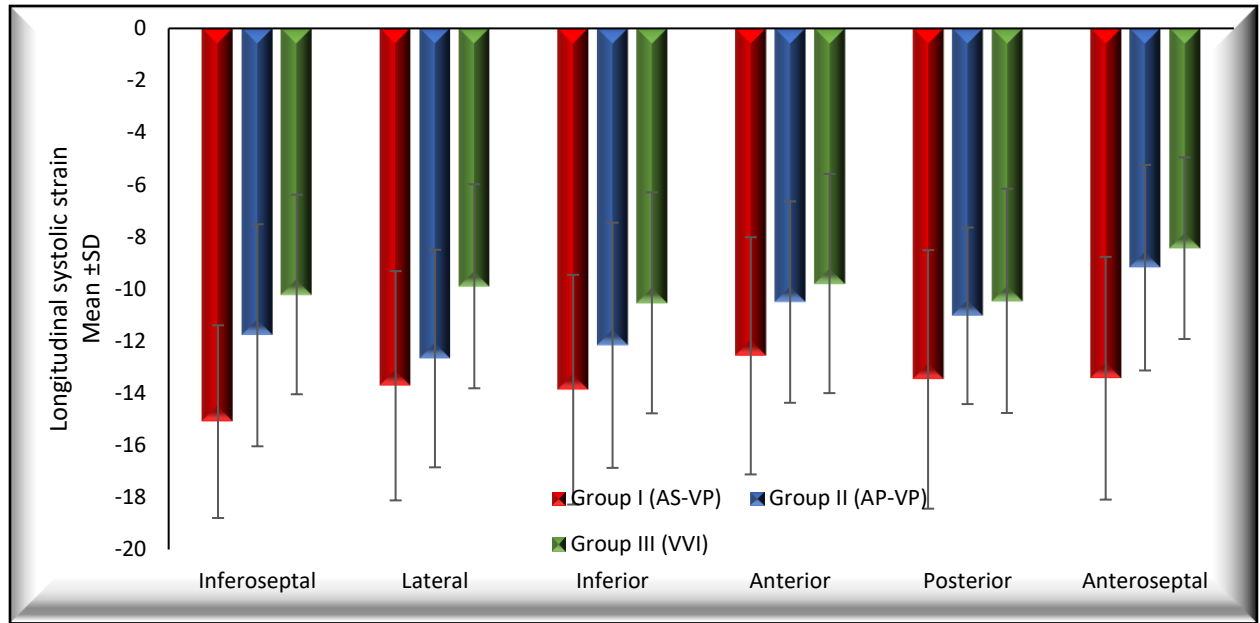


Figure 5: Comparison between the patients during AS-VP mode (group I), AP-VP mode (group II) and VVI mode (group III) regarding regional LV longitudinal systolic strain