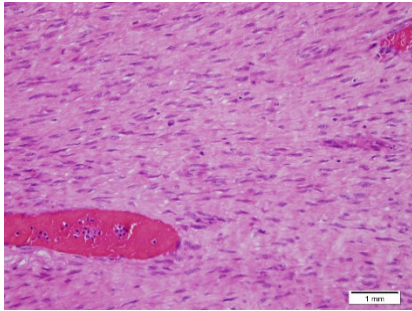


**Figure 3:** histopathology showing. **A).** Interaabdominal Fibromatosis

All surgical resection margins are free of tumor size 26 x 17 x 9 cm.



**B).** Immunohistochemical staining of the tumor showing positive stain for anti-beta-catenin  
x400.

