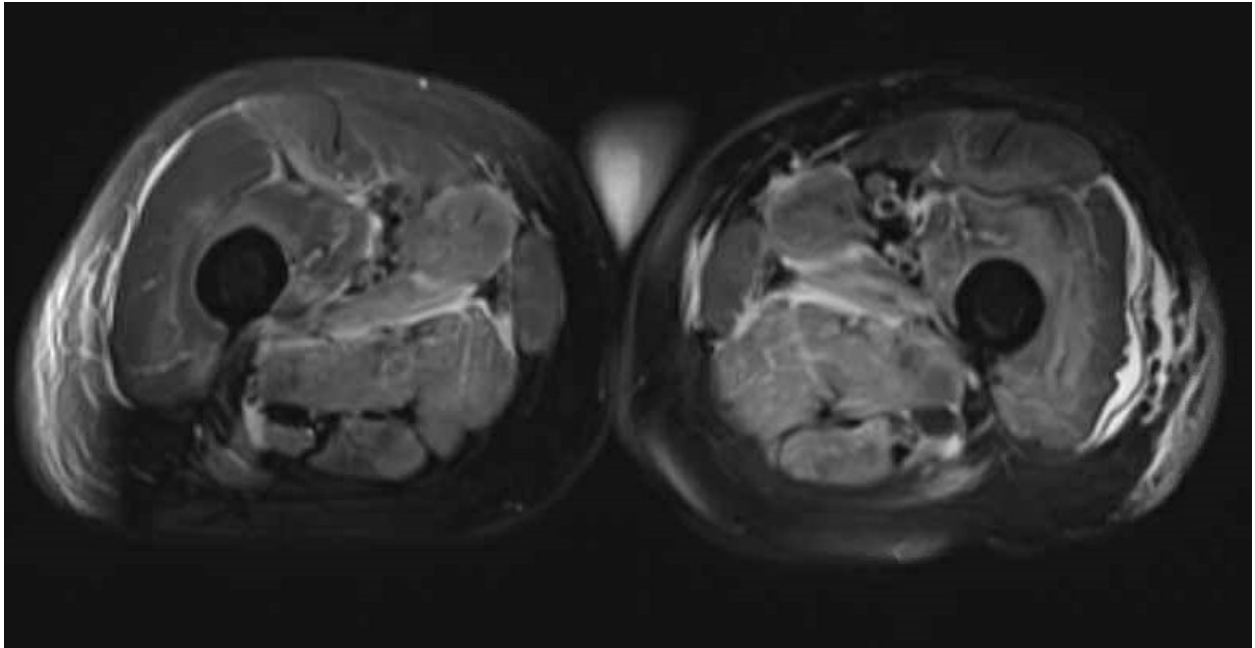


Figure 1: MR bilateral lower extremities (femurs) with and without Intravenous Contrast.



There is enhancing feathery T2 hyperintense signal in the musculature of the proximal thighs bilaterally. Involvement is most pronounced in the adductor, obturator, and tensor fascia lata musculature with patchy involvement of the visualized gluteal, proximal hamstrings, and quadriceps musculature.