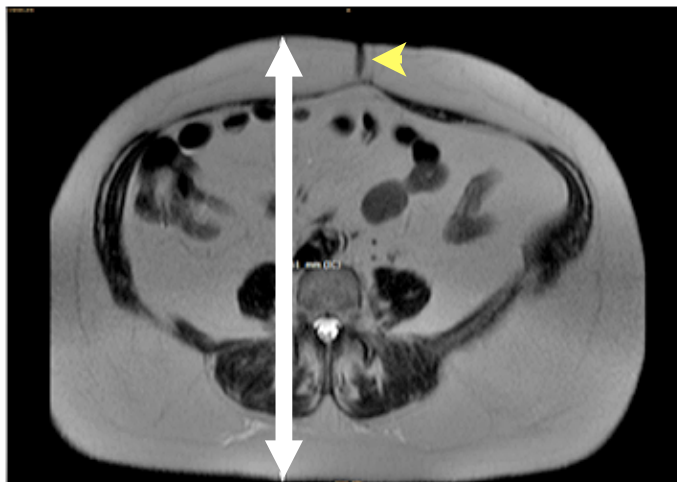
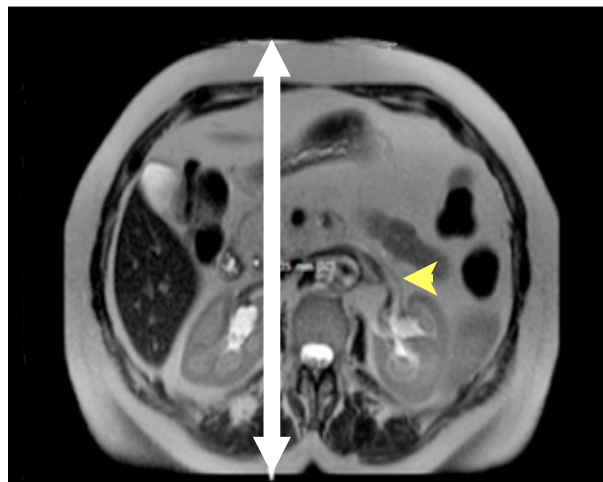


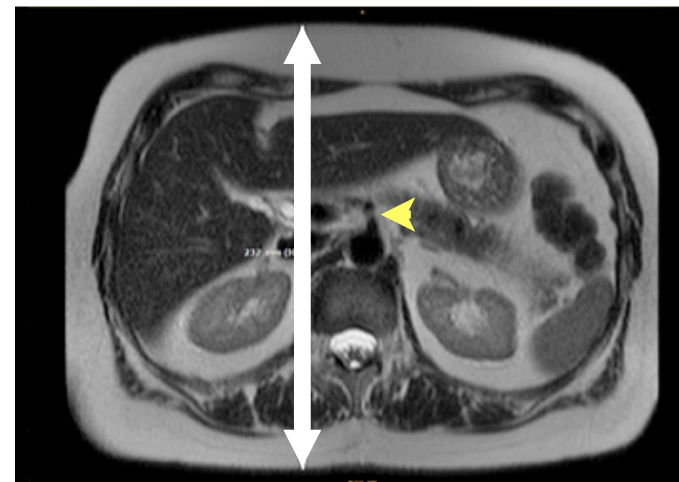
a. Umbilical



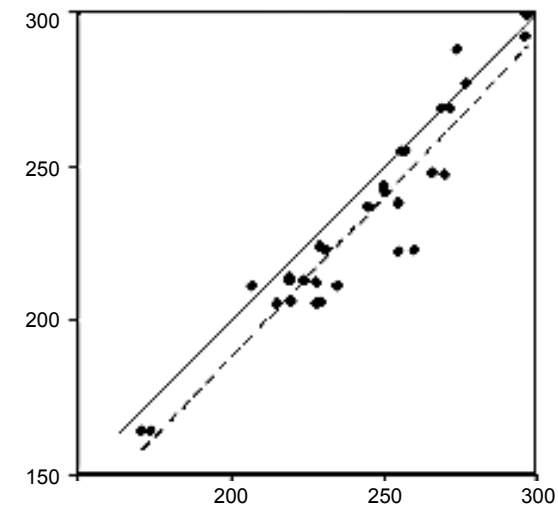
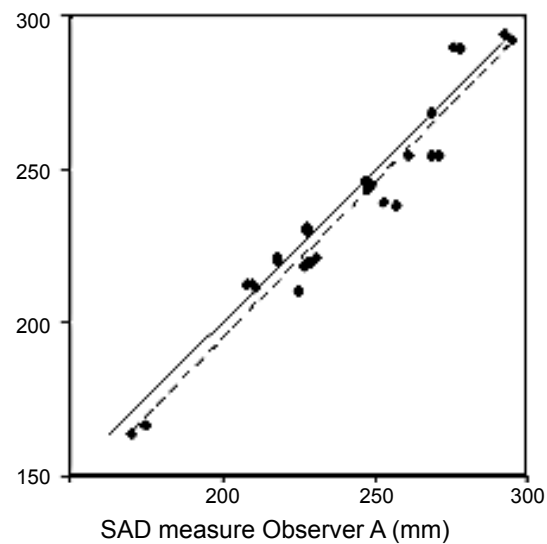
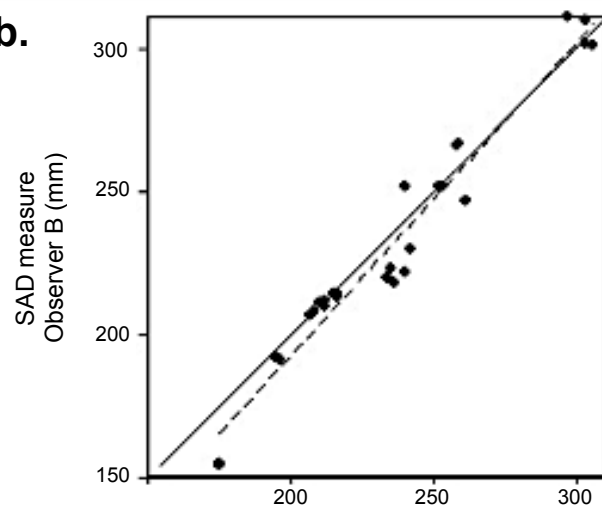
Left renal vein



Inferior mesenteric artery



b.



c.

