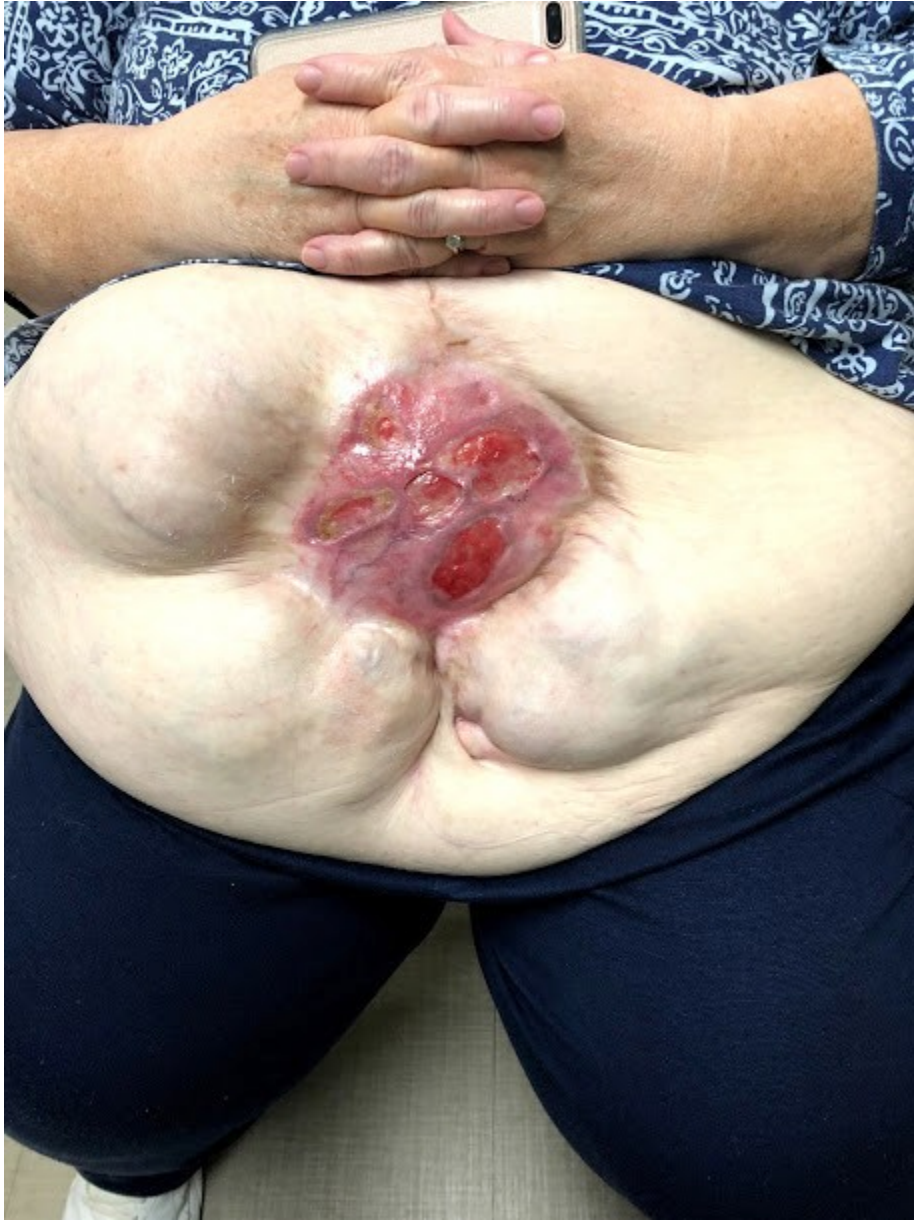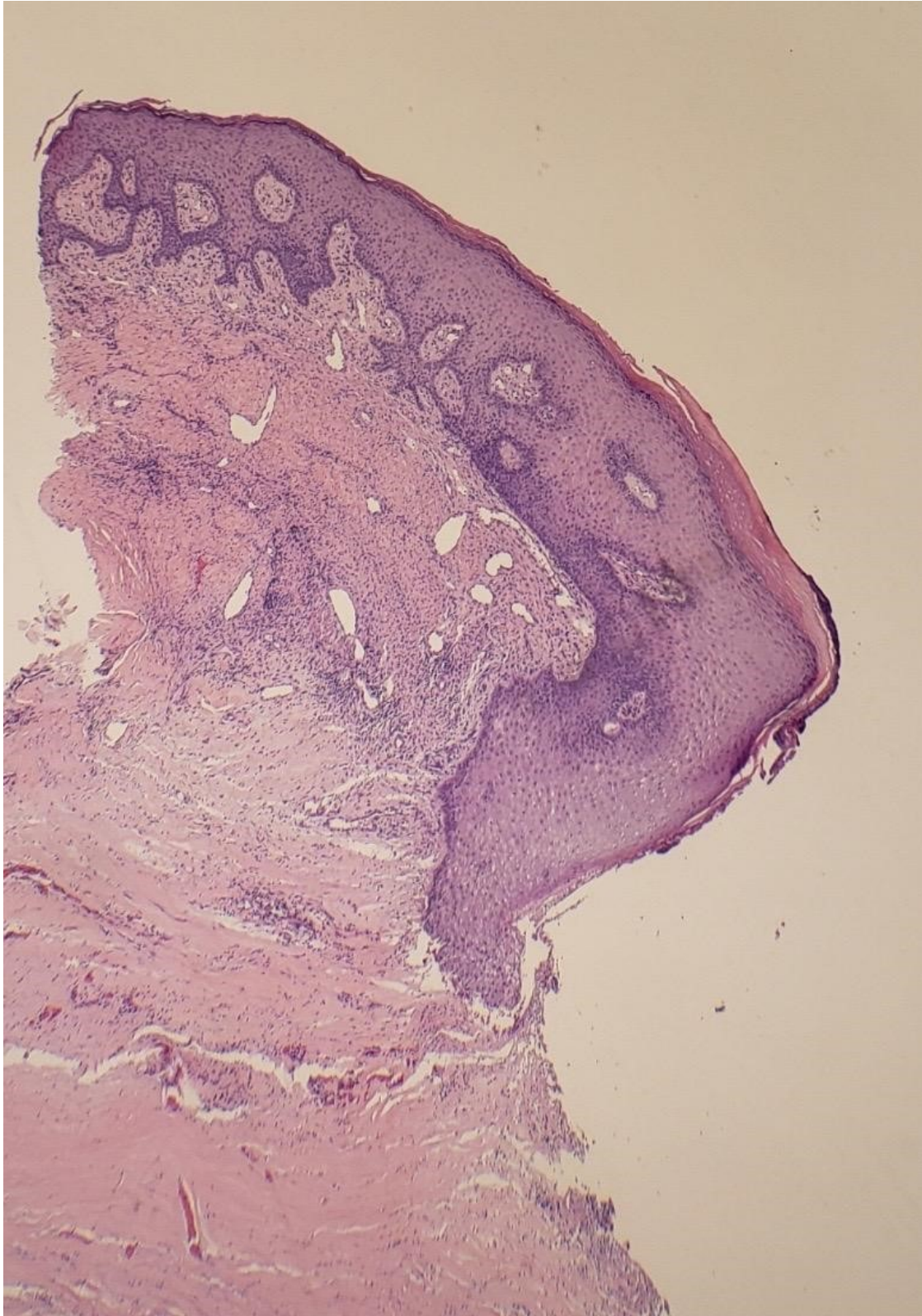



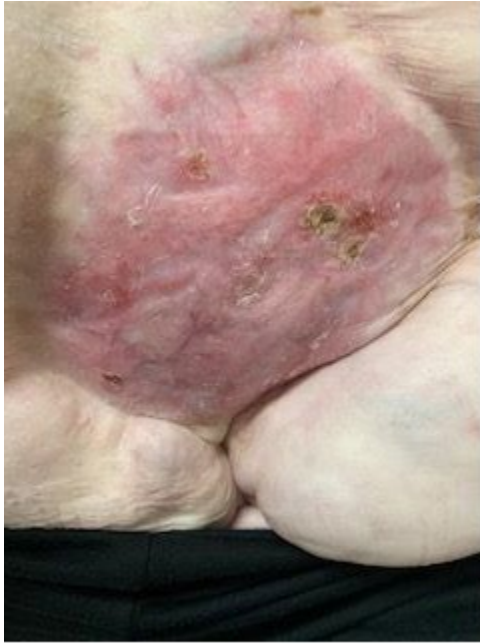
Figure 1. A. 9 cm x 9 cm scar with multiple ulcerated lesions on the anterior supra-umbilical region)



B. Histopathology: ulceration with extensive dermal fibrosis, chronic inflammation, numerous eosinophils and granulation tissue



C. 1 month following losartan discontinuation.