

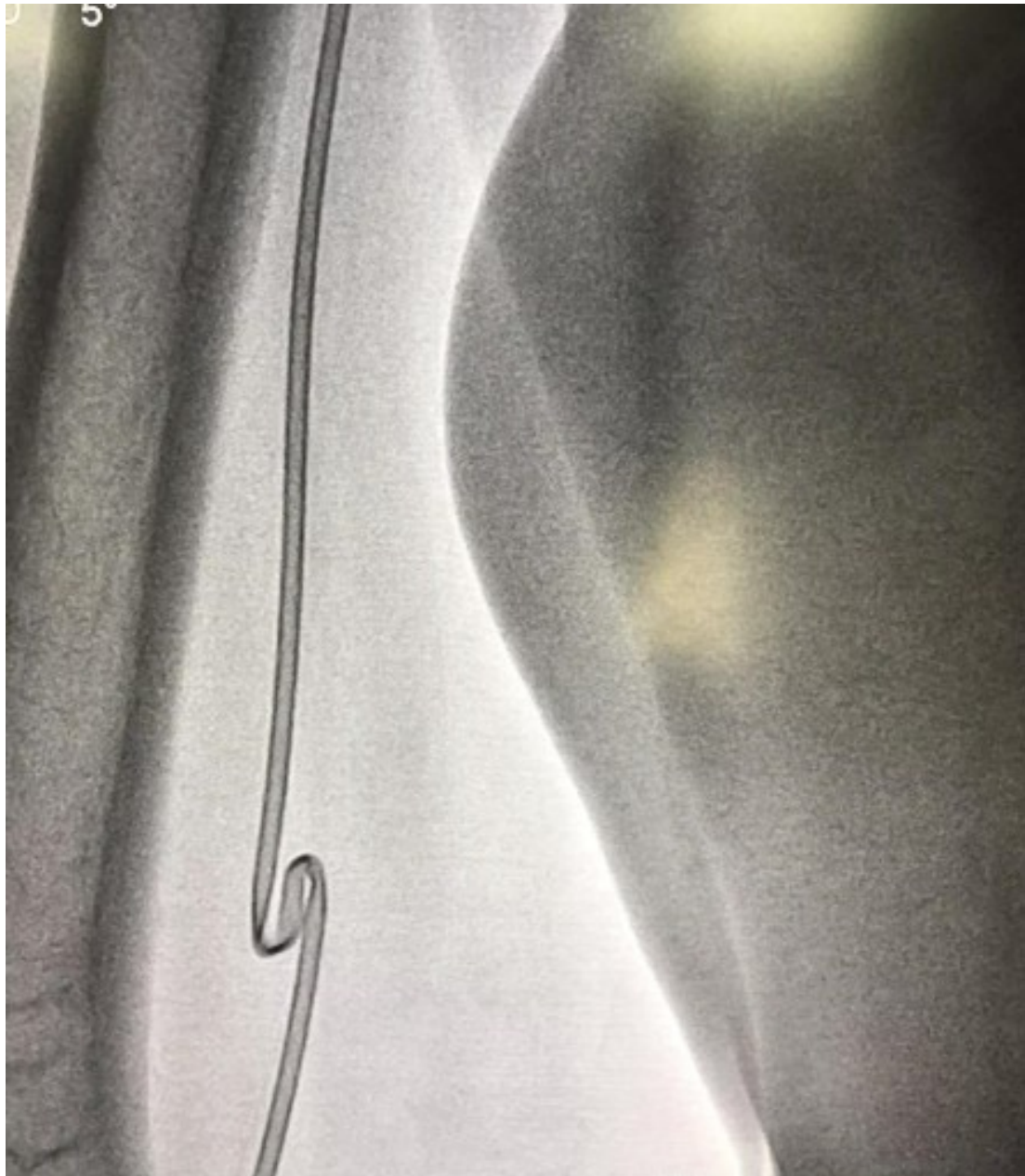

Fig. 1 It revealed an outright knot within right brachial artery with fluoroscopy.

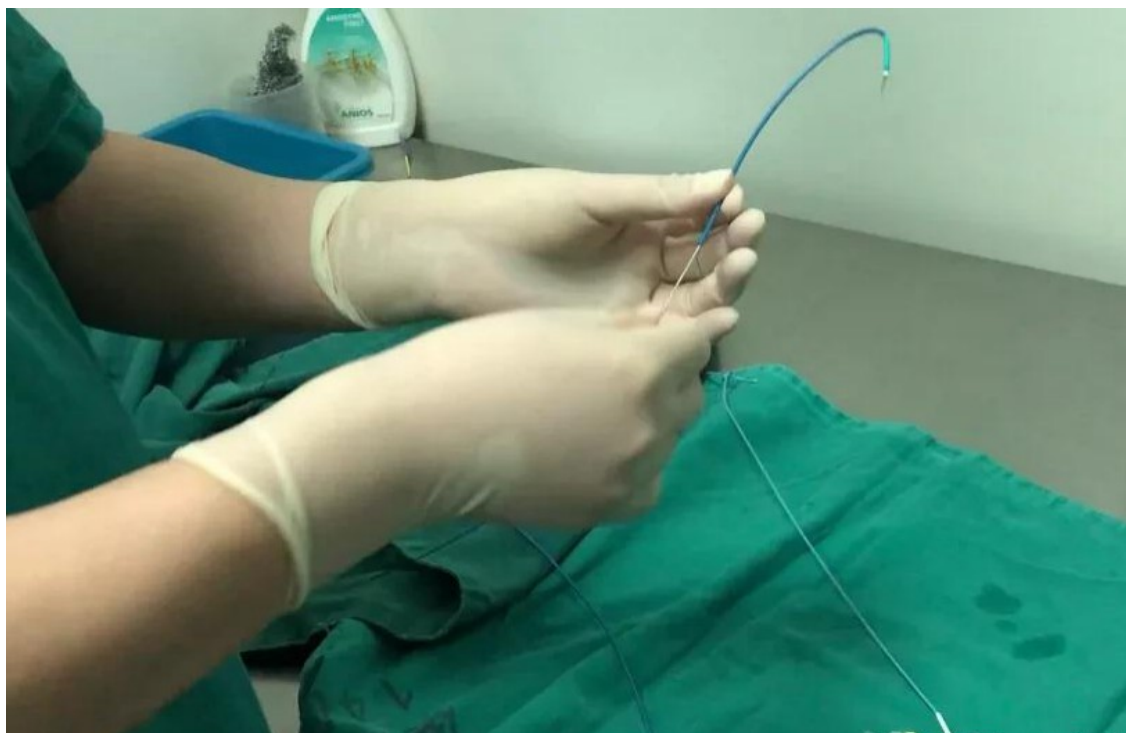

Fig.2 A balloon passed through the cut guiding catheter from tail to tip.

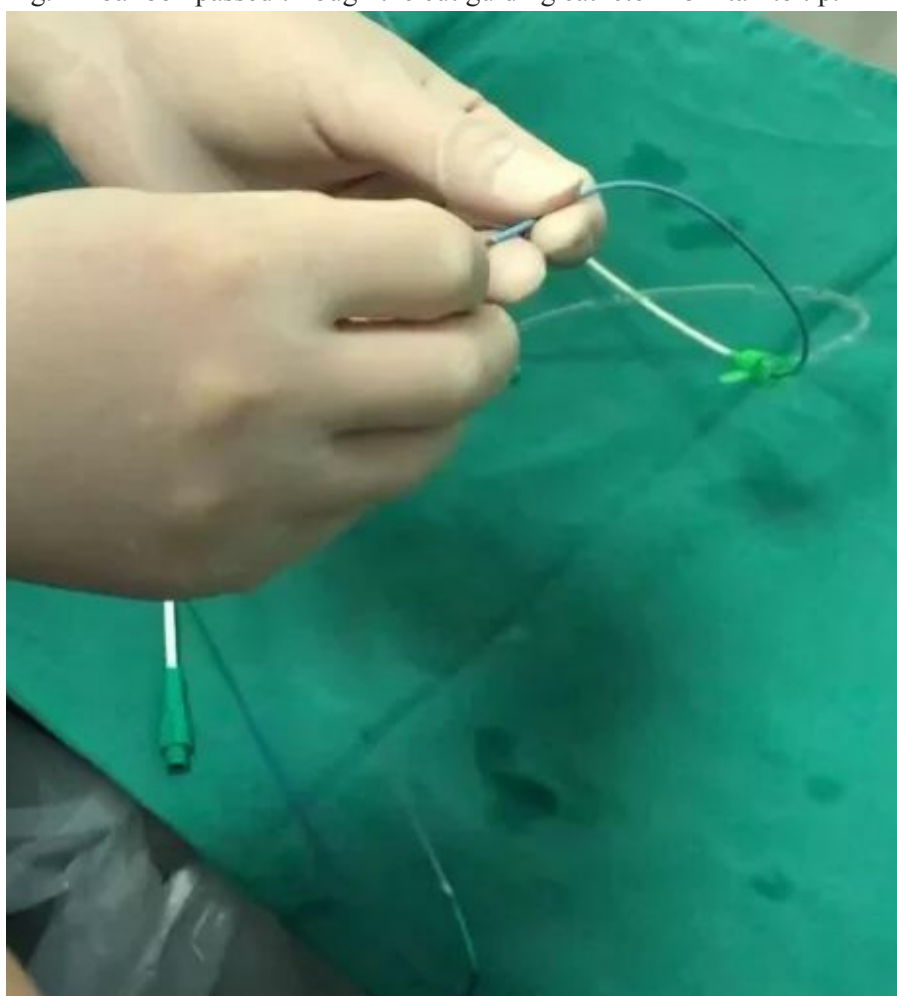


Fig.3 A balloon passed through the cut angiography catheter.

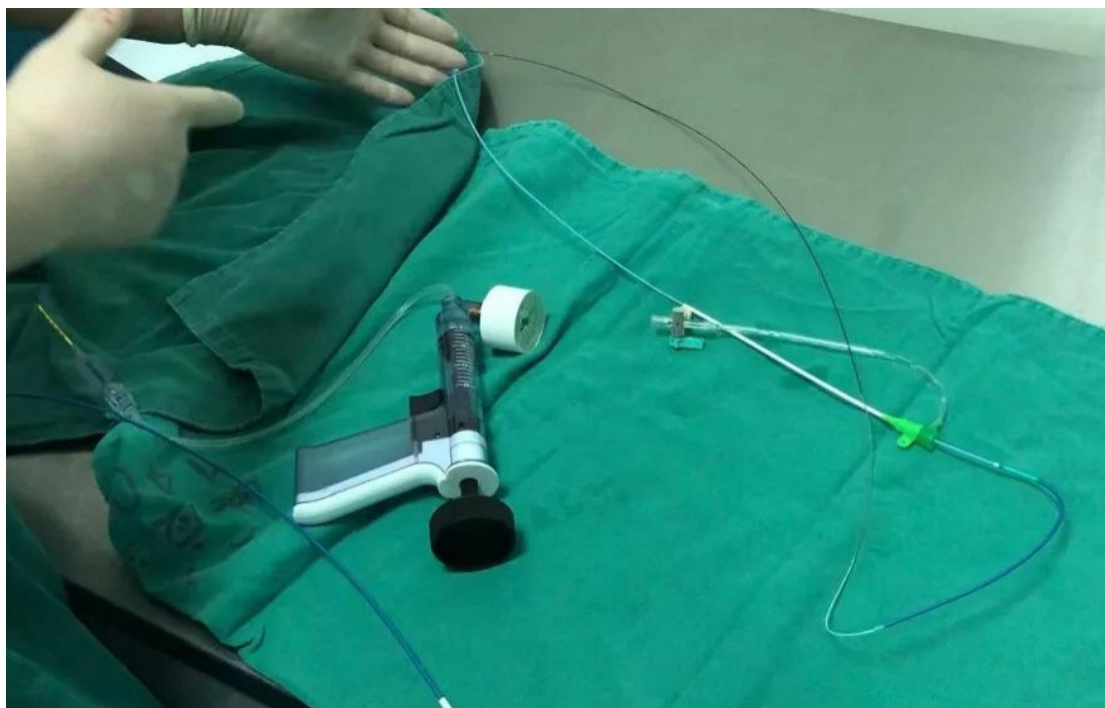

Fig.4 The balloon and the angiography catheter contact tightly.

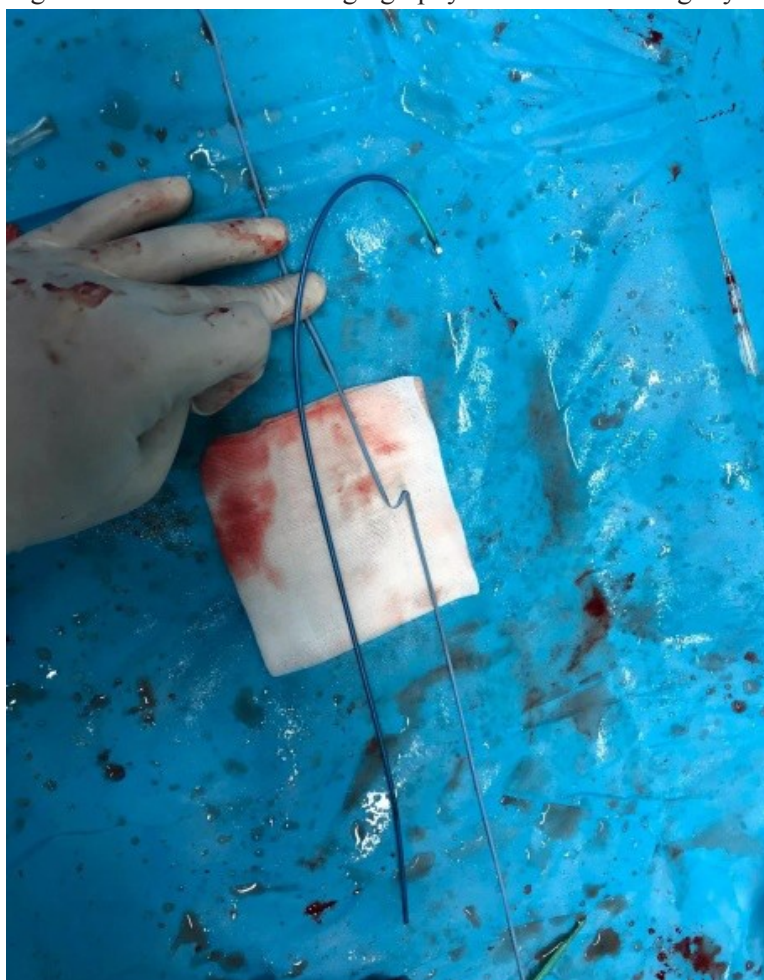

Fig.5 The knotted catheter was pulled out successfully.