

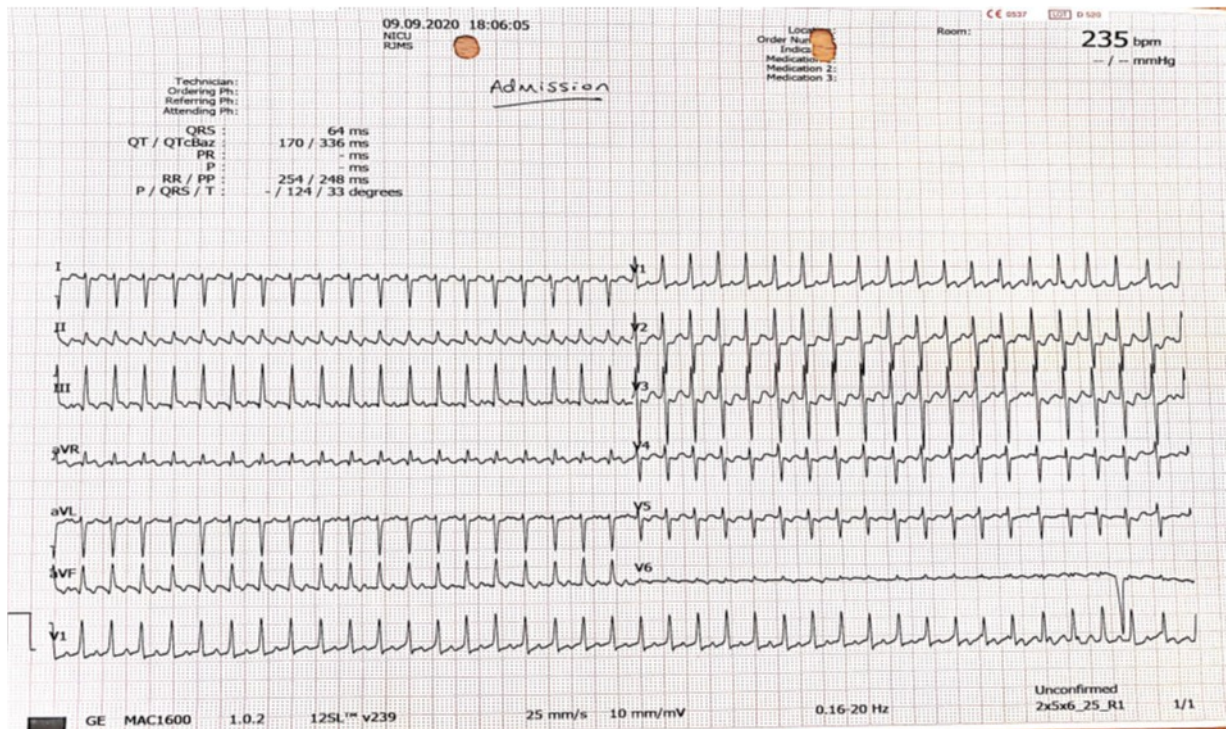Figure 1: Postnatal ECG pre-cardioversion showing the neonate still in Atrial flutter with the ventricular heartbeat rate of 235 bpm

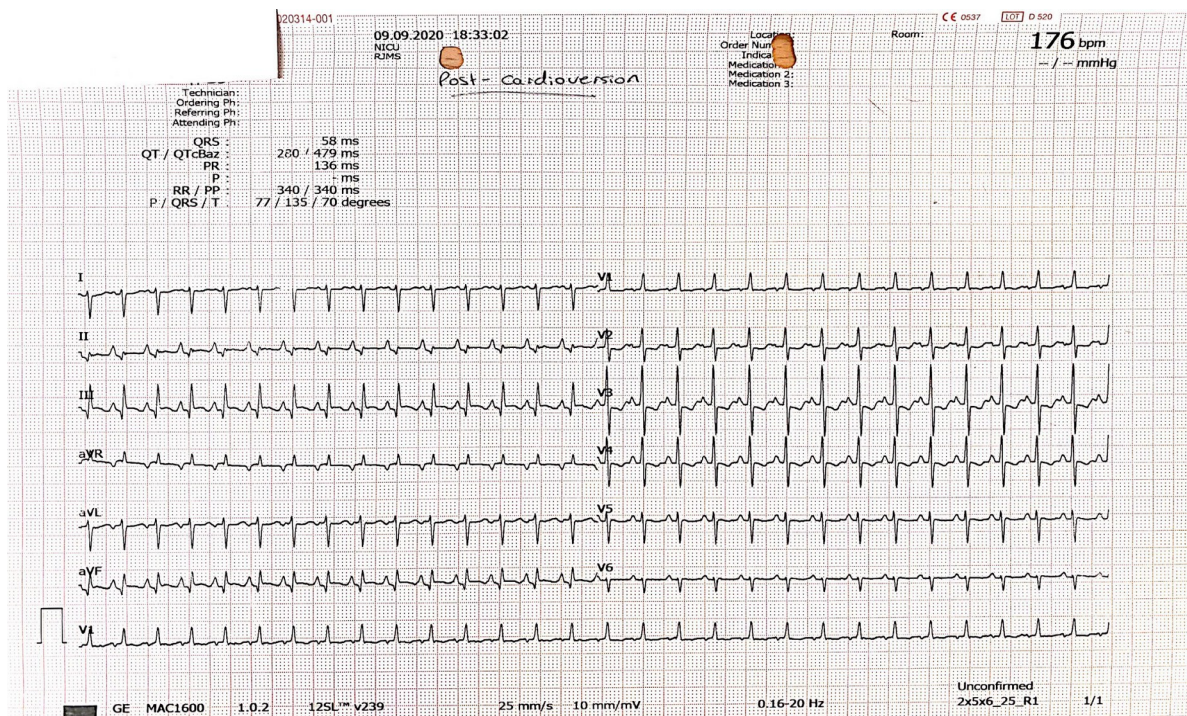


Figure 2: Postnatal ECG post-cardioversion with sinus rhythm achieved with ventricular rate of 176 bpm