

To 'Journal of medical case reports'

;Editor-in-cheif

I would like submit a manuscript entitled '***Development of squamous cell carcinoma in an untreated patient of psoriasis: a case report***' for your kind consideration for publication in your journal. The manuscript is important due to incidence of SCC in a psoriatic patient without any systemic therapy or phototherapy. This would be a rare condition and previous studies have not focused on this issue in detail.

We believe these findings will be of interest to the readers of Journal of medical case reports. And this manuscript is appropriate for publication by your journal.

I hereby certify that this is an original paper which has not been published elsewhere, and is not currently under any consideration for publication anywhere. The authors received no financial support for the research and/or authorship of this article. The authors declare that they have no conflict of interest to the publication of this article.

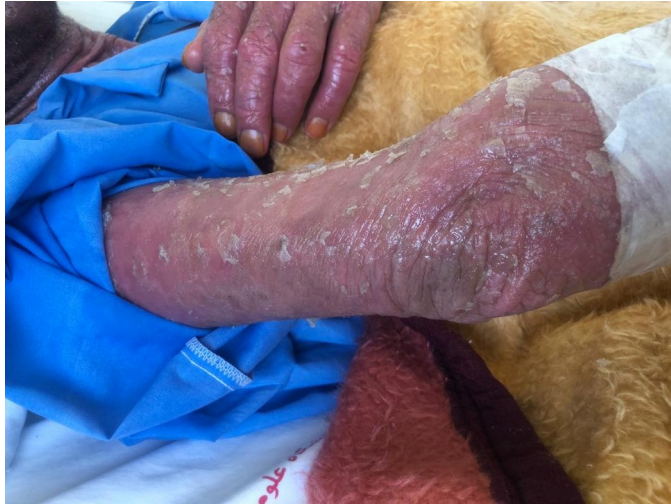.I look forward to hearing from you at your earliest convenience

.Thanks you for your consideration of this manuscript

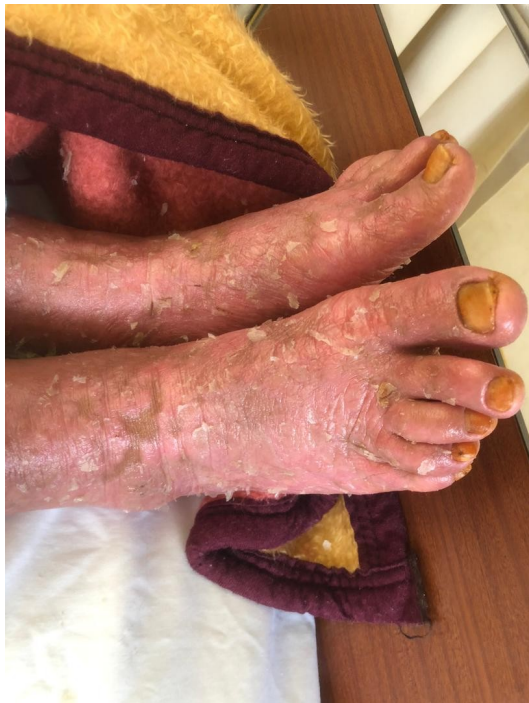,Sincerely

Zahra Talebzadeh, Resident of Dermatology, Department of Dermatology, School of Medicine, Isfahan University of Medical Sciences, Isfahan, Iran

Figures



.Figure 1: Extensor aspect of the right arm showing erythematous scaly skin



.Figure 2: Dorsal aspect of both feet showing erythematous scaly skin

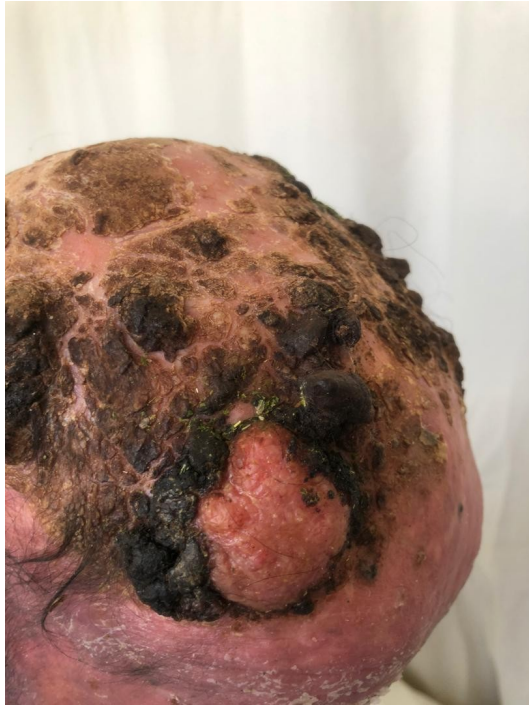

Figure 3: Multiple tumoral lesions present over the scalp including a 6 x 5 cm erythematous, firm and adherent lesion over the frontal part

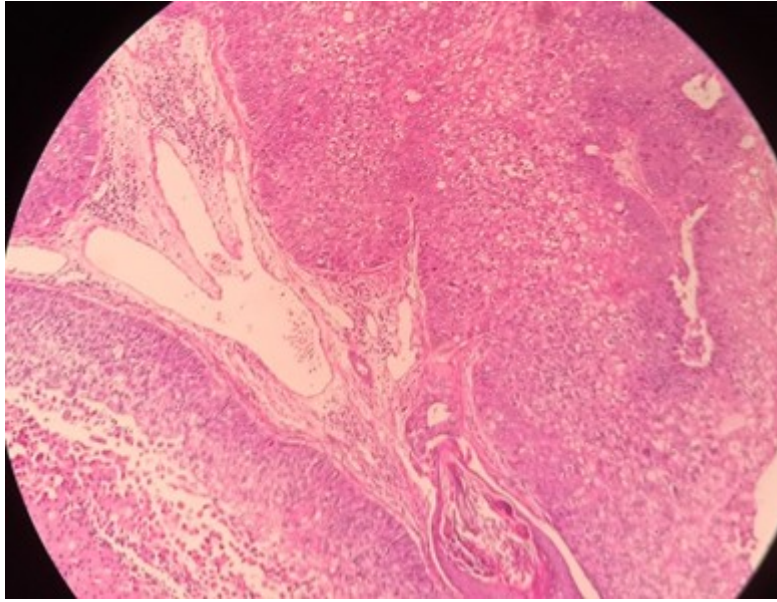


Figure 4: Histopathological schema showing neoplastic proliferation of epithelial cells with infiltration of lymphocytes

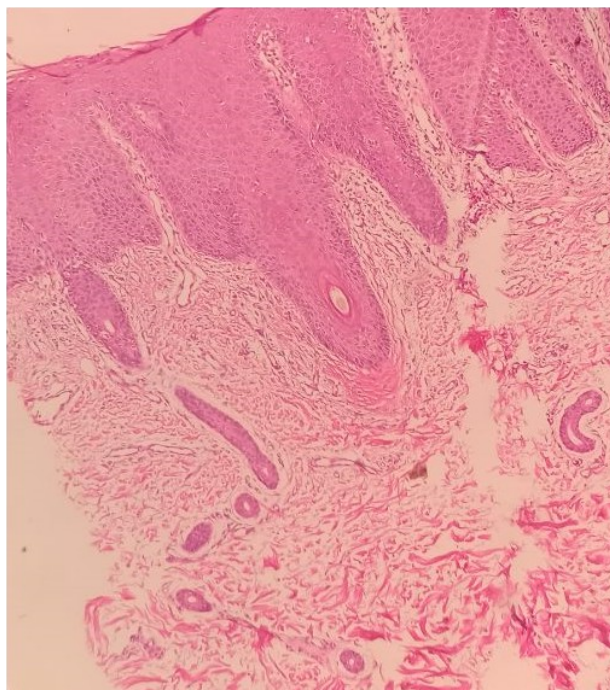


Figure 5: Histopathological schema showing parakeratosis and neutrophilic infiltration in parakeratotic layer (Monro microabscess) and downward elongation of rete ridges. Hypogranulosis, suprapillary thinning accompanied by dilated vessels, perivascular lymphocytic and a few neutrophilic infiltration are also seen, suggestive of psoriasis

