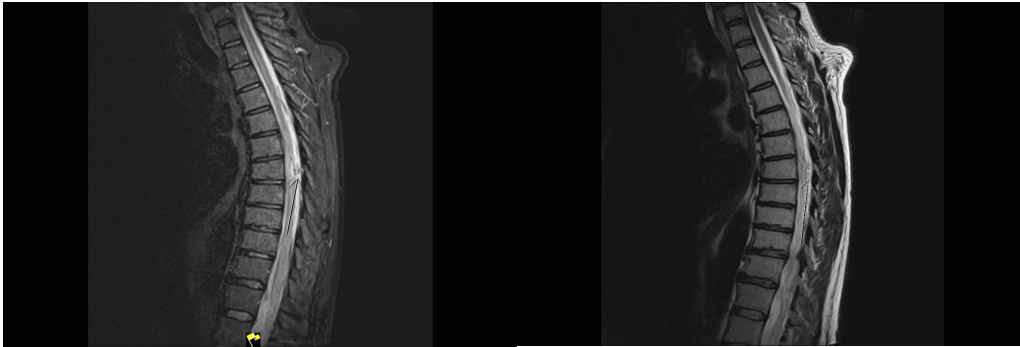
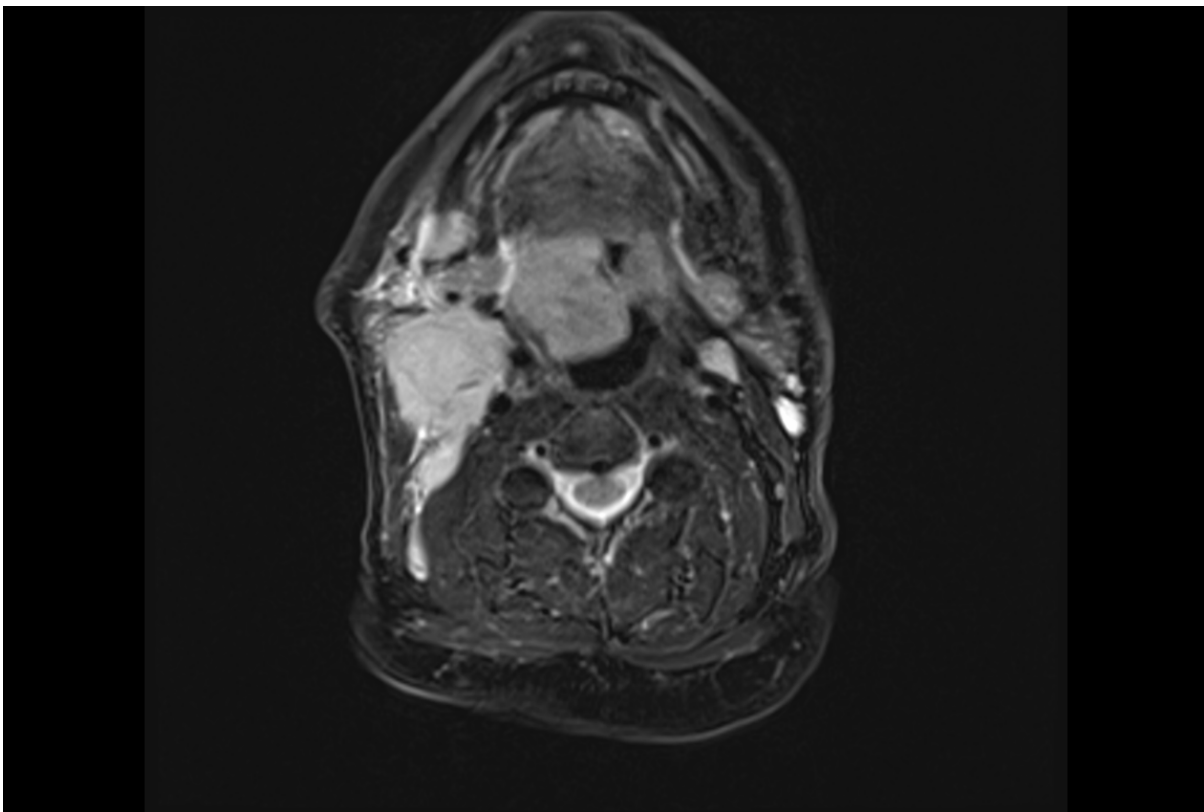


**Figures:**



**Figure 1.** T1 and T2 MRI of the spine demonstrating an enhancing intradural extramedullary lesion at the T7 level of the adjacent cord oedema.



**Figure 2.** MRI of 5.3 cm right tonsillar malignancy centred on the right palatine tonsil. This extends inferiorly to abut and displaces the epiglottis with effacement of the right vallecula. There is lateral involvement of the constrictor muscles and extension across the midline.