

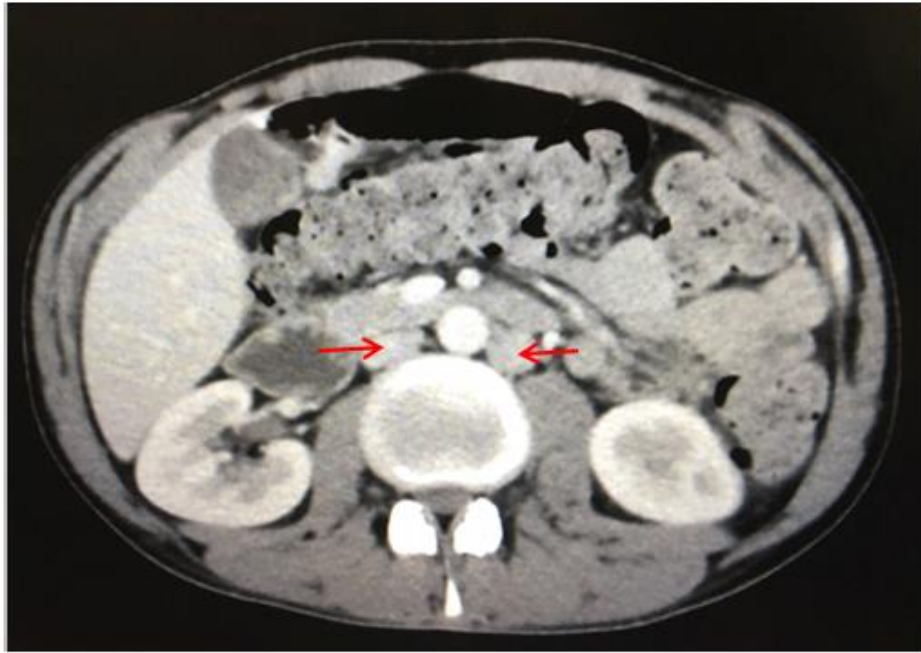

Figure 1: CT scan (sagittal plane): Duplication of the inferior vena cava

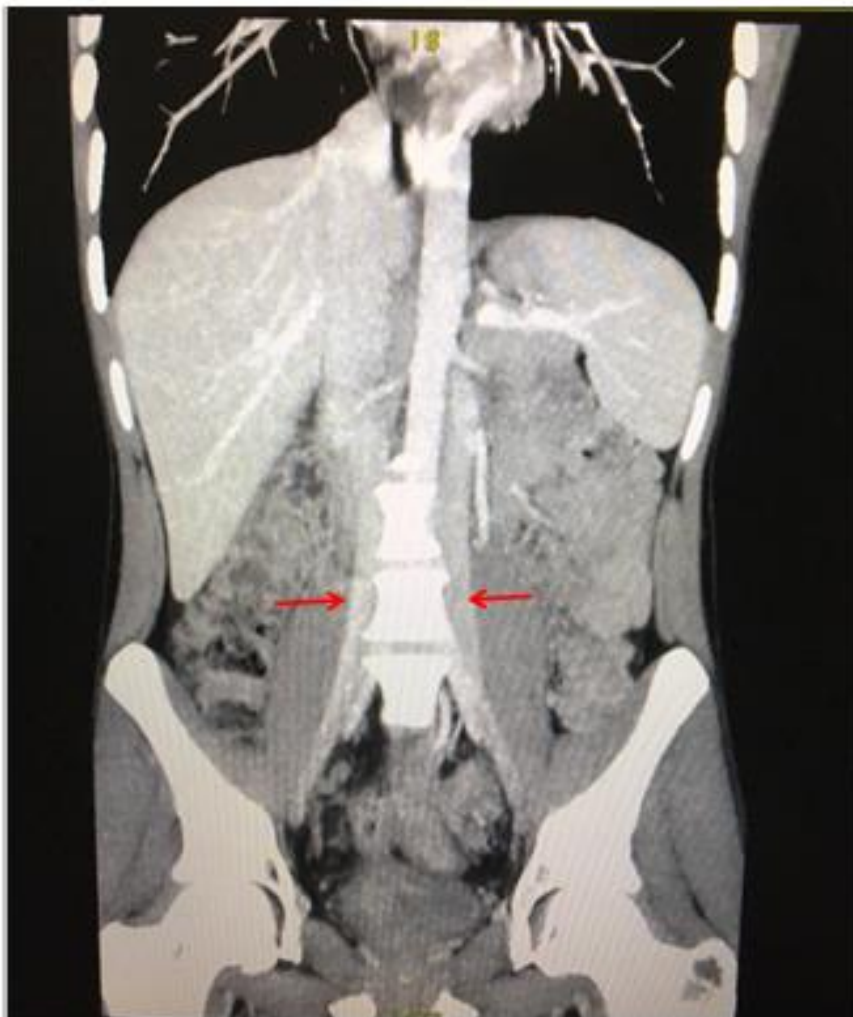


Figure 2: CT scan (coronal plane): Duplication of the inferior vena cava

