

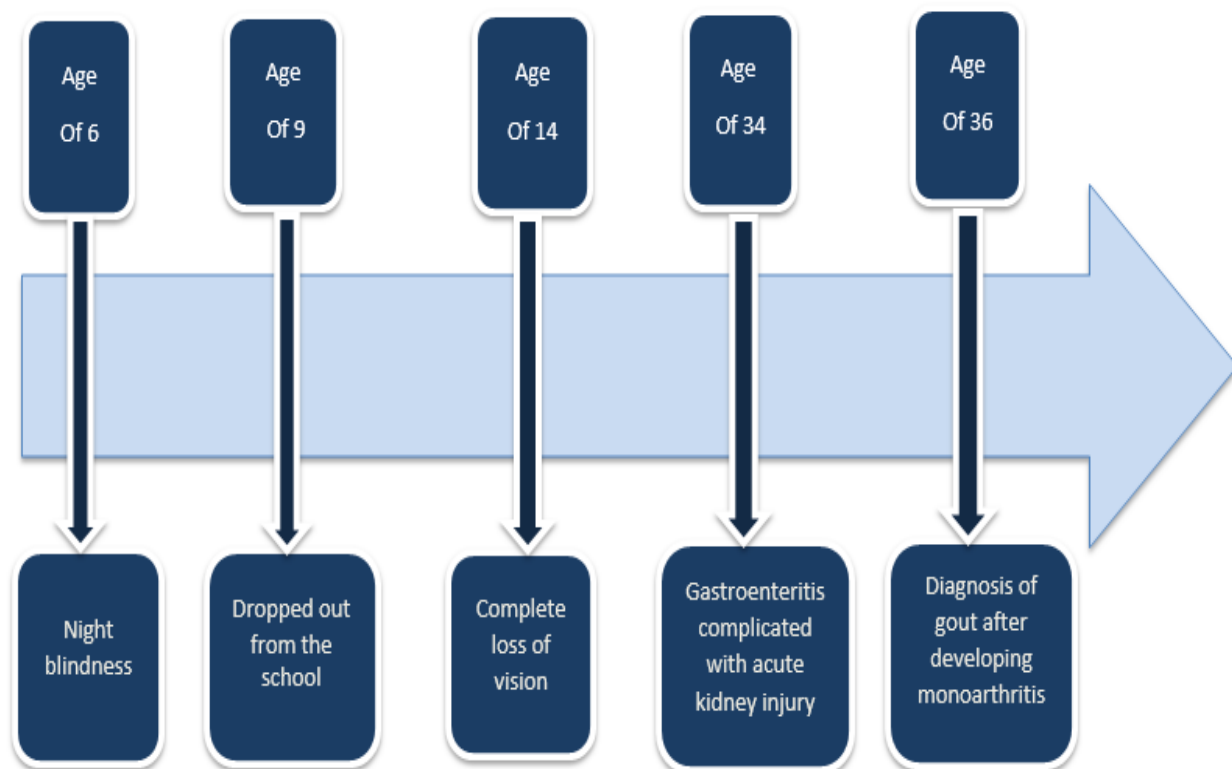Figure [1]: Timeline described her previous events.

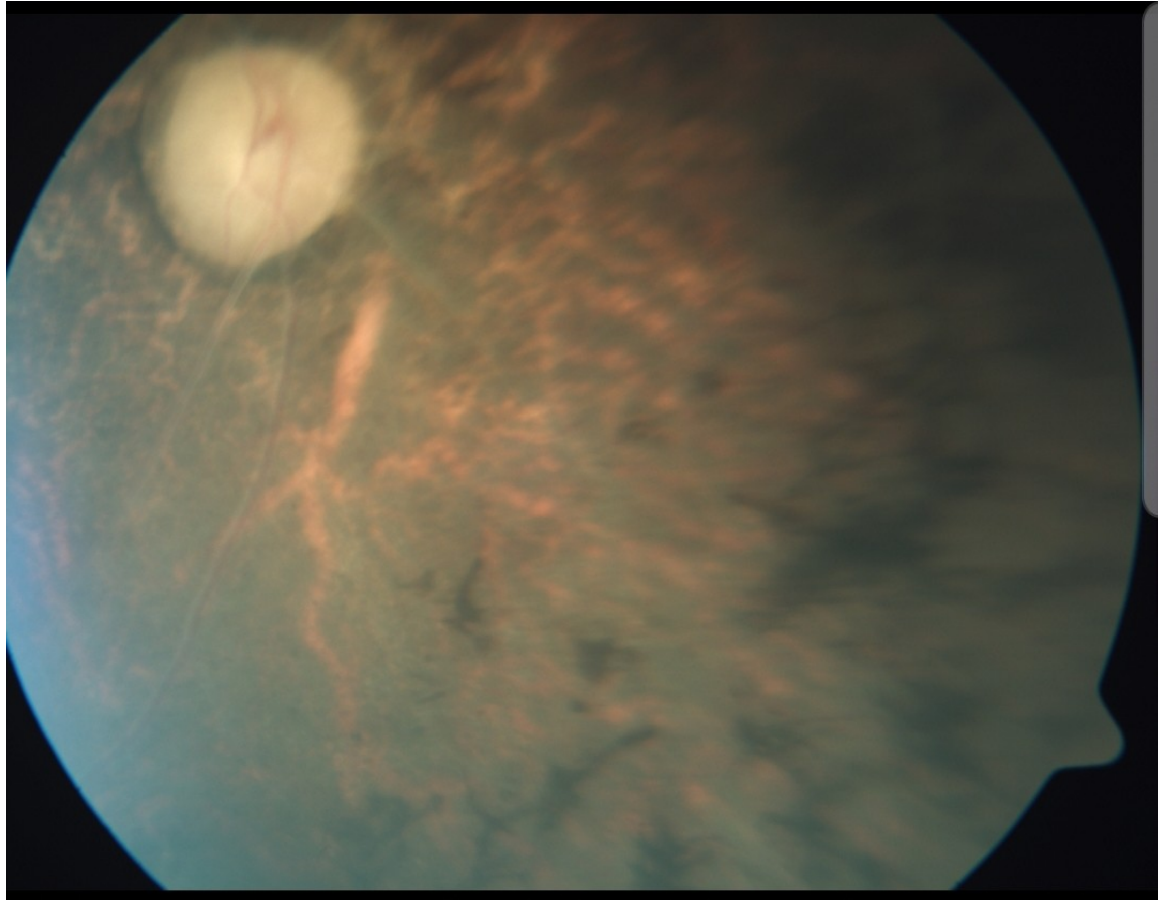


Figure 2: Fundusoscopic picture showed pale optic disc and retinal pigmentation (retinitis pigmentosa)

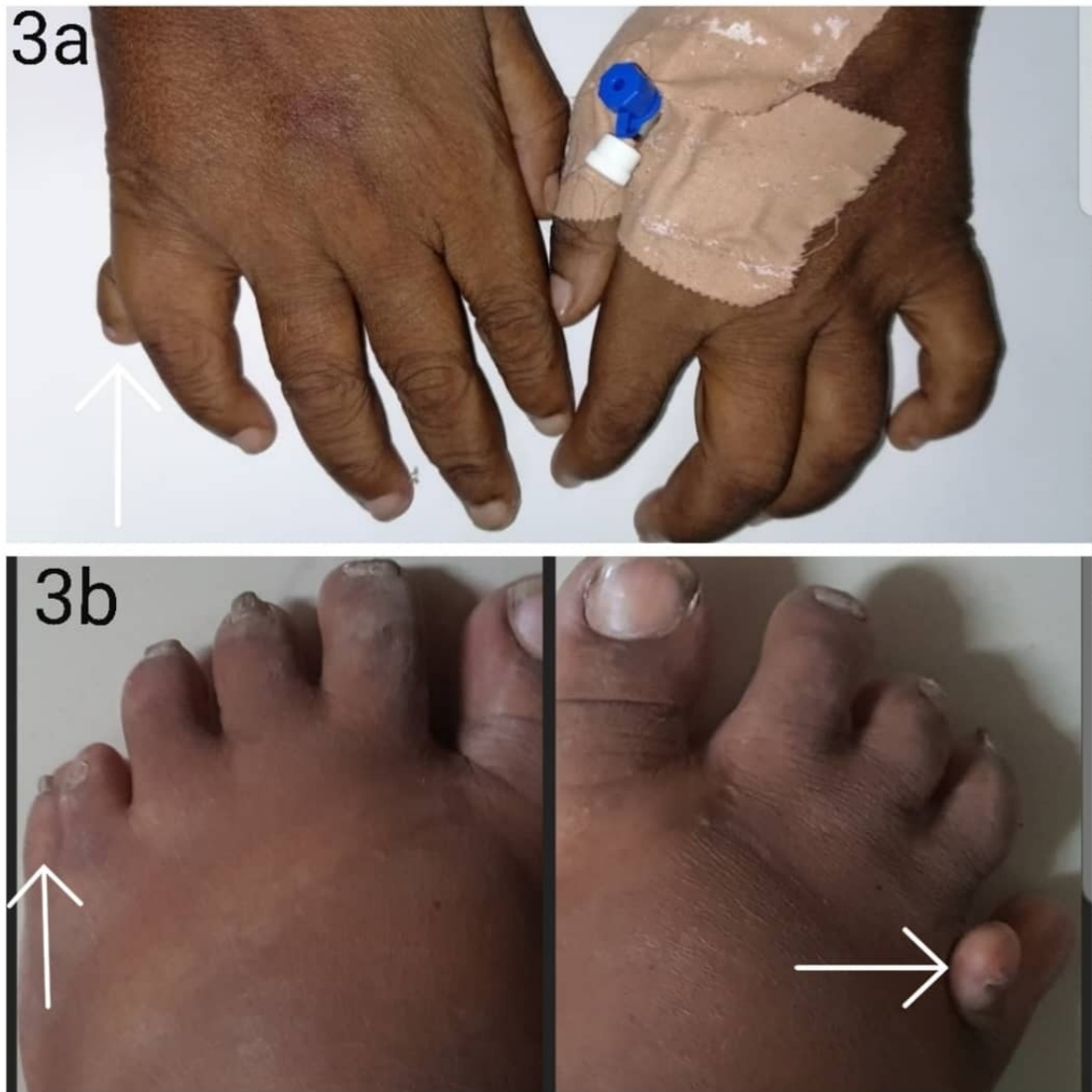

Figure 3: 3a right upper limb postaxial polydactyly, 3b lower limb postaxial polydactyly.

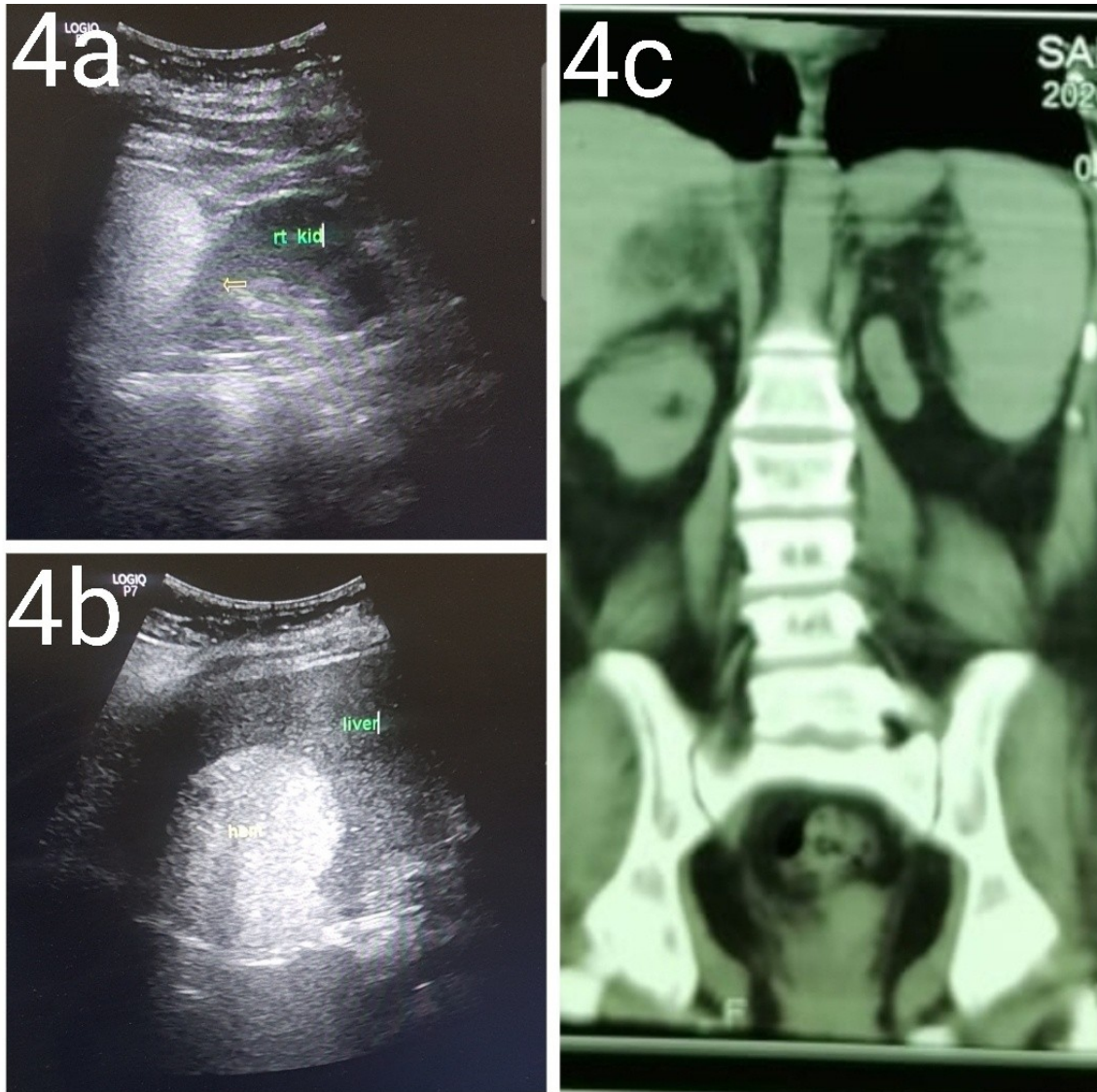


Figure 4: 4a abdominal ultrasound showed small size right kidney 83*32 mm. 4b abdominal ultrasound showed enlarged liver with hyper echoic focal lesion in segment V (features of hepatic hemangioma). 4c CT-KUB showed atrophic left kidney.

