

Figure 1

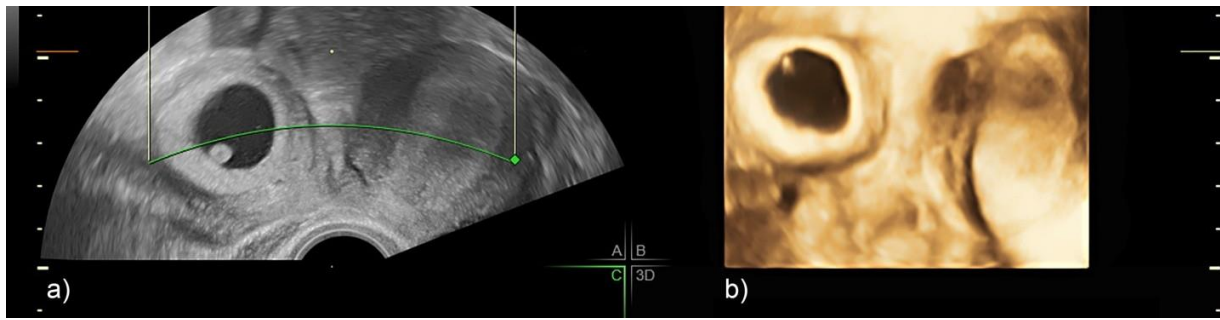


Figure 2

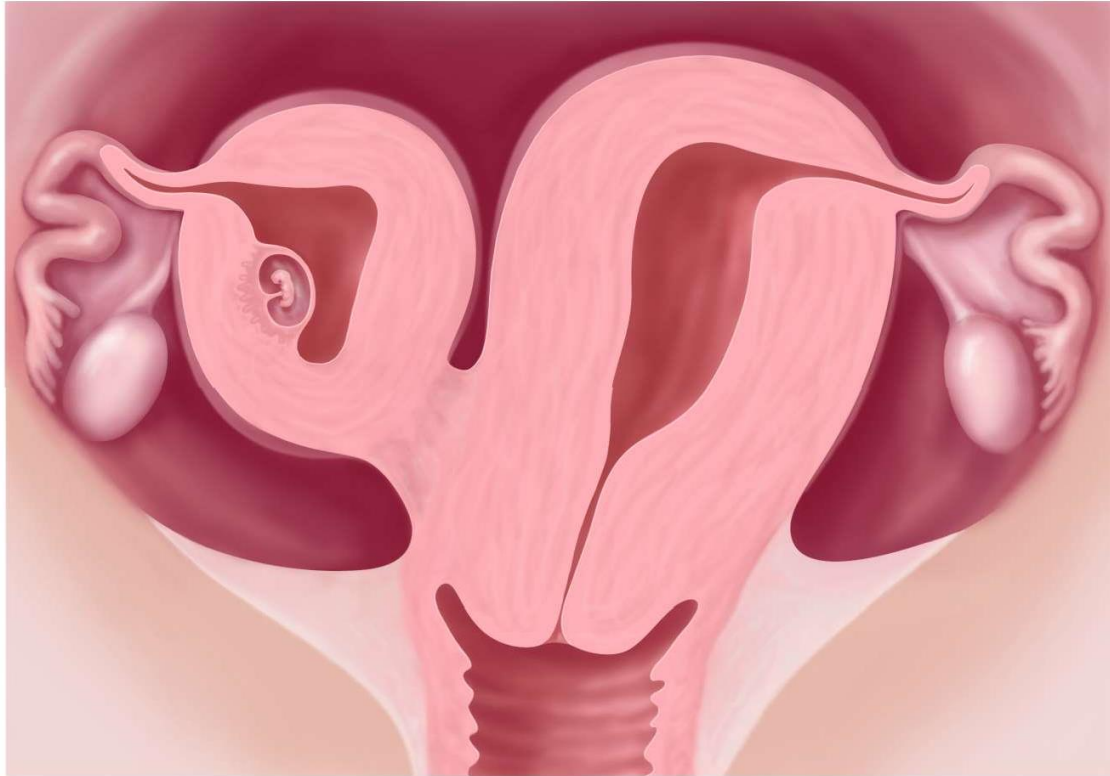


Figure 3

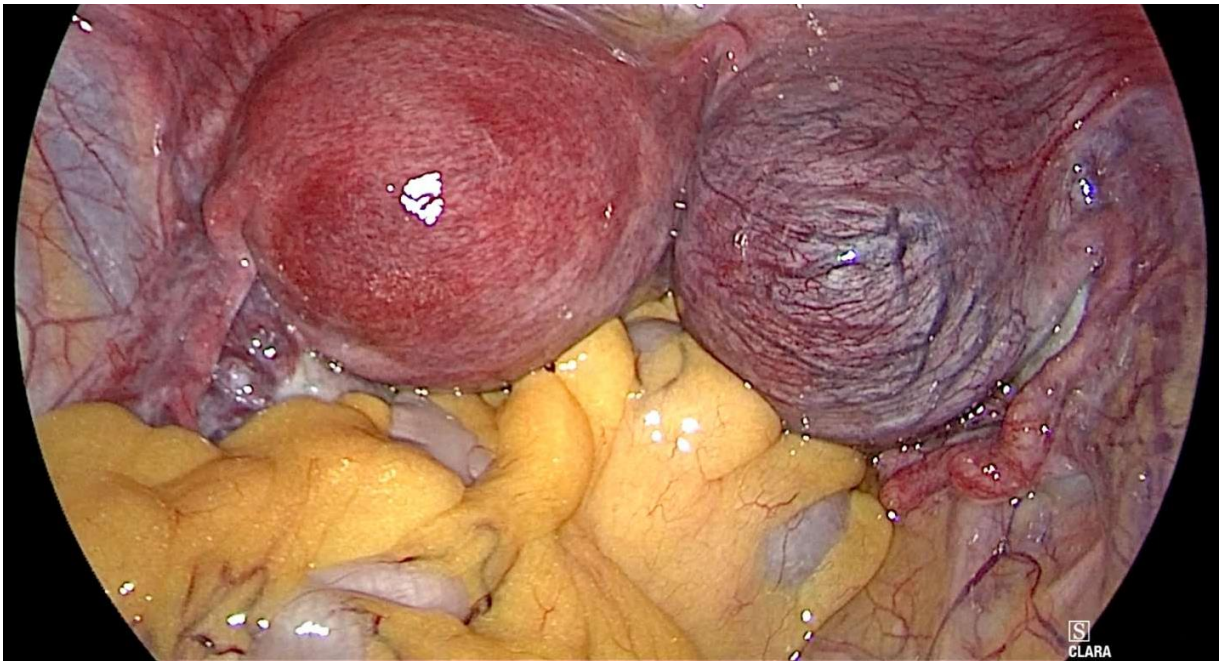


Figure 4A

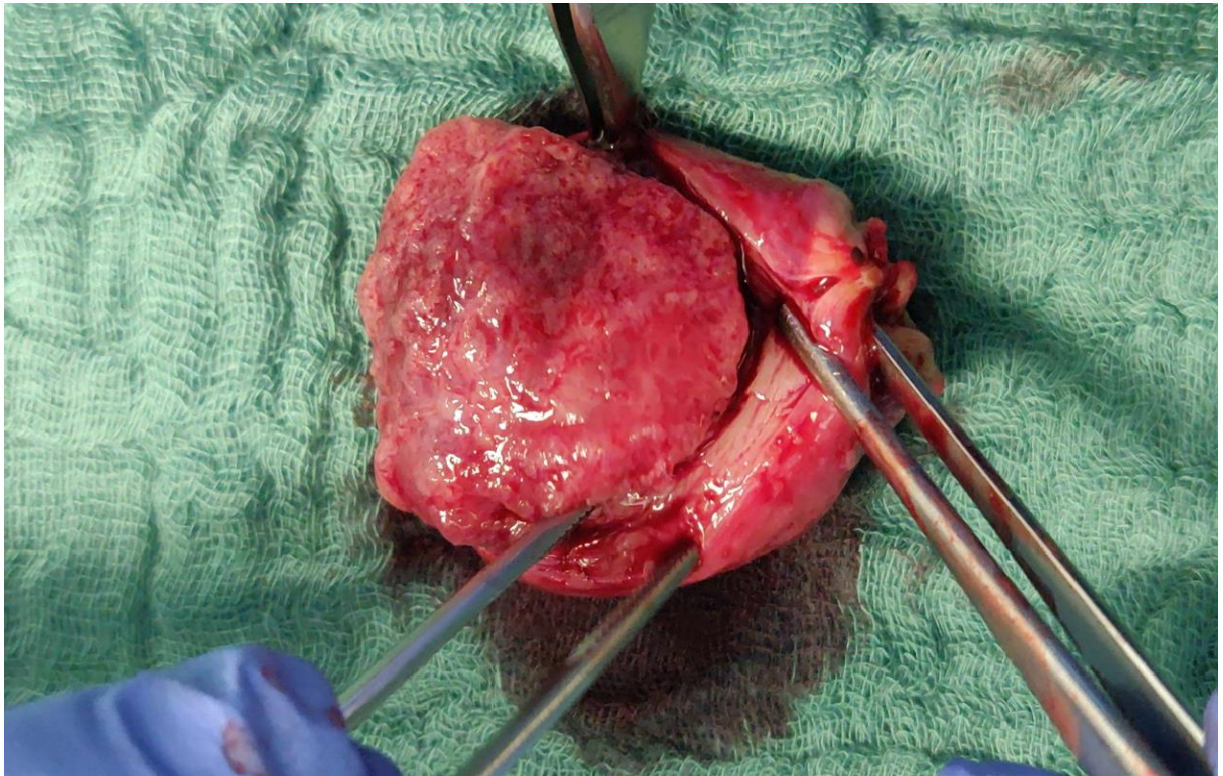


Figure 4B

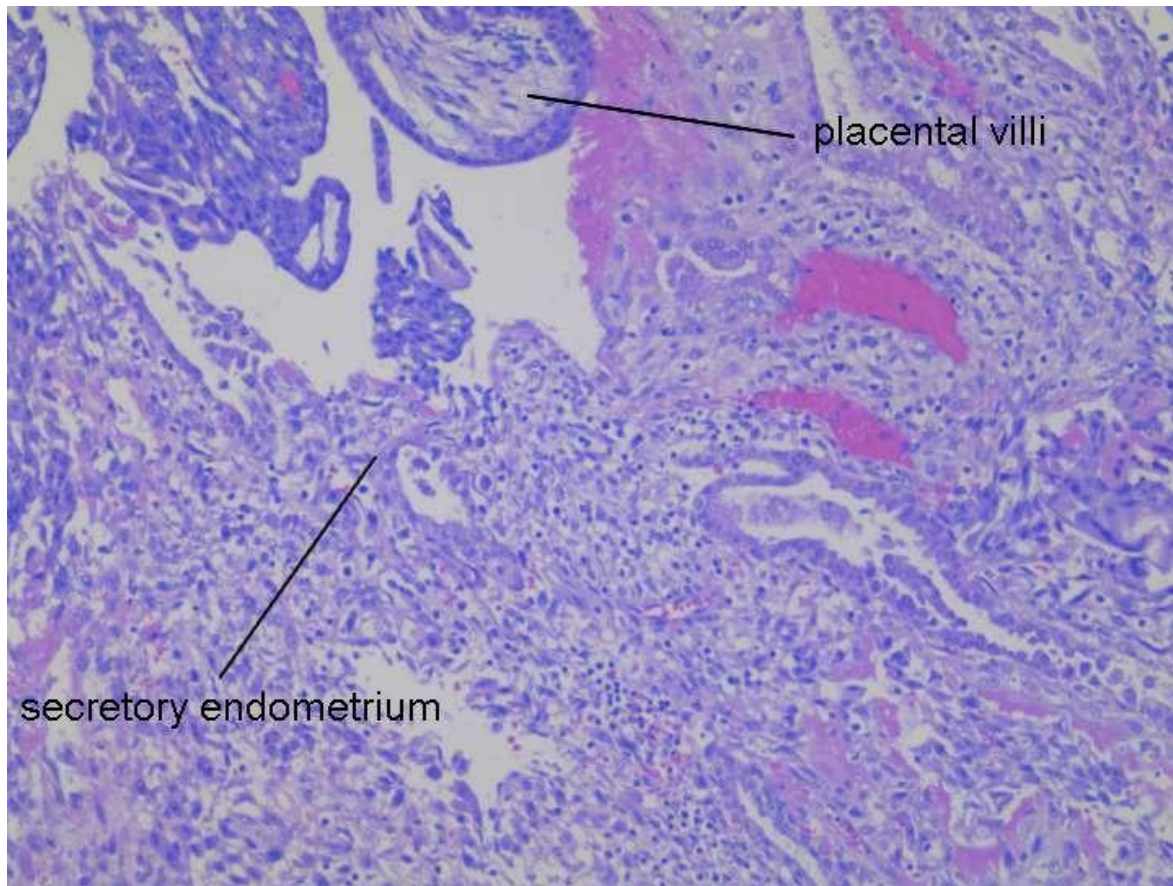


Table 1

USG features[19]	Fallopian tube ectopic pregnancy	Bicornuate uterine pregnancy	Unicornuate uterus with rudimentary horn pregnancy
Two uterine horns	Absent	Present	Present
Ring of myometrium around G-sac	Absent , present in interstitial ectopic pregnancy <5mm [20]	Present	Present
Visual continuity between G-sac and cervix	Absent	Present	Absent