

# COLOSSAL UTERINE LEIOMYOMA IN A ACHONDROPLASTIC FEMALE- A CASE REPORT

Jyotsna Madana<sup>1</sup> and Rathnamma Papanna<sup>1</sup>

<sup>1</sup>Sri Devaraj Urs Academy of Higher Education and Research Medical College

April 16, 2024

## COLOSSAL UTERINE LEIOMYOMA IN A ACHONDROPLASTIC FEMALE- A CASE REPORT

MADANA JYOTSNA PRIYA, RATHNAMMA P

Department of Obstetrics and Gynaecology, Sri Devaraj Urs Medical College, Sri Devaraj Urs Academy of Higher Education and Research (SDUAHER), Tamaka, Kolar, Karnataka, India

### INTRODUCTION:

Uterine leiomyomas- they are the resultant smooth muscle and connective tissue overgrowths which are the most common solid benign uterine neoplasms . About 20-40% of women of age group between 20-35yrs (i.e, reproductive age) present with the uterine leiomyoma. As noted in many studies prevalence increases in reproductive age group and is reduced in women of menopausal age group.<sup>[1,2]</sup> Fibroid uterus have been classified according to their location: Submucosal, intramural, subserosal by FIGO clinical staging. Intramural and submucosal leiomyomas present with many symptoms, while subserosal fibroids are often asymptomatic. The most common symptoms a lady with uterine fibroids present with menorrhagia, dysmenorrhea, infertility, subfertility, pelvic pain, dyspareunia and pressure symptoms resulting in constipation, increased frequency of micturition<sup>[3,4]</sup>. A detailed clinical history, physical and medical examination ultrasonographic examination, computed tomography scanning and magnetic resonance imaging are used often to diagnose fibroids [5]. In this case study, we have aimed to present the surgical management of a colossal uterine leiomyoma in a perimenopausal achondroplastic female with medical comorbidities.

### CASE DESCRIPTION:

A 45-year-old perimenopausal unmarried lady presented with complaints of mass per abdomen which for about 3 months. Mass was insidious in onset, gradually progressive and was occupying whole abdomen, not associated with pain. She was a known case of bronchial asthma and was on rotahalers occasionally. She was a known case of hypothyroidism and was on treatment. She also had a history of mitral valve prolapse since 4 years and was on treatment for the same. The patient's personal history revealed loss of appetite, dyspnea. Her last menstrual period was 1 month back and she had no menstrual abnormalities or irregularities. Vitals of the patient on presentation were within normal limits. On general physical examination, she had kyphosis (FIGURE NO.1) and short limbed dwarfism (? K/C/O Achondroplasia)(FIGURE NO. S1). Her height was 43 cm and weight was 25 kg. On palpation a solid abdominal mass of about 32 weeks gravid uterus size mass was extending from pubic symphysis to halfway between umbilicus and xiphisternum with smooth surface, irregular borders and with a dull note on percussion. Tenderness was not present. On inspection patient had a normal external genitalia. Patient's pelvic organ examination could not be done (perspeculum and pervaginal). The results of routine laboratory testing including a complete blood count, serum electrolyte levels, tumor markers, tests of liver and renal function, thyroid function tests and Pap smear, ECG, Chest x-ray, were within normal limits 2d Echo was done which showed EF of 60% and with

mild mitral regurgitation and mitral valve prolapse. Magnetic Resonance Imaging Abdomen revealed a large pelvicoabdominal heterogenous lobulated mass, approximately 20 cm × 16 cm x 14 cm in size, seen connected with the uterine fundus- s/o Large Uterine fibroid. Ovaries couldn't be appreciated well and were compressed peripherally due to mass. Minimal free fluid noted in pouch of Douglas. Preoperatively, a possible large leiomyoma was suspected and the patient underwent laparotomy. A midline vertical incision was made 1 cm below the umbilicus extending down to 2 cm above the pubic symphysis. Intraoperatively, an enlarged intramural leiomyoma arising from uterine fundus and of 32 weeks size. A multi-septate mass was separated from the lower pole of the left kidney and samples were sent for frozen section. (FIGURE NO. S2). Bilateral ovaries visualized separately with multicystic fluid spaces present in the broad ligament (FIGURE NO. S3). A total abdominal hysterectomy with bilateral salpingo-oophorectomy was performed. After achieving hemostasis, drain was placed in the pouch of Douglas, to drain any blood for the first 24 hours postoperatively. The drain was removed on the first postoperative day, and she was discharged on the 8th postoperative day in excellent condition. Ceftriaxone (Rocephine®), Roche) was applied 1 g twice a day. On histopathological examination revealed a 20 cm × 20 cm × 15 cm, 3600-g intramural, myomatous, cellular leiomyoma (FIGURE NO. S4) and cervix had shown features of chronic cervicitis. Bilateral tubes histology was normal and right fallopian tube paratubal cyst. Sections from right ovary showed corpus albicans and with normal architecture. Sections from the left ovary showed simple serous cyst with fibrous subepithelium. Sections studied from lower pole of the left kidney shows features of angiomyolipoma. Histologic signs of malignancy were not found. The final diagnosis was an intramural uterine leiomyoma with degenerative changes with simple serous cyst of left ovary and Angiomyolipoma of left lower pole of the kidney.

## DISCUSSION:

Achondroplasia, a multifactorial disorder of bone growth, is a most common type of short-limbed dwarfism<sup>[6][7]</sup> particularly in the long bones of the arms and legs and is characterized by dwarfism, reduced range of motion at the elbows, big head (macrocephaly), small fingers, and normal IQ. The condition occurs in 1 in 15,000 to 40,000 newborns worldwide.<sup>[8][9][10]</sup> No particular race has been documented to be more commonly affected.<sup>[5]</sup> It is caused by mutations in the FGFR3 gene. Most cases of achondroplasia are not inherited.<sup>[4]</sup> If inherited, inheritance is autosomal dominant.<sup>[6][7]</sup>

Uterine fibroids are benign tumors that are more prevalent in the reproductive age group. Many studies suggest that activated receptor tyrosine kinases (RTKs) play a major role in proliferation of fibroids. In Linda Yu et al study,<sup>(11)</sup> they found that fifteen out of seventeen RTKs activity was highly expressed in the leiomyomas, and included the IGF-I/IGF-IR, EGF/EGFR, FGF/FGF-R, HGF/HGF-R, and PDGF/PDGF-R gene families which was done by a phospho-RTK array technique.

Ultrasonography is most commonly done for the initial evaluation, as it is the least invasive and cost-effective technique. Magnetic resonance imaging is the gold standard in ruling out the pathology. Expectant management, medical and surgical approaches, or uterine artery embolization are used in treating uterine fibroids. The choice of treatment depends on the patient's age, type and severity of symptoms, suspicion of malignancy, desire for future fertility and proximity to menopause. Surgical approach is done in management of large uterine fibroids. This case represents a successful surgical management of an unmarried perimenopausal patient with large uterine leiomyoma and with many medical illnesses. Factors like reproductive factors, age, race, hormones, obesity, lifestyle, environmental conditions and infection were associated with the development of uterine fibroids<sup>[12]</sup>. The most common symptomatology in women with fibroids are pelvic pain, menorrhagia, tumor bulk-related symptoms, fatigue, loss of appetite, dyspnea. On the other hand, some may not have any symptoms. Surgical treatment differs according to the patient factors and are the following: Menorrhagia not responding to medical therapy, suspicion of malignancy, unexplained infertility, fibroids growing after menopause, the presence of symptoms that have a negative effect on daily life<sup>[13]</sup>. Transverse vertical incision of the abdominal wall may be planned for operation. According to the ACOG guidelines, oophorectomy should be done at the time of hysterectomy in postmenopausal women<sup>[14]</sup>. She was treated with a total abdominal hysterectomy with bilateral salpingo-oophorectomy and she was discharged on the seventh postoperative day in excellent condition. Careful pre-anesthetic evaluation, perioperative management and

multidisciplinary workup will help in preventing morbidity and mortality associated in this kind of cases.

**Contribution of authorship:**

Collected the data and designed the case report: Dr Madana Jyostna Priya

Contributed data and Performed the analysis: Dr Rathnamma P.

**Disclosure of interest :** Nothing

**Funding resources :** Nothing

Patient's consent: Enclosed

**Images:**



FIGURE NO.1- KYPHOSIS

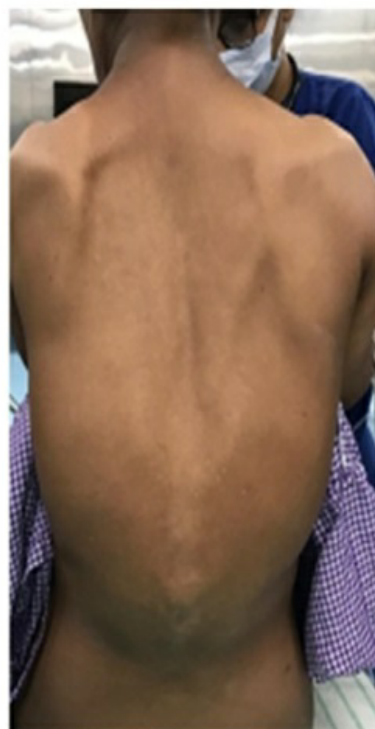

FIGURE NO.2

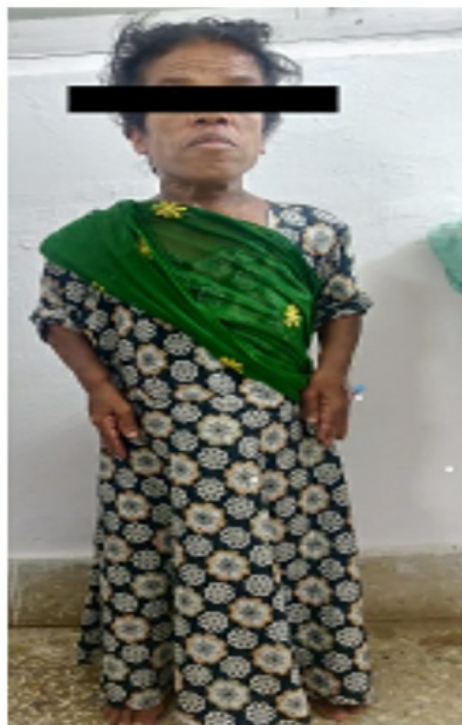

FIGURE NO. 3



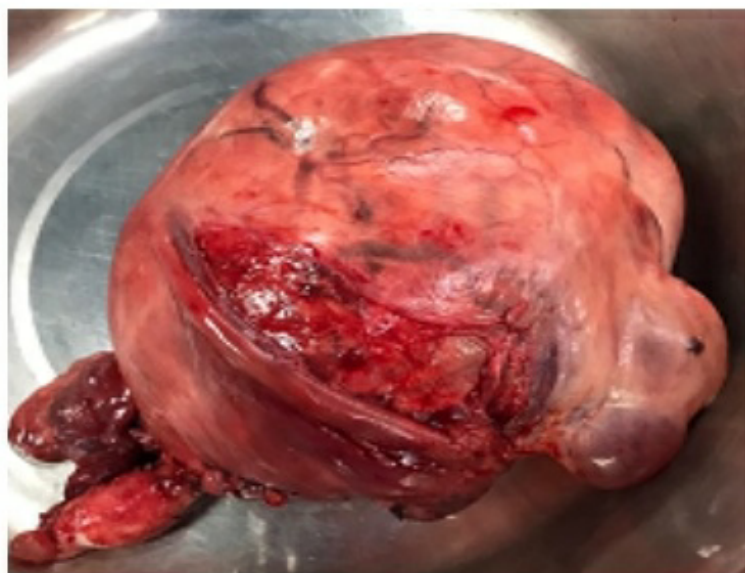
FIGURE NO . 4

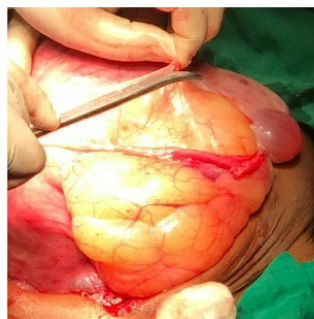

FIGURE NO. 5- LOWER POLE OF  
THE KIDNEY

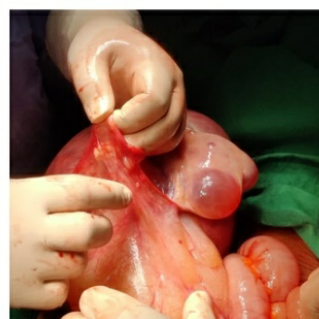

FIGURE NO. 6 MULTIPLE CYSTIC  
OVARY



**FIGURE NO. 7- GROSS SPECIMEN**

*References :*

1. Sparic R, Mirkovic L, Malvasi A, Tinelli A (2016) Epidemiology of uterine myomas: A review. *Int J Fertil Steril* 9: 424-435.
2. Okolo S (2008) Incidence, aetiology and epidemiology of uterine fibroids. *Best Pract Res Clin Obstet Gynaecol* 22: 571-588.
3. Levy BS (2008) Modern management of uterine fibroids. *Acta Obstet Gynecol* 87: 812-823.
4. Evans P, Brunsell S (2007) Uterine fibroid tumors: Diagnosis and treatment. *Am Fam Physician* 75: 1503-1508.
5. Parker WH (2007) Etiology, symptomatology, and diagnosis of uterine myomas. *Fertil Steril* 87: 725-736.
6. Achondroplasia. Genetics Home Reference. May 2012; <http://ghr.nlm.nih.gov/condition=achondroplasia>.
7. Pauli RM. Achondroplasia. GeneReviews. February 2012; <http://www.ncbi.nlm.nih.gov/books/NBK1152/>.
8. Bacino CA. Achondroplasia. UpToDate. November 15, 2017; <https://www.uptodate.com/contents/achondroplasia>.
9. Learning About Achondroplasia. National Human Genome Research Institute (NHGRI). May 11, 2012; <http://www.genome.gov/19517823>.
10. Defendi GL. Genetics of Achondroplasia. Medscape Reference. May 16, 2014; <http://emedicine.medscape.com/article/941280-overview>
11. Linda Yu, Katrin Saile, Carol D Swartz, Hong He, Xiaolin Zheng, Grace E Kissling, Xudong Di, Shantelle Lucas, Stanley J Robboy, Darlene Dixon, *Mol Med*. Differential Expression of Receptor Tyrosine Kinases (RTKs) and IGF-I Pathway Activation in Human Uterine Leiomyomas 2008 May-Jun; 14(5-6): 264–275.

12. Mülâyim B (2015) Unaware of a large leiomyoma: A case report with respect to unusual symptoms of large leiomyomas. *Ann Med Surg (Lond)* 4: 431-433.
13. Yavuz A, Astepe B, Terzi H, Kale A (2015) Management of uterine giant myoma: Case report. *Sakaryamj* 5: 34-38.
14. American College of Obstetricians and Gynecologists (2008) Clinical management guidelines for obstetrician-gynecologists. *ACOG Practice Bulletin* 89 Washington, DC, 231-241.