Posted on 31 Jan 2024 | The copyright holder is the author/funder. All rights reserved. No reuse without permission. | https://doi.org/10.22541/au.170666087.71027683/v1 | This is a preprint and has not been peer-reviewed. Data may be preliminary.

Diagnostic Properties of RDC/TMD Criteria for TMJ Internal Derangement versus MRI Gold Standard.

Li Feng[1], Zhao Yang[2], Shiyue Chen[2], Jianghua Wan[3], Sanjay Rastogi[4], and Rupshikha Choudhury[4]

[1]Chengdu First People's Hospital
[2]First Affiliated Hospital of Naval Military Medical University
[3]The First Affiliated Hospital of Hainan Medical University
[4]Regional Dental College

March 07, 2024

Abstract

Objective: To correlate the clinical RDC/TMD findings with Magnetic resonance imaging (MRI) as a diagnostic aid in the internal derangement of TMJ. Methods: The present study consists of a total sample size of 14 subjects clinically diagnosed with the internal derangement of TMJ. According to the set criteria by Research Diagnostic Criteria for Temporomandibular disorders (RDC/TMD), the subjects were subjected to MRI after a thorough evaluation. The diagnostic findings were compared with MRI. The data obtained were statistically analyzed using the specificity, sensitivity, and kappa coefficient. Results: Twenty-five percent of sensitivity and fifty-seven percent of specificity were observed for RDC/TMD diagnosis regarding MRI in the total sample. Kappa value was found to be in the moderate range. Conclusion: The clinical findings based on RDC/TMD alone were not sufficient for the diagnosis of TMJ, and MRI's internal derangement still a "golden standard" among the other modalities.

Diagnostic Properties of RDC/TMD Criteria for TMJ Internal Derangement versus MRI Gold Standard

Objective: To correlate the clinical RDC/TMD findings with Magnetic resonance imaging (MRI) as a diagnostic aid in the internal derangement of TMJ.

Methods: The present study consists of a total sample size of 14 subjects clinically diagnosed with the internal derangement of TMJ. According to the set criteria by Research Diagnostic Criteria for Temporomandibular disorders (RDC/TMD), the subjects were subjected to MRI after a thorough evaluation. The diagnostic findings were compared with MRI. The data obtained were statistically analyzed using the specificity, sensitivity, and kappa coefficient.

Results: Twenty-five percent of sensitivity and fifty-seven percent of specificity were observed for RDC/TMD diagnosis regarding MRI in the total sample. Kappa value was found to be in the moderate range.

Conclusion: The clinical findings based on RDC/TMD alone were not sufficient for the diagnosis of TMJ, and MRI's internal derangement still a "golden standard" among the other modalities.

KEYWORDS: Internal Derangement of TMJ; MRI; RDC/TMD.

What is already Known?

Internal Derangement of Temporomandibular joint is a recurrent problem in the pre-auricular region. Often misdiagnosed and leads to mistreatment. Contemporary literature shows that Research Diagnostic criteria

of Temporomandibular Disorders (RDC/TMD) are commonly used among the physicians for the diagnosis of the same problem.

What's New?

The results of this study suggest that RDC/TMD criteria for internal derangement alone are not sufficient, and it may be supplemented by the use of MRI so that a proper treatment protocol can be generated for the patient.

Introduction

Internal derangement of the Temporomandibular Joint (TMJ) is an organic disease, and attempts have been made to identify TMJ disc displacement's clinical symptoms. Several studies were done to identify clinical signs and symptoms that were predictive of the joint's status. Various diagnostic imaging techniques were performed, which contributed to the proper diagnosis of TMJ disorders. The most standard and most well-established technique for examining the TMJ radiographically is the transcranial projection. Even more precise depictions of the osseous changes were gained from tomography than from transcranial radiography. With the advent of newer advanced modalities like CT and MRI, both soft and hard tissues can now be viewed in nearly any desired plane of reference with considerable accuracy[1-3].

All imaging techniques are not equally effective for each of the different condition that affects the TMJ. The efficacy of any imaging examination rests not just with its technical adequacy but also with its diagnostic accuracy, a complex interaction between the images and the person interpreting it. Besides, the increasing sophistication of imaging techniques does not guarantee a better diagnosis of the patient[4,5].

The accuracy of clinical examination for diagnosing the exact status of TMJ internal derangements has been investigated in several previous studies[6-9], which have reported the clinical examination's overall accuracy as 43% to 95%.

False-positives diagnoses are related to over-classification of the disease, which might lead to over-treatment, while false negative diagnoses are related to under-classification and consequently under-treatment[8]. Now the question arises, how to establish an accurate diagnosis for the internal derangement of the TMJ? Despite various advances in the field of clinical diagnosis of temporomandibular disorders and imaging modalities, i.e., various modifications done in the RDC/TMD since its advent by various societies on temporomandibular joint and imaging technologies, the question remains the same about the best diagnostic criteria and imaging module in order to diagnose the internal derangement of the TMJ.[2-4]

In order to resolve the confusion regarding the diagnosis and management of the TMD, it was felt necessary to study and compare the efficacy of RDC/TMD diagnostic criteria and MRI as a diagnostic aid in the internal derangement of TMJ. Furthermore, to find out whether RDC/TMD criteria alone is enough for diagnosing the internal derangement of TMJ or its combination with MRI is required whenever seeing the patient with internal derangement. A study was planned to compare the efficacy of RDC/TMD alone or in combination with MRI to diagnose the internal derangement of TMJ.

The study's specific focus was to correlate the findings of RDC/TMD with advanced imaging techniques like MRI as a diagnostic aid in the Temporomandibular joint's internal derangement (TMJ).

Materials and Methods:

This prospective study was conducted at the Department of Oral and Maxillofacial Radiology, performed from October 2016 to October 2019. The Institutional Review Board and the local ethical committee have approved the study after registration with the Research Center (protocol HMU # RC/IRB/2016/1040). This study followed the criteria as declared by Helsinki. All participants signed provided written informed consent after a full explanation of the process's procedure and safety. According to the set criteria, those who were not ready or failed to report were excluded from the study.

In this study, adult patients without any systemic complications, who strictly met the inclusion criteria, were

Posted on 31 Jan 2024 | The copyright holder is the author/funder. All rights reserved. No reuse without permission. | https://doi.org/10.22541/au.170666087.71627683/v1 | This is a preprint and has not been peer-reviewed. Data may be preliminary.

included. The subjects' clinical inclusion criteria were assessed on the following five clinical characteristics that were/are the modification of those described initially by Okeson[10]. The inclusion criteria were; Limited mouth opening; Deflection of the mandible to the affected side at the maximal mouth opening, TMJ pain at the pre-auricular region during mandibular movement; Limitation of condylar translation to the maximal mouth opening; Crepitation during mouth opening and/or closing movement. The exclusion criteria were patients with cerebral aneurysm clip, cardiac pacemaker, skeletal jaw deformity, undergoing orthodontic treatment, history of traumatic extraction, claustrophobic and uncooperative, pregnant patient, and metallic prosthesis heart valves, ferromagnetic foreign bodies in a critical location like the eye.

Each patient was subjected to the clinical diagnostic process. In accord with the Research Diagnostic Criteria (RDC/TMD) [11], the diagnostic process used a standardized clinical head and neck examination that included palpation of the TMJ and muscles of mastication for pain, palpation of joint sounds, and measurement of the range of motion[3].

According to the RDC/TMD criteria, a total of 14 symptomatic patients with clinically diagnosed internal derangement of TMJ according to the RDC/TMD criteria were included in this study group. All volunteers were examined and were accepted for the study after completing the following evaluation-

A subjective questionnaire to document the absence of jaw pain, joint noise, locking and history of TMD.

Clinical TMJ and dental examination for signs and symptoms usually associated with internal derangement.

The symptomatic patients were selected from 14 consecutive subjects who were evaluated at the Department of Oral Medicine, Diagnosis, and Radiology.

Bilateral TMJ magnetic resonance images were obtained of all 14 patients employing Higher 1.5 Tesla magnet (General Electric). Pulse sequences were obtained from all patients in closed-mouth position and maximal mouth opening positions on corrected sagittal and coronal T1 weighted; proton density (PD) and T2 weighted images.[3]

MRI images were prescribed graphically perpendicular (sagittal images) and parallel (coronal images) to the condyle's horizontal long axis. The maximum intercuspation position was used for closed mouth images and maximum mouth opening for open mouth images.

The disc's position was analyzed and grouped into one of the categories described by Tasaki et al. [12]. Disc function was analyzed as usual, displaced with reduction or without reduction, or indeterminate. The normal function was noted when a disc in the superior position in the closed mouth position interposed between the condyle and the articular eminence in the open mouth position. The reduction was noted when a displaced disc in the closed mouth position assumed a position interposed between the condyle and the articular eminence in the open mouth position. No reduction was noted when the displaced disc in the closed mouth position did not achieve a position between the condyle and the articular eminence in the open mouth position.

Indeterminate disc function was noted when the disc could not be identified because of the artifact or post-surgical scaring[13]. Osseous components were classified as normal or abnormal.

The TMJs were classified according to the following MR criteria[8]-

Normal state (No Disc Displacement; NDD) - in the sagittal plane of imaging, the disc had a biconcave shape (an anterior band; an intermediate zone, the thinnest portion; a posterior band, the thickest portion). In a closed-mouth position, the posterior band's junction with the bilaminar zone was located above the apex of the condylar head (12 o'clock position). When the jaw opens, the condyle rotates under the disc, and the disc-condyle complex translates inferiorly under the temporal tubercle. The disc remains interposed between the osseous component and moves anteriorly in a synchronized fashion. The disc has an arc-shaped configuration in the coronal plane of imaging due to its insertions at the condylar pole. The disc is perfectly centered on the condylar head in an open and closed-mouth position.

Posted on 31 Jan 2024 | The copyright holder is the author/funder. All rights reserved. No reuse without permission. | https://doi.org/10.22541/au.170666087.71627683/v1 | This is a preprint and has not been peer-reviewed. Data may be preliminary.

(Figure 1).

Anterior disc displacement with reduction (ADDWR):- In the closed position, the disc's posterior band is anterior to the condylar head in all the sagittal sections. When the jaw is opened, the disc is recaptured by the condyle, and the disc condyle relation appears normal. Figure 2

Anterior disc displacement without reduction (ADDWOR):- In close and open mouth position, the disc's posterior band is anterior to the condylar head's superior aspect in all sagittal sections. When the jaw is opened, the disc is anteriorly compressed, whether its shape is modified or not. Figure 2

Sideways displacement (medial or lateral):- Sideways displacements of the disc are well documented in the coronal plane. The disc crosses over one of the sagittal plane tangents to one of the condylar poles. Figure 3

Rotational displacement was present when the disc was anteriorly displaced in all sagittal sections, together with a sideway component (medial or lateral), whether it is reduced or not, according to the definition of Katz berg.

Stuck disc or disc adhesion:- During jaw movement, the disc remains in the same place in relation to the mandibular fossa or the articular tubercle. The stuck disc may be fixed in a normal or displaced position and may or may not be associated with the condyle's normal mobility.

Degenerative changes: Flattening, erosion, changes in the shape of the articular surfaces, anterior osteophytes, and/or subchondral lacunas were classified as a degenerative joint disease (osteoarthritic joint). The sharpness of the cortical limits was not considered: chemical shifting may produce artifacts in the MR images.

Restricted condylar translation: Limitation of translation was identified when the condylar head did not reach the apex of the articular tubercle of the temporal bone during the opening, with or without the disc – condyle complex dislocation.

All radiograph s and images were evaluated for a set criterion to determine osseous and soft tissue changes in the TMJ.

Statistical Analysis .

Data were subjected to statistical analysis using SPSS 22.0 (SPSS, Inc., Chicago, IL). Statistical tests used for analyzing data were mean and standard deviation and unpaired t-test.

Statistical analyses were undertaken to correlate the radiography/imaging findings to the clinical signs and symptoms in the internal derangement according to RDC/TMD criteria. Data were subjected to statistical analysis using SPSS 22.0 (SPSS, Inc., Chicago, IL). Statistical tests used for analyzing data were sensitivity&specificity tests and inter-observer reliability correlation through the Kappa test.

RESULTS

Joint tenderness was the most frequent clinical finding (18 out of 28 joints) (64%), followed by joint noise (16 out of 28 joints) (57%), muscle tenderness (10 out of 28 joints) (36%), and deflection/deviation was found only in 9 out of 28 joints (32%) and was the least frequent clinical finding in the present study. Thirty-six percent (36%) of the patients showed limited mouth opening (5 out of 14 patients).

14 joints were clinically diagnosed as ADDWR (50%) out of a total of 28 joints and were the most prevalent in RDC diagnostic subgroups, whereas 3 joints were clinically diagnosed to be ADDWOR (11%) and were least prevalent among the RDC diagnostic subgroups. 13 joints were diagnosed as No disc displacement (NDD) (39%).

Out of 28 TM, joints-13 were diagnosed by MRI as No Disc Displacement (NDD) (46.4%), MRI diagnosed 11 as ADDWR (39.3%), 2 were diagnosed by MRI as ADDWOR (7.1%), and 2 joints were categorized as others (7.1 %) {Others-Disc was not seen in MRI}.

Posted on 31 Jan 2024 | The copyright holder is the author/funder. All rights reserved. No reuse without permission. | https://doi.org/10.22541/au.170666087.71627683/v1 | This is a preprint and has not been peer-reviewed. Data may be preliminary.

Out of 28 TMJ joints (14 patients), 11 were diagnosed normal with RDC/TMD criteria; among these 11 normal TMJ joints, 4 were confirmed as normal by MRI (the remaining 7 joints were diagnosed as ADDWR). Out of 28 TMJ joints (14 patients), 14 were diagnosed ADDWR with RDC criteria; among these 14, 3 were confirmed as ADDWR by MRI (out of the remaining joints, 8 joints were diagnosed as NDD and 2 as ADDWOR). Out of 28 TMJ joints (14 patients), 3 were diagnosed ADDWOR with RDC criteria; among these 3 TMJ joints, MRI has shown 1 ADDWR, 1 NDD and 1 as others.

RDC/TMD diagnosis's sensitivity and specificity concerning MRI findings were (36.4%) of sensitivity and (63.6%) of specificity of RDC diagnosis was found for NDD. (21.4%) of sensitivity and (57.4%) of specificity of RDC diagnosis was observed for ADDWR. (0%) of sensitivity and (33%) of specificity of RDC diagnosis was observed for ADDWOR. Twenty-five percent (25%) of sensitivity and Fifty-seven point one percent (57.1%) of specificity were observed for RDC diagnosis with respect to MRI in the total sample.

A comparison of clinical examination findings with MRI diagnosis is summarized in Table 1.

Consensus inter-observer diagnosis was taken from the three different observers, who interpreted the MRI findings individually. Each observer was blind to each other's MRI analysis and the RDC clinical diagnosis.

For left TMJ, Kappa values were analyzed between observer 2 and observer 1 and were found to be 0.421. (Moderate). Kappa values were analyzed between observer 2 and observer 3 and were found to be 0.413 (Moderate).

For Right TMJ, Kappa values were analyzed between observer 2 and observer 1 and were found to be 0.407. (Fair). Kappa values were analyzed between observer 2 and observer 3 and were found to be 0.412. (Moderate). Table 2-5

DISCUSSION

The present study investigated the accuracy of clinical findings in determining the presence or absence of internal derangement of TMJ according to the set criteria by RDC/TMD and the superior diagnostic imaging modality like magnetic resonance imaging (MRI).

For this study, 14 patients between 11 to 40 years of age were selected. The control group of 5 healthy volunteers without any sign & symptoms of TMD showed a different age distribution; they were between 20 to 30 years.

Out of a total of 14 patients, the study consisted of 9 female & 5 male patients. The ratio of female to male in this group of patients with TMDs was 1.8:1. The results of this study show that the prevalence of TMDs was higher in women than in men. Several related studies have reported comparable results[10,14].

In the present study, the author has investigated the accuracy of five clinical parameters for determining the presence or absence of anterior disc displacement. The MRI findings obtained from 28 joints with TMDs were compared with their initial visits' clinical findings. The sensitivity values of the clinical parameters were considerably low, in contrast with their high specificity. It means that false–negative diagnoses were made more frequently than false-positive diagnosis[7]. It was in accordance with the study carried out by Yatani et.al[15]. Thus results obtained from these studies indicate that it is challenging to predict disc derangement based on clinical symptoms alone. In other words, not all joints commonly present characteristic clinical signs and symptoms of disc derangement[2,7,8,16].

The most common clinical sign in this study group was tenderness in the pre-auricular region (18 out of 28 joints, i.e., 64%), the cause being unclear. Okeson et al. [10] reported that disc displacement of TMJ is the crucial cause of facial and TMJ pain. Based on these observations, pain/tenderness in the preauricular region could be associated with alteration of retrodiscal tissue[17].

A study carried out by Kobs G et al. [9], concluded that although clicking is a predictor of anterior disc displacement with reduction, it was not present in his entire study population. In the present study, joint noise was found in 16 out of 28 joints (57%), thus indicating that TMJ clicking might occur as a consequence

Posted on 31 Jan 2024 | The copyright holder is the author/funder. All rights reserved. No reuse without permission. | https://doi.org/10.22541/au.170666087.71627683/v1 | This is a preprint and has not been peer-reviewed. Data may be preliminary.

of frictional incompatibility between the disc and the eminence when the posterior band of the disc moves anteriorly or posteriorly beyond the apex of the articular eminence. Other causes may be a deviation in the condylar form (remodeling), adhesion, or muscular incordination[18-22].

Muscle tenderness and limited mouth opening were found in Thirty-six percent in the present study. Deflection/deviation was found in 9 joints out of 28 joints (Thirty-two percent) and was the least among all the clinical symptoms[7].

In anticipation of osseous changes in the long-standing internal derangement of TMJ and to rule out other TMJ organic pathologies, the authors could have chosen the various radiographic and imaging modalities to determine the status of the disc. However, none of the modalities (conventional radiograph, specialized radiograph, and CT- axial and coronal view) could substantiate and locate the disc position[23,24,25].

The predictive value of the clinical diagnosis of ADDWR was 0.65 in a study by Barclay et al. [2]. The present study showed a 7 non-symptomatic joint with ADDWR on MRI. 2 joints clinically diagnosed ADDWR showed anterior disc displacement without reduction with MRI. 1 joint clinically diagnosed as anterior disc displacement without reduction did reduce on opening. 1 joint clinically diagnosed as anterior disc displacement without reduction appeared normal on MRI. Whereas 1 joint clinically diagnosed as anterior disc displacement without reduction could not be interpreted in MRI, 3 joints clinically diagnosed as MRI correctly diagnosed ADDWR, and 4 joints clinically diagnosed as NDD was confirmed by MRI[2, 19, 20, 21, 22].

There was a low agreement (33% to 70%) between clinical diagnosis and MRI diagnosis in symptomatic & asymptomatic joints[2, 6, 7-9]. The present study showed only 36% (4/11) of the asymptomatic joints had a normal disc position, detected by MRI. The prevalence of disc displacement in asymptomatic subjects is between 16% and 33%[2].

A previous study has shown that contralateral non-symptomatic joints in subjects with internal derangement in the other TMJ frequently have disc displacement[10, 14]; the present study findings also correlate with this study (7/11 ADDWR).

In accordance with the available literature, posterior disc displacement is exceptionally uncommon, and it was not observed in the present study[12]. Superior disc position is commonly used to refer to normal disc positioning in the sagittal oblique closed mouth view. The method used to judge disc position in this study was the closed mouth sagittal view assessment of the posterior band's position relative to the top of condyle as a superior disc position. It was considered normal if the posterior band of the disc is at position[17].

In the current study, the medial displacement proportion was more significant than lateral displacement (4 joints were medial; 2 joints lateral). These findings are in accordance with the existing literature[18,] which suggests that medial displacement occurs more frequently than lateral displacement and can be attributed to the force of muscles attached to the disc. It has been speculated that one reason for medial disc displacement is muscle spasm of the superior belly of the lateral pterygoid muscle[3].

Most clinical studies on anteroposterior arthrography and sagittal & coronal MRI have shown that the displacement's medial component is more frequent than the lateral component. The percentage of medial displacement was more significant in anterior disc displacement without reduction, and sideways displacement was also most frequent in anterior disc displacement without reduction[8].

The anterior disc displacement without reduction is the most common internal displacement depicted among TMJ derangement, but the present study showed that the NDD was most common in the study population diagnosed by MRI. (13 NDD; 11ADDWR and 2 anterior disc displacement without reduction). The limited protrusive movement was the most accurate clinical sign used for diagnosing anterior disc displacement without reduction[8]. However, this study did not support it as only 1 patient had limited mouth opening out of 2 patients diagnosed anterior disc displacement without reduction with MRI[18]. It could be due to contradicting views in clinical parameters based on protrusive movements/deflection and no single specific criteria in diagnosing specific TMJ disc displacement[19-25].

Posted on 31 Jan 2024 | The copyright holder is the author/funder. All rights reserved. No reuse without permission. | https://doi.org/10.22541/au.170666087.71627683/v1 | This is a preprint and has not been peer-reviewed. Data may be preliminary.

The overall diagnostic agreement of 88.25% (15/17) between specific RDC- diagnosis, and MRI in the current study is in accordance with various contemporary studies[9,13]. Several authors have investigated the reliability of the clinical diagnosis of ID using MRI as a 'gold standard'. The reported percent agreement ranged from 59% to 90%. A positive RDC examination is predictive for internal derangement but not reliable with regard to the type of disc displacement. The clinical examination is of limited value in determining the TMJ disc's true position and its functional movement. When accurate information about the TMJ disc position is clinically essential, MRI should be performed; the clinical examination alone cannot provide sufficient information[2,7,9,16, 18-20].

The combinations of TMJ radiographs are useful only in long-standing pathology, leading to visible changes in the osseous structures. However, these are still relevant in ruling out and eliminating osseous pathology for a confirmed diagnosis of soft tissue pathology of TMJ.

Based on the results of this study, the main strength is that the RDC/TMD criteria are not alone sufficient for the diagnosis of the internal derangement, and perhaps, it should be supported by the MRI to reach a confirmatory diagnosis so that a comprehensive approach can be initiated towards the management of the internal derangement of the TMJ by the clinicians. However, this study's major drawback was a small sample size before reaching a definitive conclusion. A further study examining a group of volunteers with or without a history of TMD and using the same diagnostic criteria as set by RDC/TMD, MRI with larger sample size, multi-center trials needs to be conducted.

Conclusion:

The results of this study suggest that RDC/TMD criteria for internal derangement alone are not sufficient, and it may be supplemented by the use of MRI so that a proper treatment protocol can be generated for the patient. However, it needs to validate through multi-center trials before coming to a definitive conclusion.

Abbreviations: NDD: Normal Disc Displacement; ADDWR: Anterior disc displacement with reduction; ADDWOR: Anterior disc displacement without reduction.

Declarations:

Ethics approval and consent to participate:

All procedures performed in studies involving human participants were in accordance with the ethical standards of the institutional and/or national research committee of the The First

Affiliated Hospital of Hainan Medical University, First Affiliated Hospital of Naval Military

Medical University, and Chengdu First People's Hospital. And comply with the 1964

Helsinki Declaration and its later amendments or comparable ethical standards. The written informed consent was taken from all the patients.

Consent to publish: Not Applicable

Availability of data and materials: The datasets used and/or analyzed during the current study available from the corresponding author on reasonable request.

Competing interests: The authors declare that they have no competing interests

Author's Contribution: LF has designed the concept; ZY Data acquisition; SC drafted the manuscript; JW and SR Final proof reading and editing.

Conflict of interest: The authors declare that they have no conflict of interest.

Funding: No Funding received.

Informed consent: It was obtained from all individual participants included in the study.

ACKNOWLEDGEMENTS: Not Applicable

Posted on 31 Jan 2024 | The copyright holder is the author/funder. All rights reserved. No reuse without permission. | https://doi.org/10.22541/au.170666087.71627683/v1 | This is a preprint and has not been peer-reviewed. Data may be preliminary.

Posted on 31 Jan 2024 | The copyright holder is the author/funder. All rights reserved. No reuse without permission. | https://doi.org/10.22541/au.170666087.71627683/v1 | This is a preprint and has not been peer-reviewed. Data may be preliminary.

REFERENCES:

1. McNeill C. History and evolution of TMD concepts. Oral Surg Oral Med Oral Pathol Oral Radiol Endod. 1997 Jan;83(1):51-60
2. Barclay P, Hollender LG, Maravilla KR, Truelove EL. Comparison of clinical and magnetic resonance imaging diagnosis in patients with disk displacement in the temporomandibular joint. Oral Surg Oral Med Oral Pathol Oral Radiol Endod. 1999 Jul;88(1):37-43
3. Sener S, Akgänlü F. MRI characteristics of anterior disc displacement with and without reduction. Dentomaxillofac Radiol. 2004 Jul;33(4):245-52
4. Brooks SL, Brand JW, Gibbs SJ, Hollender L, Lurie AG, Omnell KA et al. Imaging of the temporomandibular joint: a position paper of the American Academy of Oral and Maxillofacial Radiology. Oral Surg Oral Med Oral Pathol Oral Radiol Endod. 1997 May;83(5):609-18
5. Orsini MG, Kuboki T, Terada S, Matsuka Y, Yamashita A, Clark GT. Diagnostic value of 4 criteria to interpret temporomandibular joint normal disk position on magnetic resonance images. Oral Surg Oral Med Oral Pathol Oral Radiol Endod. 1998 Oct;86(4):489-97
6. Larheim TA. Current trends in temporomandibular joint imaging. Oral Surg Oral Med Oral Pathol Oral Radiol Endod. 1995 Nov;80(5):555-76
7. DelBalso AM. An approach to the diagnostic imaging of jaw lesions, dental implants, and the temporomandibular joint. Radiol Clin North Am. 1998 Sep;36(5):855-90
8. Foucart JM, Carpentier P, Pajoni D, Marguelles-Bonnet R, Pharaboz C. MR of 732 TMJs: anterior, rotational, partial and sideways disc displacements. Eur J Radiol. 1998 Aug;28(1):86-94
9. Kobs G, Bernhardt O, Kocher T, Meyer G. Critical assessment of temporomandibular joint clicking in diagnosing anterior disc displacement. Stomatologija. 2005;7(1):28-30
10. Orofacial Pain: Guidelines for Assessment, Diagnosis, and Management (1996). Jeffrey P. Okeson (Ed.). Publisher: Quintessence Publishing Co., Inc., Chicago, USA.
11. Dworkin SF, LeResche L. Research diagnostic criteria for temporomandibular disorders: review, criteria, examinations and specifications, critique. J Craniomandib Disord. 1992 Fall;6(4):301-55
12. Tasaki MM, Westesson PL, Isberg AM, Ren YF, Tallents RH. Classification and prevalence of temporomandibular joint disk displacement in patients and symptom-free volunteers. Am J Orthod Dentofacial Orthop. 1996 Mar;109(3):249-62.
13. Milano V, Designate A, Bellino R, Garofalo T. Magnetic resonance imaging of temporomandibular disorders: classification, prevalence and interpretation of disc displacement and deformation. Dentomaxillofac Radiol. 2000 Nov;29(6):352-61
14. Litvak H, Malament KA. Prosthodontic management of temporomandibular disorders and orofacial pain. J Prosthet Dent. 1993 Jan;69(1):77-84
15. Yatani H, Suzuki K, Kuboki T, Matsuka Y, Maekawa K, Yamashita A. The validity of clinical examination for diagnosing anterior disk displacement without reduction. Oral Surg Oral Med Oral Pathol Oral Radiol Endod. 1998 Jun;85(6):654-60
16. Takatsuka S, Yoshida K, Ueki K, Marukawa K, Nakagawa K, Yamamoto E. Disc and condyle translation in patients with temporomandibular disorder. Oral Surg Oral Med Oral Pathol Oral Radiol Endod. 2005 May;99(5):614-21.
17. Chiarini RA, Jacq JJ, Meriot P, Roux C. Temporomandibular joint: a methodology of magnetic resonance imaging 3-D reconstruction. Oral Surg Oral Med Oral Pathol Oral Radiol Endod. 2004 Jun;97(6):756-61
18. Arayasantiparb R, Tsuchimochi M. Quantification of disc displacement in internal derangement of the temporomandibular joint using magnetic resonance imaging. Odontology. 2010 Feb;98(1):73-81.
19. Park JW, Song HH, Roh HS, Kim YK, Lee JY. Correlation between clinical diagnosis based on RDC/TMD and MRI findings of TMJ internal derangement. Int J Oral Maxillofac Surg. 2012 Jan;41(1):103-8.
20. Larheim TA, Abrahamsson AK, Kristensen M, Arvidsson LZ. Temporomandibular joint diagnostics using CBCT. Dentomaxillofac Radiol. 2015;44(1):20140235.
21. Al-Saleh MA, Alsufyani NA, Lagravere M, Nebbe B, Lai H, Jaremko JL, Major PW. MRI alone versus

MRI-CBCT registered images to evaluate temporomandibular joint internal derangement. Oral Surg Oral Med Oral Pathol Oral Radiol. 2016 Nov;122(5):638-645.
22. Al-Saleh MA, Alsufyani NA, Saltaji H, Jaremko JL, Major PW. MRI and CBCT image registration of temporomandibular joint: a systematic review. J Otolaryngol Head Neck Surg. 2016 May 10;45(1):30.
23. Mohammed A Q Al-Saleh , Noura Alsufyani et.al. Usefulness of MRI-CBCT image registration in the evaluation of temporomandibular joint internal derangement by novice examiners. Oral Surg Oral Med Oral Pathol Oral Radiol 2017 Feb;123(2):249-256.
24. Stein S, Hellak A, Popović N, Toll D, Schauseil M, Braun A. Internal derangement in the temporomandibular joint of juveniles with clinical signs of TMD : MRI-assessed association with skeletal and dental classes. J Orofac Orthop. 2017 Jan;78(1):32-40.

FIGURE LEGENDS:

Figure 1: Depicts No Disc Displacement (NDD)

Figure 2: Illustrates Anterior Disc Displacement with Reduction (ADDWR) and Anterior Disc Displacement without Reduction (ADDWOR).

Figure 3: Shows Medial Disc Displacement (MDD)

Posted on 31 Jan 2024 | The copyright holder is the author/funder. All rights reserved. No reuse without permission. | https://doi.org/10.22541/au.170666087.71627683/v1 | This is a preprint and has not been peer-reviewed. Data may be preliminary.

Figure 1 NDD (No Disc Displacement):

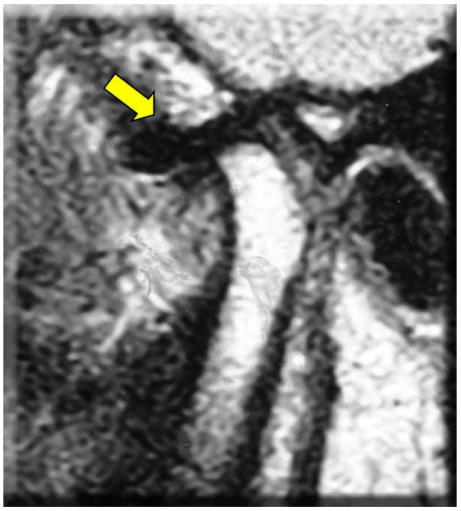

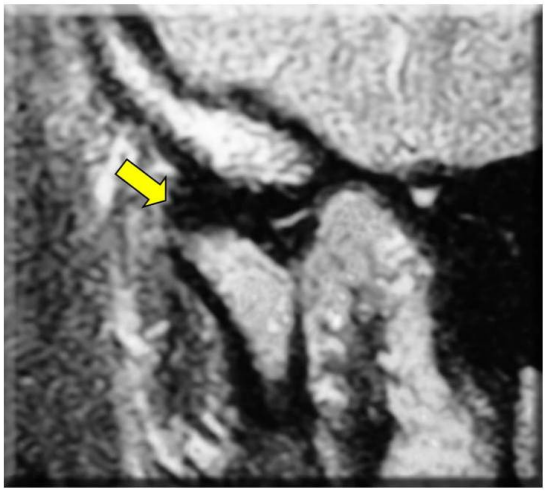

Posted on 31 Jan 2024 | The copyright holder is the author/funder. All rights reserved. No reuse without permission. | https://doi.org/10.22541/au.170666087.71627683/v1 | This is a preprint and has not been peer-reviewed. Data may be preliminary.

Figure 2: ADDWR and ADDWOR

Fig 2a MRI Sagittal section in Closed mouth (Right TMJ) **ADDWR**

Fig 2b RI Sagittal section in open mouth (Right TMJ) **ADDWR**

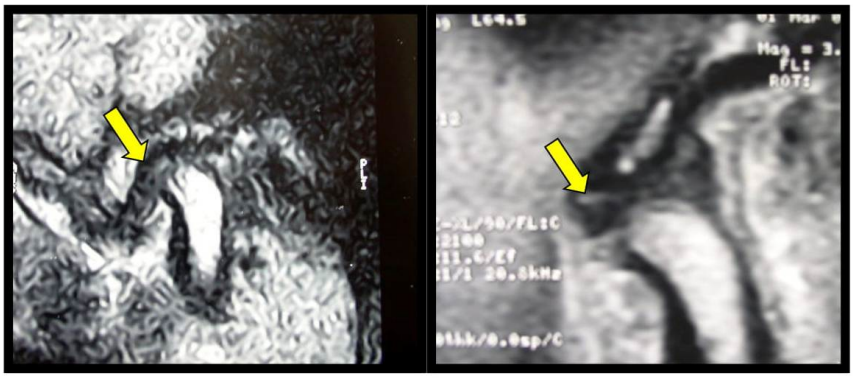

Fig 2c MRI Sagittal section in Closed mouth (Left TMJ) **ADDWOR**

Fig 2d MRI Sagittal section in open mouth (Left TMJ) **ADDWOR**

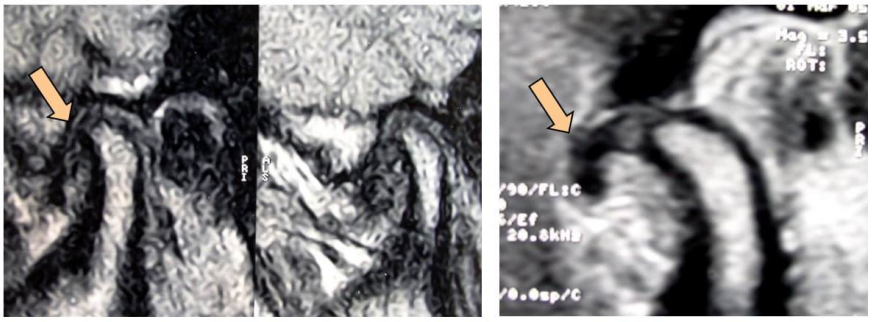

Posted on 31 Jan 2024 | The copyright holder is the author/funder. All rights reserved. No reuse without permission. | https://doi.org/10.22541/au.170666087.71627683/v1 | This is a preprint and has not been peer-reviewed. Data may be preliminary.

Figure 3: MDD (Medial Disc Displacement)

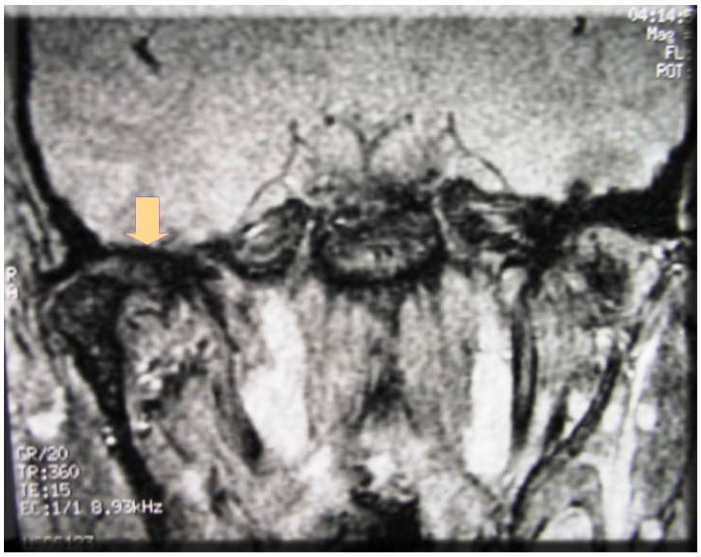

Hosted file

`Tables for OMR.docx` available at https://authorea.com/users/730281/articles/710090-diagnostic-properties-of-rdc-tmd-criteria-for-tmj-internal-derangement-versus-mri-gold-standard

Posted on 31 Jan 2024 | The copyright holder is the author/funder. All rights reserved. No reuse without permission. | https://doi.org/10.22541/au.170666087.71627683/v1 | This is a preprint and has not been peer-reviewed. Data may be preliminary.