

Redo aortic valve surgery in a case of dextrocardia with situs inversus totalis

Fabrício Dinato¹, Carlos Brandão², Pablo Pomerantzeff³, and Fabio Jatene⁴

¹University of São Paulo

²University of Sao Paulo Heart Institute

³University of Sao Paulo

⁴Heart Institute (InCor), University of São Paulo Medical School

March 07, 2024

Abstract

Dextrocardia is a rare congenital cardiac anomaly where the base-apex axis of the heart is directed to the right side. It may be associated with situs solitus, situs inversus, or situs ambiguous. Here we report a case of a patient with dextrocardia and situs inversus totalis, who had severe aortic bioprosthetic valve degeneration needing a redo aortic valve replacement. Computed tomography scan played a crucial role for a proper preoperative anatomical evaluation and surgical planning. Regarding our operative strategy, the main surgeon stood on the left side of the patient to perform most surgical steps. This surgical management played an important role for the good result in this challenging scenario.

Redo aortic valve surgery in a case of dextrocardia with situs inversus totalis

Fabrício José Dinato MD; Carlos Manuel de Almeida Brandão MD, PhD; Pablo Maria Alberto Pomerantzeff MD, PhD; Fabio Biscegli Jatene MD, PhD

Institution:

Division of Cardiovascular Surgery, Heart Institute, University of São Paulo Medical School, São Paulo, Brazil

Running Title: Redo valve surgery in dextrocardia

Correspondence: Fabrício José Dinato MD, Heart Institute, University of São Paulo Medical School, Av. Dr. Enéas de Carvalho Aguiar, 44-Pinheiros, São Paulo, Brazil. CEP 05403-000

Email: fabricao.dinato@incor.usp.br

Conflict of interest: None.

Funding: None.

Ethical Statement: Informed consent was given by the patient.

Data availability statement: Further supporting data is available from the authors on request.

Abstract

Dextrocardia is a rare congenital cardiac anomaly where the base-apex axis of the heart is directed to the right side. It may be associated with situs solitus, situs inversus, or situs ambiguous. Here we report a case of a patient with dextrocardia and situs inversus totalis, who had severe aortic bioprosthetic valve

degeneration needing a redo aortic valve replacement. Computed tomography scan played a crucial role for a proper preoperative anatomical evaluation and surgical planning. Regarding our operative strategy, the main surgeon stood on the left side of the patient to perform most surgical steps. This surgical management played an important role for the good result in this technically challenging scenario.

Keywords

Dextrocardia. Situs inversus. Reoperation. Aortic Valve.

Introduction

Dextrocardia is a cardiac abnormality in which the main cardiac axis is directed to the right and caudally. It may be associated with situs solitus, situs inversus, or situs ambiguous. Dextrocardia with situs inversus totalis means the heart and all other visceral organs are the mirror image of normal position. The incidence of dextrocardia with situs inversus totalis is 1/10,000 to 50,000 births [1].

The surgical management of such cases require a good operative planning involving the surgical team arrangement to overcome the technical challenges and achieve an optimal outcome.

Here we report the case of a patient with dextrocardia and situs inversus totalis, who had severe aortic bioprosthetic valve degeneration needing a redo aortic valve replacement.

Case report

A 67-year-old woman presented to the emergency room with progressive dyspnea on exertion for 5 months with worsening of symptoms in the last 3 days, with the onset of orthopnea, paroxysmal nocturnal dyspnea and lower limb edema. She had a history of dextrocardia with situs inversus totalis and aortic valve replacement surgery, ten years previously. Her vital parameters were normal, with bibasal crackling sounds in the lungs and a grade 4 sisto-diastolic murmur in the right paraesternal area at the 2nd intercostal space.

The chest radiography showed a right-sided cardiac shadow with mild cardiomegaly and signs of pulmonary congestion (Figure 1A). Transthoracic ecocardiography revealed dextrocardia, situs inversus, aortic bioprosthetic valve dysfunction due to severe regurgitation and moderate stenosis (mean pressure gradient of 39 mmHg), and a left ventricular ejection fraction of 55%. Computed tomography (CT) demonstrated situs inversus totalis with dextrocardia and no structures identified to be adherent to the sternum (Figure 1B). After completing preoperative assessment and planning, an urgent surgery was indicated.

Surgery was carried out via a median resternotomy. Femoral vessels were exposed in case urgent use of cardiopulmonary bypass became necessary. After sternal reentry, the adhesions between the posterior table and the mediastinal structures were easily divided and pleural spaces were opened bilaterally. Subsequently, dissection of the heart and great vessels was performed without any injury (Figure 2).

The cardiopulmonary bypass (CPB) was established by cannulating the ascending aorta, the superior vena cava, and the inferior vena cava. After aortic cannulation, our operative strategy was to change the position of the main surgeon to the left side of the patient to cannulate both cavas and to perform further surgical steps. Moderate hypothermia was applied. The aorta was cross-clamped, aortotomy was done, and then direct ostial cold blood cardioplegic solution was delivered. The aortic bioprosthesis was found to be calcified and it was carefully removed using an annular preserving technique. A bioprosthesis was implanted using interrupted 2-0 polyester mattress sutures (Figure 3). Interestingly, the direction of taking sutures also changed (forehand bites became backhand and vice versa). The aorta was closed and de-airing was carried. The patient was weaned from CPB and came off in sinus rhythm. The postoperative recovery was uneventful.

Discussion

Dextrocardia is a rare congenital cardiac anomaly where the base-apex axis of the heart is directed to the right side. The atrial situs can be situs solitus, situs inversus, or situs ambiguous of which situs inversus (mirror image dextrocardia) is more common (40%). If all the visceral organs also get mirrored, then it is

called dextrocardia with situs inversus totalis. In dextrocardia with situs inversus, around 10% of the cases are associated with other congenital cardiac anomalies [2].

Our patient had a typical case of dextrocardia with situs inversus totalis (all visceral organs were mirror images of the normal) and presented an aortic biological prosthesis dysfunction requiring a redo aortic valve replacement. The anatomy of the patient is almost challenging in the case with dextrocardia and decision for the surgeon where to stand during surgery is crucial.

Some approaches have been described about patients with dextrocardia with situs inversus totalis for valve replacement but still redo cardiac surgery is rare. Halder et al [3] reported a case of aortic and mitral valve replacement in a patient with dextrocardia and situs inversus totalis in which they stood on the left side of the patient. Sahin and colleagues [4] described a transeptal approach for mitral valve replacement. Saad et al [5] addressed the position of the surgeon in dextrocardia and situs inversus. Similar to our case, Altarabsheh et al [6] reported a left side approach for aortic valve replacement in a patient with dextrocardia and situs inversus, proposing this operative setting for patients with such unusual anatomy.

A meticulous pre-operative surgical plan involving the whole team was very important for a smooth intra-operative course and a favourable outcome. Regarding intraoperative strategy about the position of surgeon for cannulation and aortic valve approach, we performed bicaval cannulation, prosthesis removing and new aortic bioprosthesis insertion with the main surgeon standing on the left side of the patient. We believed this surgical team arrangement added much to the technical ease for the surgery, since the anatomy was opposite to what our minds are used to.

In addition, since it was a redo cardiac surgery with an uncommon anatomy, CT scan played a crucial role for a proper preoperative anatomical evaluation of all the great vessels, the heart, possible associated anomalies and to plan our cannulation strategy. Also, CT scan permitted to minimize risk of re-entry injury because it could identify potential adherence of mediastinal structures to the undersurface of the sternum.

Our patient had dextrocardia with situs inversus totalis requiring a redo aortic valve surgery. CT scan had an important role for operative planning, which contributed substantially for the good result of the operation. Our left side approach provided excellent exposure for redo aortic valve replacement in this scenario.

References

1. Garg N, Agarwal BL, Modi N, Radhakrishnan S, Sinha N. Dextrocardia: an analysis of cardiac structures in 125 patients. *Int J Cardiol.* 2003;88:143-55.
2. Evans WN, Acherman RJ, Collazos JC, Castillo WJ, Rollins RC, et al. Dextrocardia: Practical clinical points and comments on terminology. *Pediatr Cardiol.* 2010;31:1-6.
3. Halder S, Hossain Z, Swarnendu D, Chakrabarty U, Dasbaksi K, Khurram M, et al. Double valve replacement in a case of dextrocardia and situs inversus totalis. *Indian J Thorac Cardiovasc Surg.* 2018;34:506-509.
4. Sahin MA, Guler A, Kaya E. Mitral valve replacement in a patient with situs inversus and dextrocardia. *Thorac Cardiovasc Surg.* 2011;59:305-6.
5. Saad RA, Badr A, Goodwin AT, Dunning J. Should you stand on the left or the right of a patient with dextrocardia who needs coronary surgery? *Interact Cardiovasc Thorac Surg.* 2009;9:698-702.
6. Altarabsheh SE, Al-Azzam FM, Deo SV, Almomane AF, Al-Omari A, Alma'ayeh SM, et al. Left side approach for aortic valve replacement in patient with dextrocardia and situs inversus totalis. *J Saudi Heart Assoc.* 2017;29: 297-299.

Figures

Figure 1:

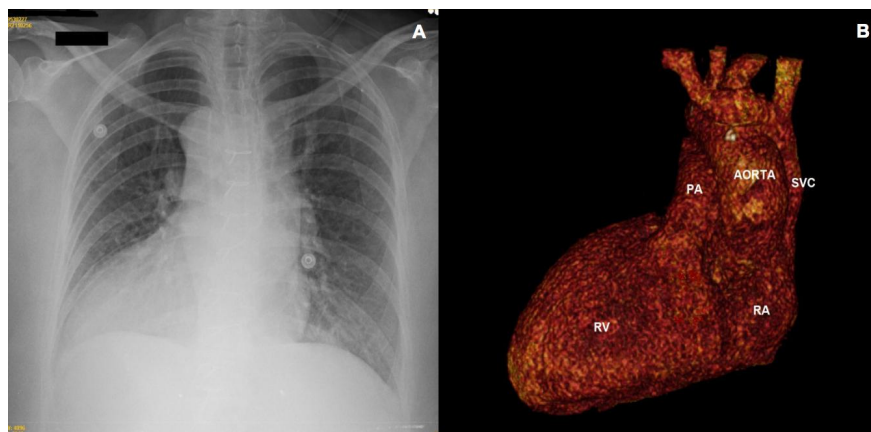


Figure 2:

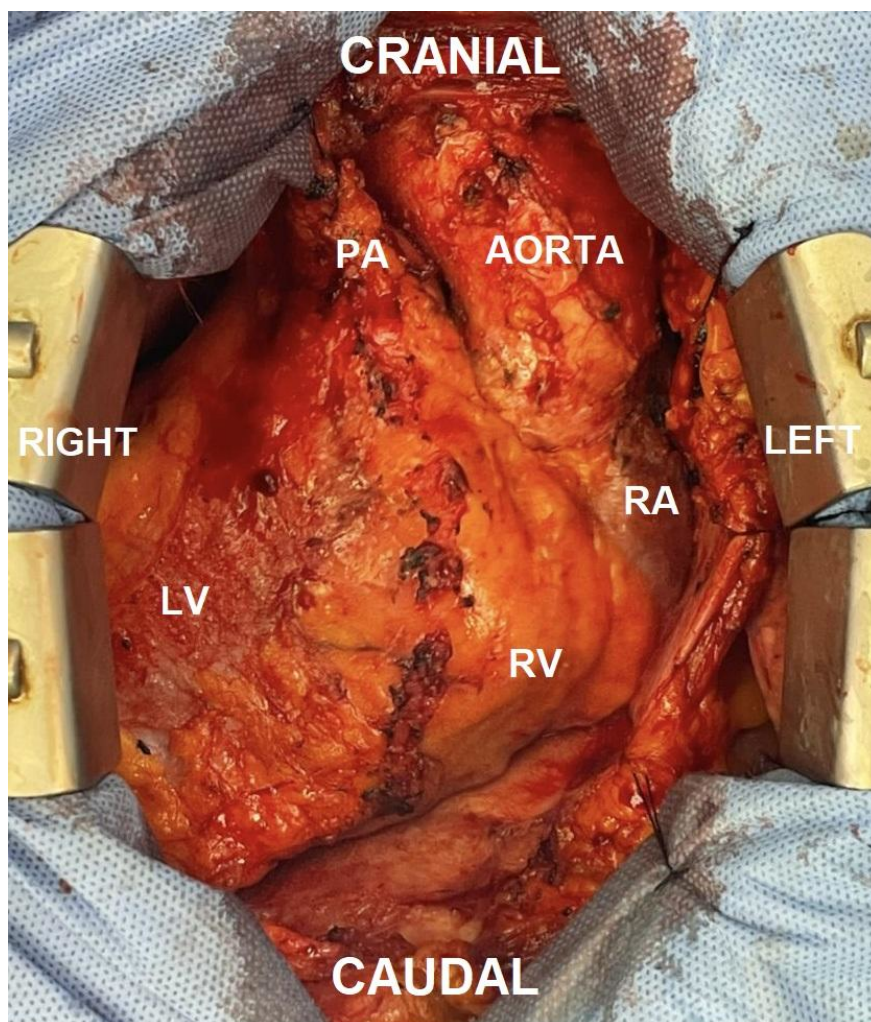


Figure 3:

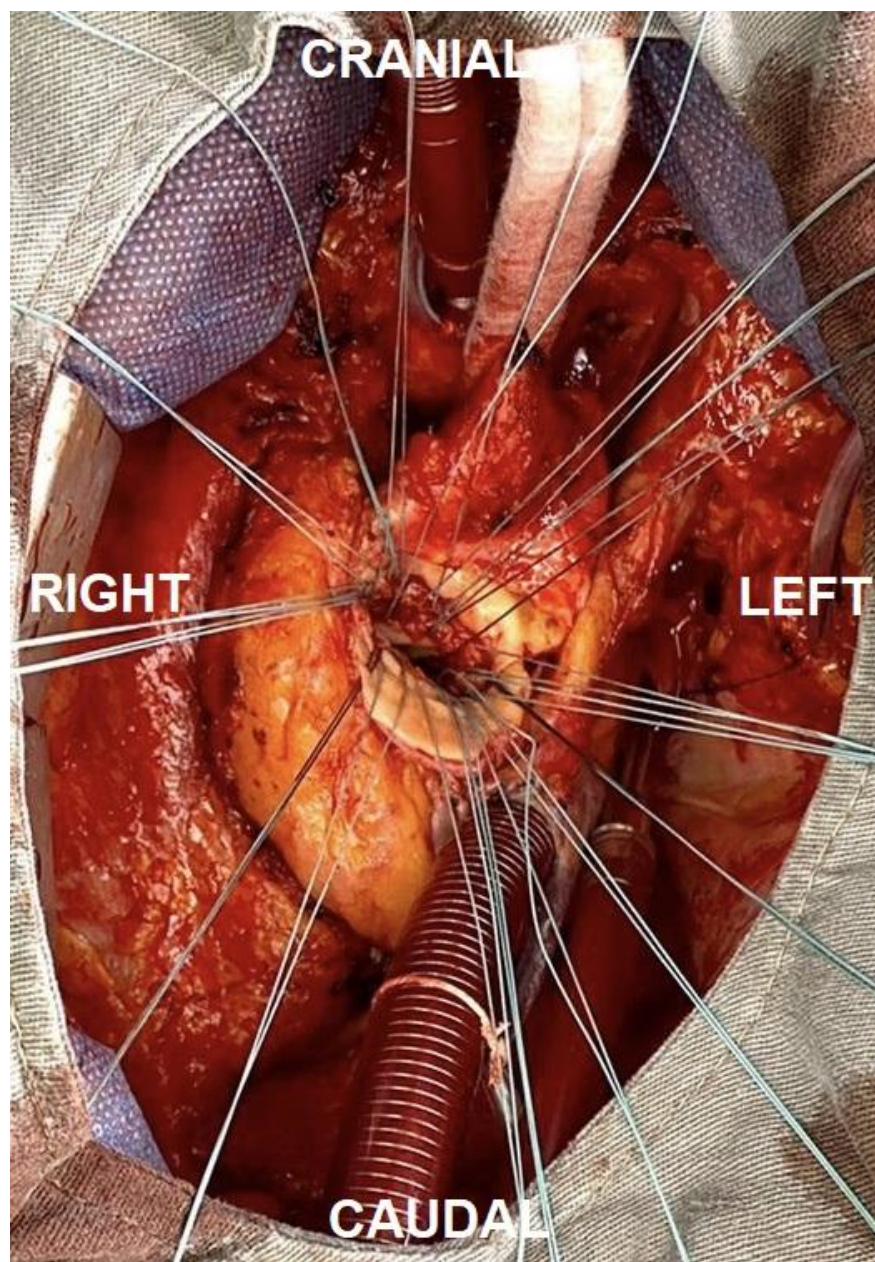


Figure Legends:

Figure 1. A: Chest radiography demonstrating dextrocardia with dilated heart due to left ventricle enlargement and signs of pulmonary congestion. B: 3D reconstruction of computed tomography of the chest demonstrating the heart and great vessels exactly a mirror of norm. PA: pulmonary artery; RA: right atrium; RV: right ventricle, SVC: superior vena cava.

Figure 2. Intra-operative view of the patient showing the aorta and the right atrium (RA) on the left side, and the pulmonary artery (PA) and the left ventricle (LV) on the right side. RV: right ventricle.

Figure 3. Intra-operative view after prosthesis removal and placing interrupted polyester mattress sutures.

