

A rare form of congenital erythrocytosis due to SLC30A10 biallelic variants: differential diagnosis and recommendation for biochemical and genetic screening.

Rosalinda Giannini¹, EMANUELE AGOLINI², Giuseppe Palumbo², Antonio Novelli², Giacomo Garone², Melissa Grasso², Giovanna Colafati², Marta Matraxia², Eleonora Piccirilli², and Giulia Ceglie²

¹Università degli Studi di Roma Tor Vergata Dipartimento di Biomedicina e Prevenzione

²Ospedale Pediatrico Bambino Gesù

August 30, 2023

Abstract

There are several known forms of congenital erythrocytosis. Secondary forms are usually associated with increased erythropoietin levels and recognize heterogeneous genetic basis. Despite the use of NGS technologies, more than 50% of congenital erythrocytosis cases are still classified as idiopathic. Identifying the underlying molecular cause appears to be crucial when a therapeutic option is available, especially if erythrocytosis is combined with progressive dysfunction of other organs. Herein, we describe the case of a patient with a rare form of congenital erythrocytosis due to bi-allelic mutations of SLC30A10 gene, responsible for a rare disease known as hypermanganesemia with dystonia 1 (HMNDYT1).

Introduction

Erythrocytosis is defined as an increase in the red blood cell (RBC) count, hemoglobin (Hb) concentration and hematocrit (Hct) above the reference range adjusted to age, sex and living altitude (1). Besides idiopathic forms, erythrocytosis can be classified as either primary or secondary, based on pathophysiology and circulating erythropoietin (EPO) levels. Primary erythrocytosis exhibits an EPO-independent mechanism, while secondary forms are identified as EPO-dependent being a consequence of erythroid progenitors' responsiveness to increased EPO secretion. Primary and secondary forms can be either congenital - usually linked to a genetic defect - or acquired (Table 1). The best-known form of primary congenital erythrocytosis is due to heterozygous pathogenic variants in *EPOR* gene, which encodes for EPO receptor (2); more recently *SH2B3* germline mutations have been implied as another possible cause (3). No definite treatment guidelines have been published for primary congenital erythrocytosis and while most individuals require no regular treatment, some undergo phlebotomy to treat hyper-viscosity symptoms (4). Genetic causes of secondary congenital erythrocytosis are certainly wider, including both autosomal dominant and recessive forms. Here, we report on the case of a 3-year-old boy, presenting with erythrocytosis and growth retardation, harboring a bi-allelic variant in *SLC30A10* gene which is responsible for a rare recessive syndromic form of erythrocytosis known as hypermanganesemia with dystonia 1 (HMNDYT1).

Results

Case Description The patient is the only child of consanguineous parents native from Bangladesh, born at 36 +6 weeks of gestation. Weight at birth was 1.740 kg (Z-score -2.81) (5), length was 41 cm (Z-score -2.19), occipital-frontal circumference was 30 cm (Z-score -2.95). Developmental motor milestones were reached according to age (sitting position at 7 months, autonomous walking at 14 months), while first words were

pronounced around 18 months of age and language development was delayed. In addition, from the age of two, parents noticed poor interaction with peers and poor non-verbal communication. The patient was initially evaluated at the age of 12 months for poor weight gain in the context of late preterm birth. Routinary blood tests showed a slight increase of RBC (5.300.000/mm³, upper reference limit [URL] 5.000.000/mm³) and AST activity (53 U/L, URL 40 U/L). Screening for celiac disease, TSH and IGF1 were normal, while total IgE levels were increased (299 kU/L, URL 40 kU/L) with positivity for specific IgE against milk, alpha and beta lactoglobulin, for which a two-month cow's milk protein-free diet was started. On follow-up exams, a trend towards progressive increase of erythrocytosis was evident, and the patient was admitted to the hospital for further investigations. On admission, cell blood count showed: RBC 7.850.000/mm³, Hct 65.2%, Hb 19.8 g/dl, platelets 170.000/mm³ and reticulocyte 144.000/ μ L (2.2 %). Hb electrophoresis and serum EPO levels were normal (6.63 mU/mL, normal range: 4.3-29 mU/mL). Polycythemia Vera and other forms of myeloproliferative neoplasms were excluded through molecular testing for *JAK2* -V617F mutation and *BCR/ABL* fusion gene on peripheral blood. Echocardiogram and complete abdomen ultrasound showed no anomalies. After initial treatment, the patient underwent phlebotomies in aliquots of 6 ml/Kg at rate of approximately 1 procedure per month. To investigate different congenital forms of polycythemia a clinical exome sequencing containing more than 8500 genes was performed. Data analysis did not detect any variant in primary erythrocytosis gene,s but revealed the homozygous novel missense variant NM_018713.3:c.392T>G (p.Leu131Arg) in *SLC30A10* gene (ZINC TRANSPORTER 10; ZNT10), associated with HMNDYT1 and initially classified as a variant of uncertain significance according to the ACMG criteria (see supplementary materials).

To assess our patient's variant pathogenicity, serum Mn levels were tested, confirming a condition of hypermanganesemia (7.00 μ g/L; URL 3.00 μ g/L). Brain MRI showed bilateral and symmetrical T1 signal hyperintensity of globi pallidi, subthalamic nuclei, substantia nigra, pontine tegmentum, superior cerebellar peduncles, dentate nuclei and anterior pituitary gland, highly suggestive of manganese accumulation (Fig. 1). Brain MRI findings along with erythrocytosis and hypermanganesemia confirmed the diagnosis of HMNDYT1, and the c.392T>G (p.Leu131Arg) variant in *SLC30A10* was re-classified as likely pathogenic. Hepatic ultrasound was normal, and no extrapyramidal sign was detected at neurological examination. A standardized neuropsychological evaluation showed a non-verbal IQ within normal range (IQ 87, Leiter 3 scale), with a poor adaptive functioning (Vineland-II Adaptive Behavior composite score 47, below the first centile for age). At 3 years of age, language is limited to two words, pointing gesture, pretend and symbolic play are absent, and eye contact is poorly modulated.

The patient was treated with iron supplementation and chelation therapy with CaNa₂ EDTA (20mg/kg). Manganese levels were assessed before and after chelation therapy, showing a significative reduction from 19,80 μ g/L to 7,41 μ g/L (Supplemental Figure S1). Complete blood count showed a reduction of erythrocytosis indexes (RBC 5.840.000/mm³, Hct 45.9%, Hb 14.3 g/dl). After three months from treatment start, our patient has not developed extrapyramidal signs.

Discussion

HMNDYT1 is a form of hypermanganesemia presenting with parkinsonism, dystonia, polycythemia and chronic liver disease, associated with biallelic pathogenic mutations in *SLC30A10* gene. *SLC30A10* encodes a manganese (Mn) transporter, expressed in different tissues and responsible for Mn efflux from the Cytosol. Alteration of manganese metabolism leads to hypermanganesemia and to the accumulation of manganese in the liver, muscles and brain, particularly in the basal ganglia (6). HMNDYT1 usually presents with neurologic symptoms that can appear from early childhood to adulthood. In the childhood-onset form, neurologic involvement becomes apparent between two and fifteen years of age primarily as extrapyramidal signs including four-limbs dystonia, leading to a characteristic high-stepping gait ("cock-walk gait"), dysarthria, bradykinesia, and rigidity (7). In a few patients, onset can occur in adulthood as akinetic-rigid parkinsonism unresponsive to L-dopa treatment (6). Another complication due to severely defective manganese excretion is chronic liver disease, which shows a wide phenotypic variability, ranging from elevated liver enzymes and mild hepatomegaly to hepatic cirrhosis (7). Polycythemia is a constant feature of HMNDYT1, likely due to

manganese-induced EPO production and usually preceding neurological dysfunction (8; 7).

In our case, clinical presentation consisted in polycythemia with iron deficiency and normal serum EPO levels, combined with failure to thrive and slightly increased serum AST activity (without other signs of liver dysfunction), in absence of movement disorders.

Even though there is still no standardized treatment protocol for HMNDYT1, the primary treatment for this condition is chelation along with iron therapy. Studies showed that progression of manganese accumulation can be prevented through chelation therapy with CaNa2 EDTA, leading to an improvement of neurological symptoms (9). Acting as a competitive inhibitor, iron supplementation has proven to be helpful in reducing blood manganese concentration and normalizing erythrocyte count (7). In our case, chelation therapy was useful in managing polycythemia, and no extrapyramidal sign emerged so far.

In conclusion, rare forms of congenital erythrocytosis for which a specific treatment option is available could benefit greatly from an early diagnosis. In young patients presenting with idiopathic isolated erythrocytosis, congenital forms should always be ruled out through specific biochemical and genetic testing (10). The use of NGS technology to diagnose rare forms of genetic determined erythrocytosis has proven to be extremely useful in selected patients, identifying new genes and improving the diagnostic rate up to 45.6% (11). Considering a cost-effective approach, an enlarged multigene panel for congenital erythrocytosis should include genes causing both primary and secondary forms of erythrocytosis, to improve their diagnostic yield and disease-modifying potential.

Acknowledgements

We thank Professor Franco Locatelli for critically revising the manuscript.

This work was supported also by the Italian Ministry of Health with Current Research funds.

References

1. Cakmak HM, Kartal O, Kocaaga A, Bildirici Y. Diagnosis and genetic analysis of polycythemia in children and a novel EPAS1 gene mutation. *PEDN* . 2022 Nov;63(6):613-617. doi:10.1016/j.pedneo.2022.06.006.
2. Bento C. Genetic basis of congenital erythrocytosis. *Int J Lab Hematol* . 2018 May;40(S1):62-67.
3. Oh ST, Zahn JM, Jones CD, Zhang B, Loh ML, Kantarjian H, et al. Identification of Novel *LNK* Mutations In Patients with Chronic Myeloproliferative Neoplasms and Related Disorders. *Blood* . 2010 Nov;116(21):315. doi:10.1182/blood.V116.21.315.315.
4. McMullin MF. Congenital erythrocytosis. *Int J Lab Hematol*. 2016 May;38(1):59-65. doi: 10.1111/ijlh.12506.
5. Fenton TR, Kim JH. A systematic review and meta-analysis to revise the Fenton growth chart for preterm infants. *BMC Pediatr*. 2013 Apr;13(59). doi:10.1186/1471-2431-13-59.
6. Quadri M, Federico A, Zhao T, Breedveld GJ, Battisti C, Delnooz C, et al. Mutations in *SLC30A10* Cause Parkinsonism and Dystonia with Hypermanganesemia, Polycythemia, and Chronic Liver Disease. *Am J Hum Genet*. 2012 Mar;90(3):467-477. doi:10.1016/j.ajhg.2012.01.017.
7. Tuschl K, Clayton PT, Gospe SM Jr, Gulab S, Ibrahim S, Singhi P, et al. Syndrome of Hepatic Cirrhosis, Dystonia, Polycythemia, and Hypermanganesemia Caused by Mutations in *SLC30A10* , a Manganese Transporter in Man. *Am J Hum Genet*. 2012 Mar; 90(3):457-466.
8. Hebert BL, Bunn HF. Regulation of the Erythropoietin Gene. *Blood* . 1999 Sep;94(6):1864-1877. doi:10.1182/blood.V94.6.1864.
9. Di Toro Mammarella, L, Mignarri A, Battisti C, Monti L, Bonifati V, Rasi F. Two-year follow-up after chelating therapy in a patient with adult-onset parkinsonism and hypermanganesemia due to *SLC30A10* mutations. *J Neurol*. 2014 Nov;261:227-228. doi:10.1007/s00415-013-7187-5.
10. Jeevasankar, M., Agarwal, R., Chawla, D., Vinod, K. P., Ashok, K. D. Polycythemia in the newborn. *Indian J Pediatr*. 2008 May;75:68-72. doi: 10.1007/s12098-008-0010-0

11. Tomc J, Debeljak N. Molecular Pathways Involved in the Development of Congenital Erythrocytosis. *Genes* . 2021 Jul;12(8):1150. doi:10.3390/genes12081150.

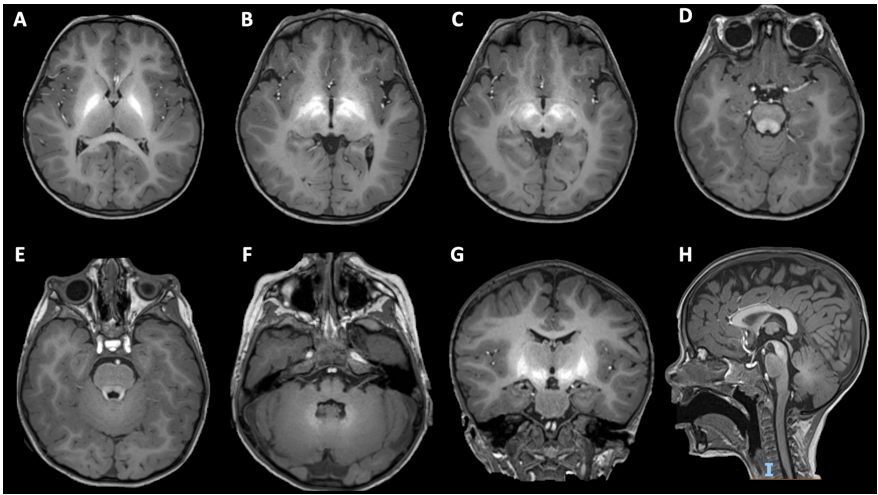
Legends for figures and Tables

Figure 1. Bilateral and symmetrical hyperintensity in T1-weighted imaging involving globi pallidi (A, B, G), subthalamic nuclei (B, G), substantia nigra (C, H), pontine tegmentum (D), superior cerebellar peduncles (E), dentate nuclei (F), and pituitary gland (E, G), reflecting manganese accumulation.

Table 1. Primary and Secondary forms of erythrocytosis, congenital or acquired

Supplemental Figure 1. Trend of hematocrit and manganesemia before and after chelation therapy. Orange and blue lines represent the values of hematocrit and manganesemia respectively.

The dark blue horizontal arrow corresponds to given iron supplementation, while vertical green arrows represent phlebotomy treatment (6 ml/Kg) and vertical red arrows indicate the first and second administration of chelation therapy with CaNa2 EDTA (20mg/kg). Even though our patient underwent only two chelation cycles with CaNa2 EDTA, consistently with reference literature, oral iron supplementation and chelation therapy combined appear to stabilize and decrease Mn blood levels, even if still above the upper reference limit. As reported by Gulab and colleagues in 2017 (doi: 10.1055/s-0037-1608778) and Jagadish and colleagues in 2021 (doi: 10.1016/j.ebr.2021.100505), it is not unusual for Mn levels to remain mildly to moderately elevated even after chelation therapy.



Hosted file

TABLE 1.docx available at <https://authorea.com/users/658024/articles/662536-a-rare-form-of-congenital-erythrocytosis-due-to-slc30a10-biallelic-variants-differential-diagnosis-and-recommendation-for-biochemical-and-genetic-screening>