

Hepatocellular carcinoma with gastric adenocarcinoma treated with atezolizumab and bevacizumab

Takayoshi Suga¹, Yuko Kimura¹, Kensuke Furuya¹, and Hiroko Sato¹

¹Shibukawa Iryo Center

June 20, 2023

Abstract

Hepatocellular carcinoma concurrent with gastric adenocarcinoma is a rare but possible case. In addition, selecting an effective treatment for two primary cancers is often difficult. In this report, we present the first case of hepatocellular carcinoma concurrent with gastric adenocarcinoma treated with atezolizumab and bevacizumab combination therapy.

Hepatocellular carcinoma with gastric adenocarcinoma treated with atezolizumab and bevacizumab

Takayoshi Suga,^{1,2*} Yuko Kimura,^{1,2} Kensuke Furuya,^{1,2} Hiroko Sato,^{1,2}

1 Department of Gastroenterology, Shibukawa Medical Center, National Hospital Organization, Shibukawa, Gunma, Japan.

2 Department of Gastroenterology and Hepatology, Gunma University Graduate School of Medicine, Maebashi, Gunma, Japan.

***Corresponding author** : Takayoshi Suga, M.D., Ph.D.,

Department of Gastroenterology, Shibukawa Medical Center, National Hospital Organization, 383 Shirai, Shibukawa, Gunma 377-0280, Japan.

Tel: +81-279-23-1010

Fax: +81-279-23-1011

E-mail: jamosuga@yahoo.co.jp

Conflict of interest : There are no conflicts of interest to declare.

Informed consent : Written informed consent was obtained from the patient to publish this report in accordance with the journal's patient consent policy.

Key words : Liver cancer; Gastric cancer; Double cancer

Word count for main text : 244 words

Case

A 58-year-old man was referred to our hospital for liver and gastric tumors. Abdominal contrast-enhanced computed tomography (CT) revealed low-density masses in the liver (Figure 1A, arrow) and stomach (Figure 1A, arrow head) with left supraclavicular lymph node metastasis. Upper gastrointestinal endoscopy revealed an ulcerous mass lesion in the gastric cardia (Figure 1B). The pathological diagnosis by liver biopsy

was hepatocellular carcinoma and by gastrointestinal endoscopic biopsy was adenocarcinoma, showing programmed death-ligand 1 (PD-L1)-positive and human epidermal growth factor receptor 2 (HER2)-negative findings. Systemic chemotherapy for hepatocellular carcinoma was selected because the hepatic tumor was huge and thought to contribute to the patient's prognosis more than advanced gastric cancer. The patient was treated with atezolizumab and bevacizumab combination therapy, the first line treatment for hepatocellular carcinoma (1). Eighteen months after treatment, CT showed partial response of hepatocellular carcinoma (Figure 1C, arrow) and gastric adenocarcinoma (Figure 1C, arrow head). No tumor growth was observed on gastrointestinal endoscopy (Figure 1D).

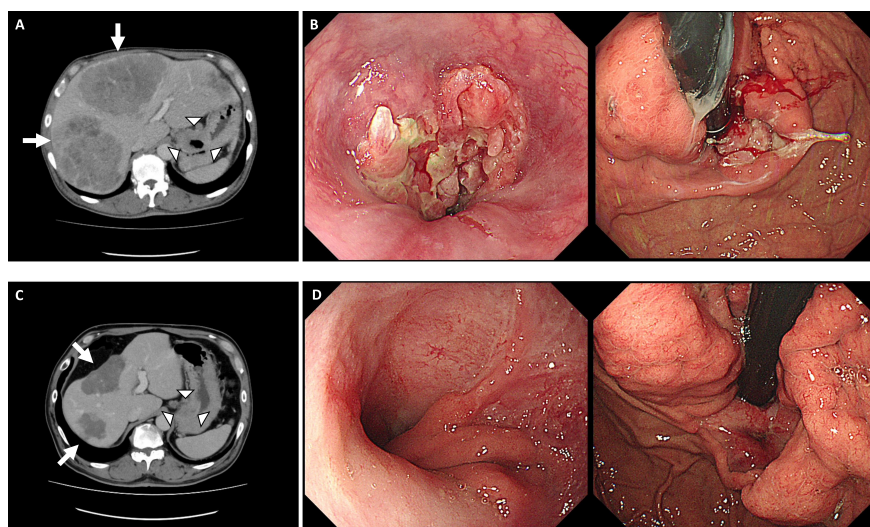
To our knowledge, this is the first report that atezolizumab and bevacizumab combination therapy was effective in a patient with two primary cancers, namely, hepatocellular carcinoma and gastric adenocarcinoma. However, whether anti-PD-L1 antibody atezolizumab had any effect on gastric cancer in this case is controversial, and bevacizumab has been reported to have some effects (2)(3)(4). Therefore, selecting an effective treatment for two primary cancers is often difficult. Atezolizumab and bevacizumab combination therapy might be one of the treatment options for hepatocellular carcinoma concurrent with gastric adenocarcinoma.

REFERENCES

1. Finn RS, Qin S, Ikeda M, et al. Atezolizumab plus Bevacizumab in Unresectable Hepatocellular Carcinoma. *N Engl J Med.* 2020;382(20):1894-1905.
2. Högnér A, Moehler M. Immunotherapy in Gastric Cancer. *Curr Oncol.* 2022;29(3):1559-1574.
3. Xie J, Fu L, Jin L. Immunotherapy of gastric cancer: Past, future perspective and challenges. *Pathol Res Pract.* 2021;218:153322.
4. Ohtsu A, Shah MA, Van Cutsem E, et al. Bevacizumab in combination with chemotherapy as first-line therapy in advanced gastric cancer: a randomized, double-blind, placebo-controlled phase III study. *J Clin Oncol.* 2011;29(30):3968-3976.

Figure legend

Figure 1. Computed tomography of hepatic and gastric masses before (A) and after (C) treatment. Endoscopy with gastric tumor before (B) and after (D) treatment.



Hosted file

Figure 1.pptx available at <https://authorea.com/users/402789/articles/650428-hepatocellular-carcinoma-with-gastric-adenocarcinoma-treated-with-atezolizumab-and-bevacizumab>