

Full title:A Coxsackievirus B1-infected neonatal rhesus macaques HFMD model and viral tissue tropism

* zhanlong¹, Duan suqin¹, Li yongjie¹, Zhang wei¹, Ming Zhang¹, * Li yanyan¹, Zhao yuan¹, Jin weihua¹, Liu quan¹, Li mingxue¹, Sun wenting¹, Chen lixiong¹, Xu hongjie¹, Tang jie¹, Hou jinghan¹, Deng zijun¹, Yang fengmei¹, and Shaohui Ma¹

¹Chinese Academy of Medical Sciences & Peking Union Medical College Institute of Medical Biology

May 30, 2023

Abstract

Coxsackie virus B1 (CVB1) is an enterovirus that presents as hand, foot and mouth disease (HFMD), which may cause long-term symptoms in some patients. However, CVB1 animal models, detoxification cycles, and long-term tissue tropism have not been systematically characterized. In this study, a CVB1 respiratory infection model was established in rhesus macaques, and clinical symptoms, viral load, and immune marker levels were observed in the acute phase (0-14 days) and long-term recovery phase (15-30 days). We also quantified the distribution, replication, and pathology of CVB1 during the long-term recovery period using 35 postmortem rhesus macaques tissue samples at 30 days post infection (d.p.i), thus revealing the long-term tissue tropism of the virus. The results showed that the respiratory tract of rhesus macaques was susceptible to CVB1 and showed HFMD symptoms, detoxification phenomena, changes in cytokine levels, and neutralizing antibodies. Autopsy viral load results were positive in heart, spleen, pancreas, pharyngeal flat, and olfactory bulb tissues, and HE staining revealed pathological damage to the liver, spleen, lung, pharyngeal flat, palatal flat, and tracheal epithelium. Viral antigens were present in visceral, immune, respiratory, and muscle tissues but not detected in intestinal and neural tissues. Brain tissue was dissected and showed viral meningitis-like changes, and CVB1 antigen expression was observed in occipital, pontine, cerebellar, and spinal cord tissues. This study first provides a basis for elucidating CVB1 pathogenesis in a nonhuman primate HFMD model and then confirms the CVB1 tissue tropism pattern after long-term infection.

Hosted file

A Coxsackievirus B1-infected neonatal rhesus macaques HFMD model and viral tissue tropism.docx available at <https://authorea.com/users/623567/articles/646253-full-title-a-coxsackievirus-b1-infected-neonatal-rhesus-macaques-hfmd-model-and-viral-tissue-tropism>

Figure 1

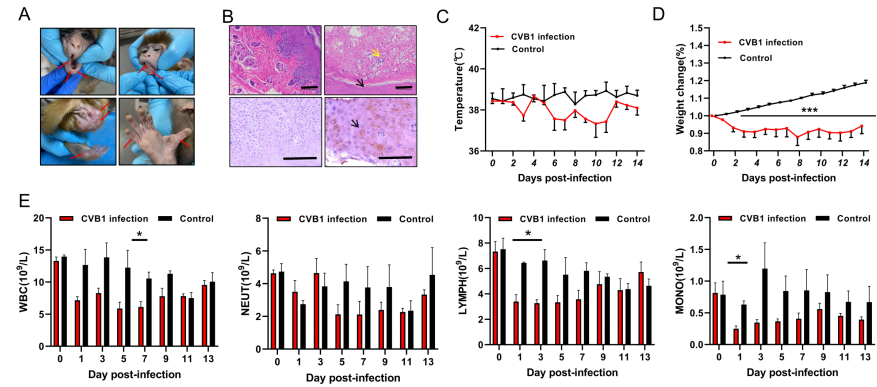


Figure 2

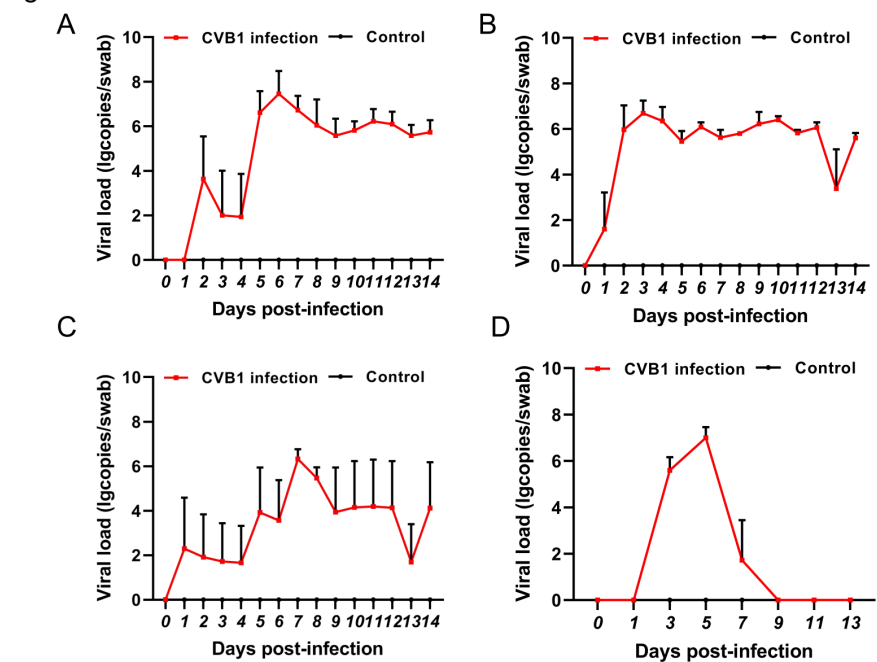


Figure 3

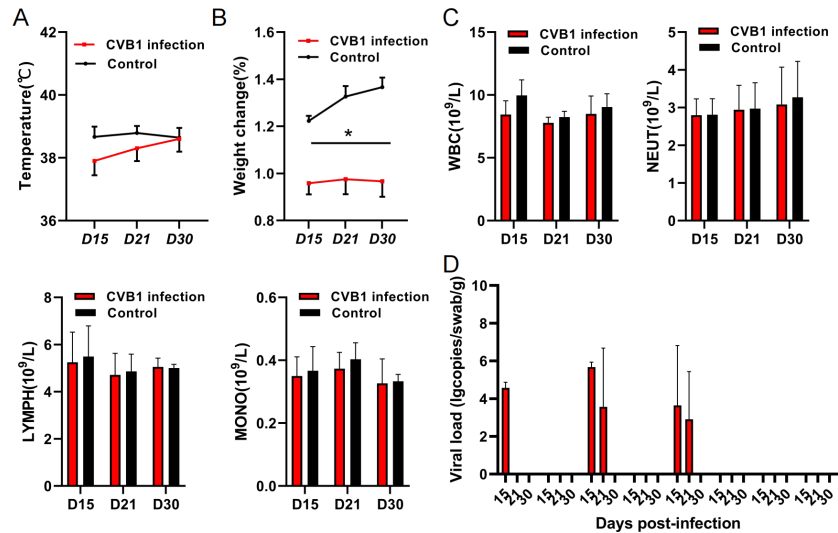


Figure 4

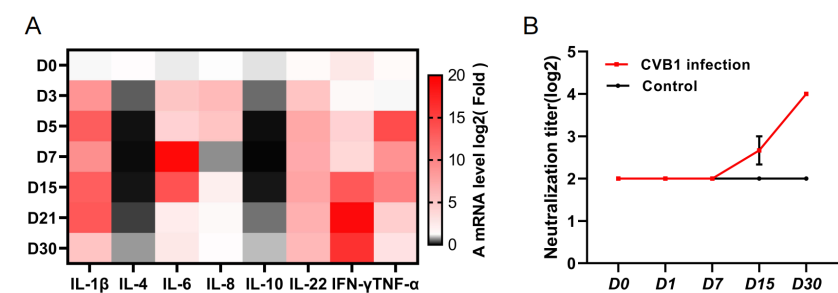


Figure 5

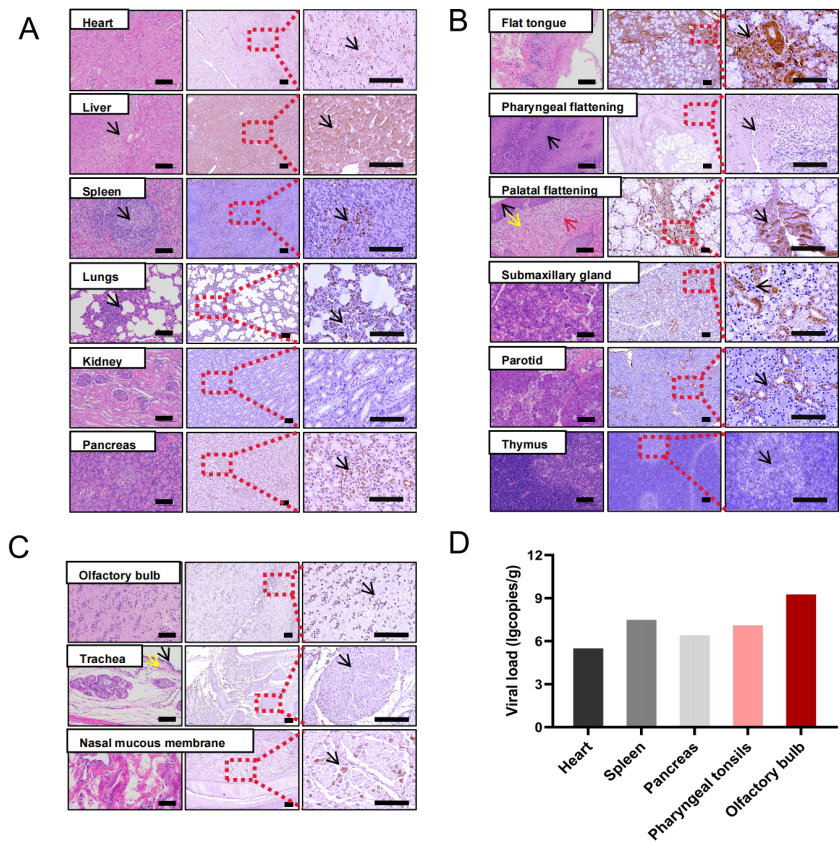


Figure 6

