

# Isolated mitral valve aneurysm in a 9-year old boy

Vehbi Dogan<sup>1</sup> and Kutay Sel<sup>2</sup>

<sup>1</sup>SBU Ankara Dr Sami Ulus Kadın Doğum Çocuk Sağlığı ve Hastalıkları Eğitim ve Araştırma Hastanesi

<sup>2</sup>Affiliation not available

March 18, 2024

# Isolated mitral valve aneurysm in a 9-year old boy

Vehbi Doğan<sup>1</sup>, Kutay Sel<sup>1</sup>

<sup>1</sup>Department of Pediatric Cardiology, Dr. Sami Ulus Children's Health and Diseases Training and Research Hospital, Ankara, Türkiye.

## ABSTRACT

**Background.** Isolated mitral valve aneurysm is rarely reported in children. In most cases it is associated with an underlying disease such as infective endocarditis. MVA can lead to severe complications that needs surgical intervention.

**Case.** In this report, we present a 9-year old asymptomatic male patient with anterior mitral valve aneurysm and rhythm disturbance diagnosed incidentally during pre-operative evaluation.

**Conclusions.** Being rare in children, isolated MVA should be kept in mind in the differential diagnosis of mass lesions seen on the atrial side of the mitral valve. A 24-hour electrocardiogram may define subtle rhythm disturbances in these patients.

**Key words:** mitral valve aneurysm, arrhythmia, children.

Mitral valve aneurysms (MVA) are localised saccular bulging on the mitral valve leaflets towards the atrium with systolic expansion and diastolic collapse.<sup>1</sup> Aortic valve infective endocarditis with aortic regurgitation is the leading cause in the literature.<sup>2</sup> Other associated etiologies have been reported such as; rheumatic diseases, iatrogenic diseases, connective tissue diseases (Marfan syndrome, Ehler-Danlos syndrome, osteogenesis imperfecta and pseudoxanthoma), severe aortic regurgitation and mitral valve prolapse.<sup>2-4</sup> Isolated mitral valve aneurysm excluding these etiologies is rarely reported in the literature.<sup>5,6</sup> In this report, a case of isolated MVA in an 9-year-old boy is presented with echocardiographic and ECG findings.

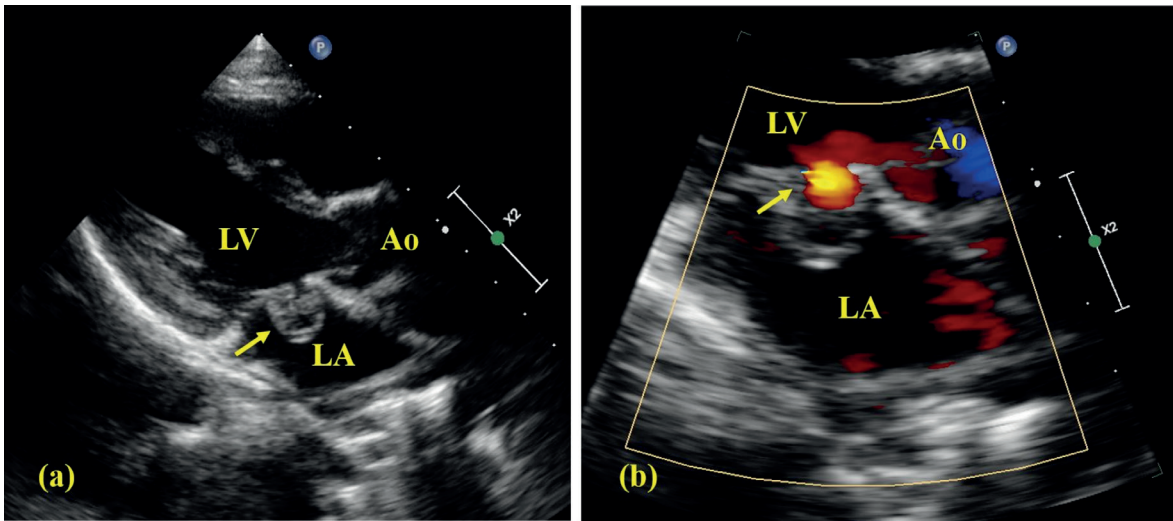
## Case report

A 9-year old boy consulted our clinic because of suspected arrhythmia during auscultation before general anesthesia for a dental procedure. The patient was asymptomatic and had no previous complaints suggestive of arrhythmia. His physical examination was normal except a grade 1/6 soft systolic murmur at left sternal border and possible extrasystole during oscultation. A 12-lead ECG was normal. Transthoracic echocardiography revealed a saccular aneurysm appearance on anterior mitral valve with a diameter of 15.4x12.7 mm and color flow was detected into the aneurysm (Fig. 1, Supplementary Materials 1 and 2). Doppler echocardiogram showed no regurgitation flow to left atrium. Subvalvular apparatus was normal. A 24-hour Holter ECG showed intermittent ectopic atrial rhythm, supraventricular extrasystole (2% of total heart beats) conducted with aberration in some and no tachycardia (Fig. 2). His laboratory examination was normal including blood culture and inflammatory markers. Due to the patient's uneventful past history, a normal physical examination except for a murmur, normal laboratory examination, absence of Duke criteria, aortic regurgitation and findings

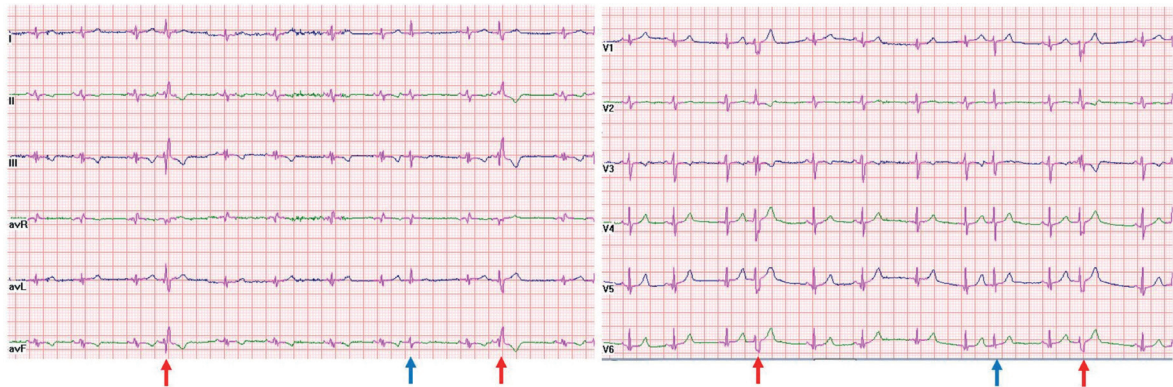✉ Vehbi Doğan  
vdogan86@yahoo.com

Received 19th Apr 2023, revised 23rd Jan 2024,  
accepted 24th Feb 2024.

This manuscript has been previously published as a preprint on the Authorea Preprint system.  
https://doi.org/10.22541/au.168152583.32127753/v1



**Fig. 1. (a).** Echocardiographic appearance of mitral valve aneurysm from long axis view; aneurysm on anterior leaflet (arrow). **(b)** Color flow into the aneurysm without regurgitation (arrow). Ao: aortic valve, LA: left atrium, LV: left ventricle.



**Fig. 2.** Supraventricular extrasystoles with (red arrow) and without (blue arrow) aberration detected during 24-hour ECG.

suggestive of connective tissue disease, a diagnosis of isolated mitral valve aneurysm (MVA) was considered in the patient. The patient was asymptomatic and we decided on close clinical follow-up without any medication. During the 10-month follow up period the patient had no complaints and no complications were observed. The patient was planned to be followed up with echocardiography every 6 months and annual 24-hour Holter ECG. Written informed consent was received from the parents of the patient.

## Discussion

Mitral valve aneurysms are rare findings, most commonly associated with infective endocarditis (IE).<sup>2</sup> Aortic valve infective endocarditis with aortic regurgitation is the leading cause in the literature. Pena et al.<sup>2</sup> evaluated 18 patients with MVA and found that 83% meet the Duke criteria for definite endocarditis. The associated diseases were mitral valve prolapse in 8, rheumatic in 6, bicuspid aortic valve in 3 and degenerative valve in 1 patient. This

study includes 2 patients under 18 years of age and rheumatic disease was the underlying pathology in both (one had endocarditis and one had aortic and mitral regurgitation). Two patients had myxomatous degeneration in the mitral leaflets with prolapse and no history of IE. In our patient, the aneurysmal lesion was on the anterior mitral leaflet without any clinical evidence of infective endocarditis or positive findings for other possible etiologies. The patient was accepted as isolated MVA after detailed evaluation. Isolated MVA is reported rarely. Nagaoka et al.<sup>6</sup> reported a 8-month old infant with severe mitral regurgitation due to perforated posterior leaflet MVA. They speculate the possible causes were congenital isolated mitral aneurysm that subsequently complicated with perforation or previous small mitral perforation inducing MVA formation secondary to a jet lesion. Mitral regurgitation or perforation were absent in our patient.

A 70 year old patient with perforated posterior leaflet aneurysm without concurrent IE, connective tissue (CT) disease or rheumatic disease was reported by Kim et al.<sup>5</sup> The patient had moderate aortic insufficiency, which was expected to affect the anterior valve more, but the aneurysm was located in the posterior valve without any evidence of an acute inflammatory process in histopathologic examination.

Its mechanism is unclear. In cases with endocarditis it is thought to be through spread of infection to mitral valve via different mechanisms.<sup>1,7</sup> For isolated lesions it is also speculated that a minor valve perforation progresses into severe regurgitation and complicating to aneurysm formation.<sup>6</sup> In our patient perforation and regurgitation were not present. As in our case, it is more common on the anterior mitral leaflet. Pena et al.<sup>2</sup> reported that 16 of the 18 patients had MVA on anterior leaflet. It can be explained by anatomical neighborhood with aortic valve.

Echocardiography is the primary diagnostic tool to detect these lesions, however it can be

misinterpreted as vegetation, mitral valve abscess, cystic atrial myxoma, blood cyst or mass.<sup>1,4,7</sup> Color flow demonstrates the direct communication between aneurysm and helps in distinguishing from these lesions.

Possible complications include perforation of the aneurysm leading to severe mitral regurgitation, thrombus formation, embolism and recurrent infection.<sup>1,2,5,6</sup> Pena et al.<sup>2</sup> reported that perforation and thrombus formation in 94% and 16% of the patients respectively. Rhythm disturbances like AV block, atrial fibrillation are reported in literature. The ECG was normal in our patient, however on 24-hour holter ECG, 2% of the total beats were supraventricular with intermittent ectopic atrial rhythm without any symptoms. As in our case small, uncomplicated or unperforated aneurysms may be managed conservatively, surgery is generally indicated in others.

In conclusion, being rare in children, isolated MVA should be kept in mind in the differential diagnosis of mass lesions seen on the atrial side of the mitral valve. A 24-hour electrocardiogram may define subtle rhythm disturbances in these patients.

### Supplementary Materials

Supplementary materials for this article are available online at <https://doi.org/10.24953/turkped.2023.314>

**Supplementary Material 1.** Echocardiogram videos, showing the apical four chamber and long axis views.

**Supplementary Material 2.** Echocardiogram videos, showing the modified long axis 2D and long axis color flow images of the aneurysm.

### Ethical approval

Written informed consent was obtained from parents of the patient.

### Author contribution

The authors confirm contribution to the paper as follows: study conception and design: VD, data collection and literature review: KS, draft manuscript preparation; VD. All authors reviewed the results and approved the final version of the manuscript.

### Source of funding

The authors declare the study received no funding.

### Conflict of interest

The authors declare that there is no conflict of interest.

### REFERENCES

1. Reid CL, Chandraratna AN, Harrison E, et al. Mitral valve aneurysm: clinical features, echocardiographic-pathologic correlations. *J Am Coll Cardiol* 1983; 2: 460-464. [https://doi.org/10.1016/s0735-1097\(83\)80272-1](https://doi.org/10.1016/s0735-1097(83)80272-1)
2. Pena JLB, Bomfim TO, Fortes PRL, Simão-Filho C, de Souza Andrade-Filho J. Mitral valve aneurysms: Clinical characteristics, echocardiographic abnormalities, and possible mechanisms of formation. *Echocardiography* 2017; 34: 986-991. <https://doi.org/10.1111/echo.13556>
3. Saxena A, Shrivastava S, Kumar MV. Mitral valve aneurysm without infective endocarditis. *Indian Heart J* 1995; 47: 501-502.
4. Gajjar TP, Desai NB. True aneurysm of anterior mitral leaflet-a rare entity. *J Thorac Cardiovasc Surg* 2012; 144: e93-e95. <https://doi.org/10.1016/j.jtcvs.2012.05.055>
5. Kim DJ, Cho KI, Jun HJ, et al. Perforated mitral valve aneurysm in the posterior leaflet without infective endocarditis. *J Cardiovasc Ultrasound* 2012; 20: 100-102. <https://doi.org/10.4250/jcu.2012.20.2.100>
6. Nagaoka K, Ibuki K, Miyahara Y. Perforated posterior mitral leaflet aneurysm in an 8-month-old infant. *Cardiol Young* 2021; 31: 153-154. <https://doi.org/10.1017/S1047951120003340>
7. Silbiger JJ. Review: Mitral valve aneurysms in infective endocarditis: mechanisms, clinical recognition, and treatment. *J Heart Valve Dis* 2009; 18: 476-480.