

Esophageal fistula involving the thoracic aorta is a rare event. Mycotic aneurysm may complicate this condition: A case report

Shokrollah Hafezeftekhari¹, Farzaneh Khoroushi¹, and Hossein Bozorgi¹

¹Mashhad University of Medical Sciences

April 12, 2023

Esophageal fistula involving the thoracic aorta is a rare event. Mycotic aneurysm may complicate this condition: A case report

Shokrollah Hafezeftekhari¹, Farzaneh Khoroushi¹, Hossein Bozorgi¹

¹Department of Radiology, Faculty of Medicine, Mashhad University of Medical Sciences, Mashhad, Iran

Correspondence: Hossein Bozorgi, Department of Radiology, Faculty of Medicine, Mashhad University of Medical Sciences, Mashhad, Iran

Email: Bozorgih4001@mums.ac.ir

Tel: 09906136895

Shokrollah Hafezeftekhari – MD – Radiology Resident

Affiliation: Department of Radiology, Faculty of Medicine, Mashhad University of Medical Sciences, Mashhad, Iran Email Address: Hafezesh4001@mums.ac.ir

Farzaneh Khoroushi – MD – Assistant Professor of Radiology

Affiliation: Department of Radiology, Faculty of Medicine, Mashhad University of Medical Sciences, Mashhad, Iran Email Address: KhoroushiF@mums.ac.ir

Hossein Bozorgi – MD – Radiology Resident

Affiliation: Department of Radiology, Faculty of Medicine, Mashhad University of Medical Sciences, Mashhad, Iran Email Address: Bozorgih4001@mums.ac.ir

Introduction

One of the most important causes of hospitalization is gastrointestinal bleeding. The most common causes of upper gastrointestinal bleeding include gastric ulcer, gastritis, esophageal varices and Mallory-Weiss syndrome. There are also less common causes that usually receive little attention in the emergency department of hospital, one of them is aortoesophageal fistula (AEF) (1). AEF is one of the rare causes of upper gastrointestinal bleeding that can be life-threatening. The mortality rate is 77% in appropriate treatment and 100% without treatment (2). AEF is divided into primary and secondary types. The primary type is caused by various causes such as thoracic aortic aneurysm, foreign body, esophageal cancers or radiotherapy. The secondary type is usually caused by complications of surgeries performed on the aorta or esophagus, and secondary to the implantation of surgical grafts (3). Clinical symptoms of AEF range from asymptomatic patients to very critical patients. Classic patients present with the triad of central chest pain, sentinel arterial bleeding, and evacuation after an asymptomatic period (Chiari Triad). Various methods have been introduced to diagnose AEF, which can be used based on the clinical condition and vital signs of the patient.

Dynamic CT scan may be a faster choice for patients who are stable after sentinel bleeding, however, patients with clinically unstable conditions should undergo immediate surgery (1). Various treatment methods have been proposed for the treatment of AEF, such as surgery and interventional radiology. Thoracic endovascular aortic repair (TEVAR) is a good option to stabilize the patient's condition and reduce mortality in the short term until the patient undergoes reconstructive surgery (4).

Our patient in this study suffered upper GI bleeding due to an AEF fistula developed following endoscopic procedures for the patient.

Case presentation

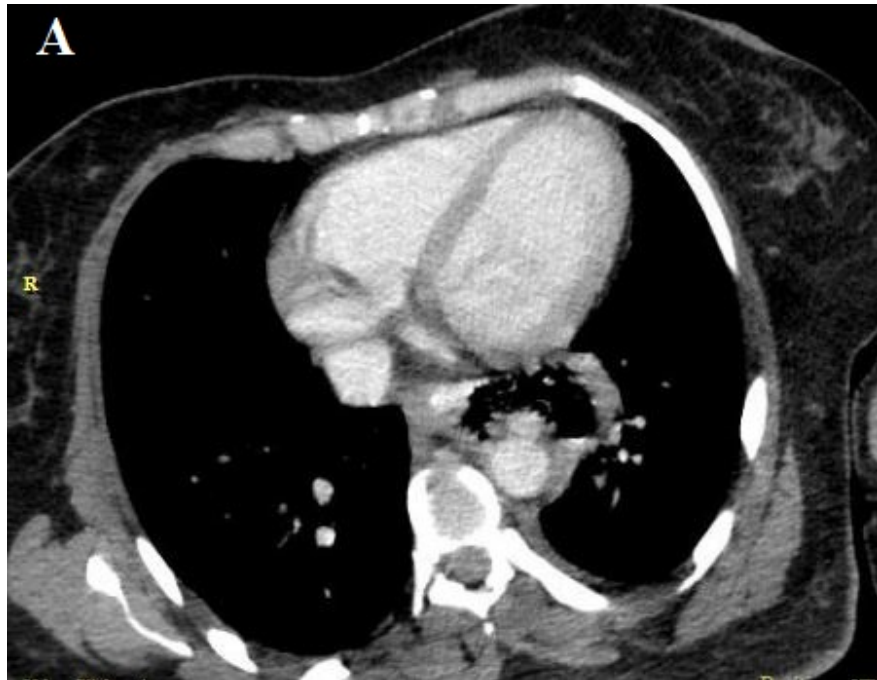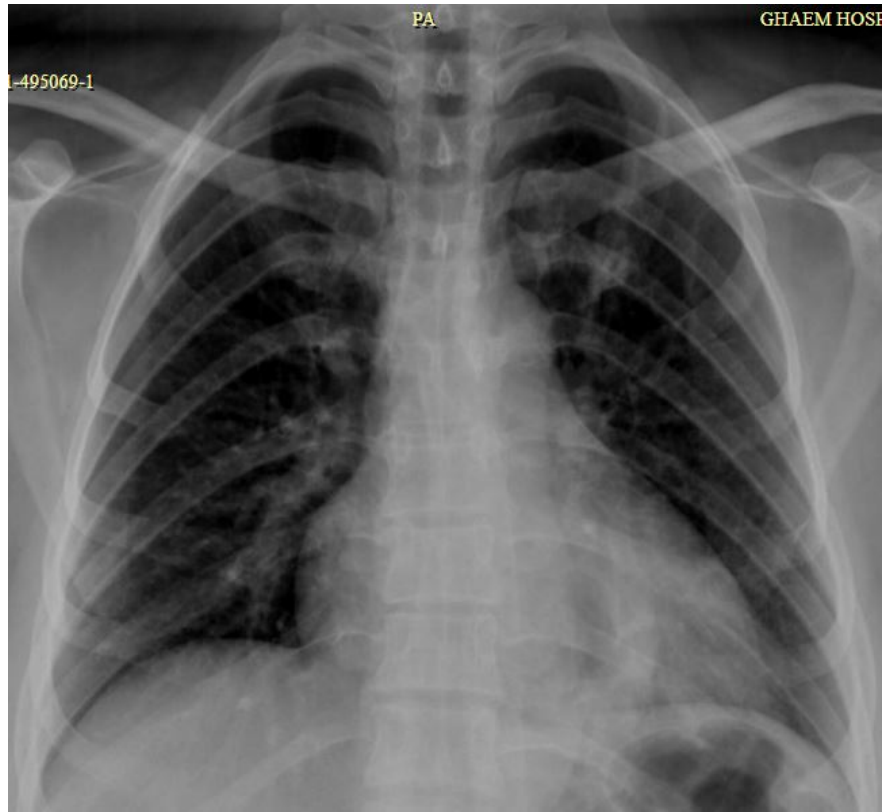
A 36-year-old Asian woman without any underlying disease and with a history of abdominoplasty surgery, came to the hospital with persistent nausea and vomiting for two weeks. After supportive treatments and performing upper GI endoscopy, a significant narrowing was seen in the distal esophagus caused by the esophageal ring, so that the scope did not pass through that narrowing. In the endoscopic evaluation of the esophagus, there was no evidence in favor of an obvious ulcer. Malignancy was ruled out after biopsy of esophageal stricture. Finally, the esophageal stricture was dilated by balloon through the scope. The patient was discharged with good general condition and regular medication.

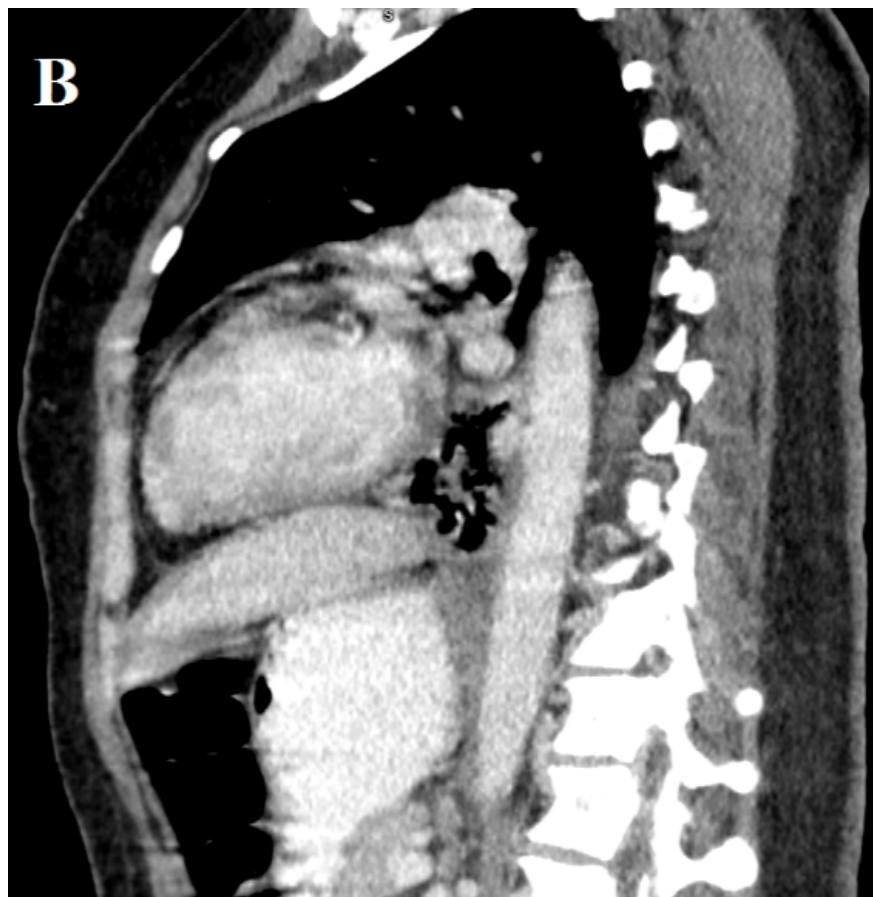
After ten months, the patient returned to the hospital again due to persistent nausea and vomiting and received supportive treatment. In endoscopy, which was performed due to the history of esophageal ring, esophagitis was seen in the esophageal mucosa, and the patient underwent re-dilatation by bougie.

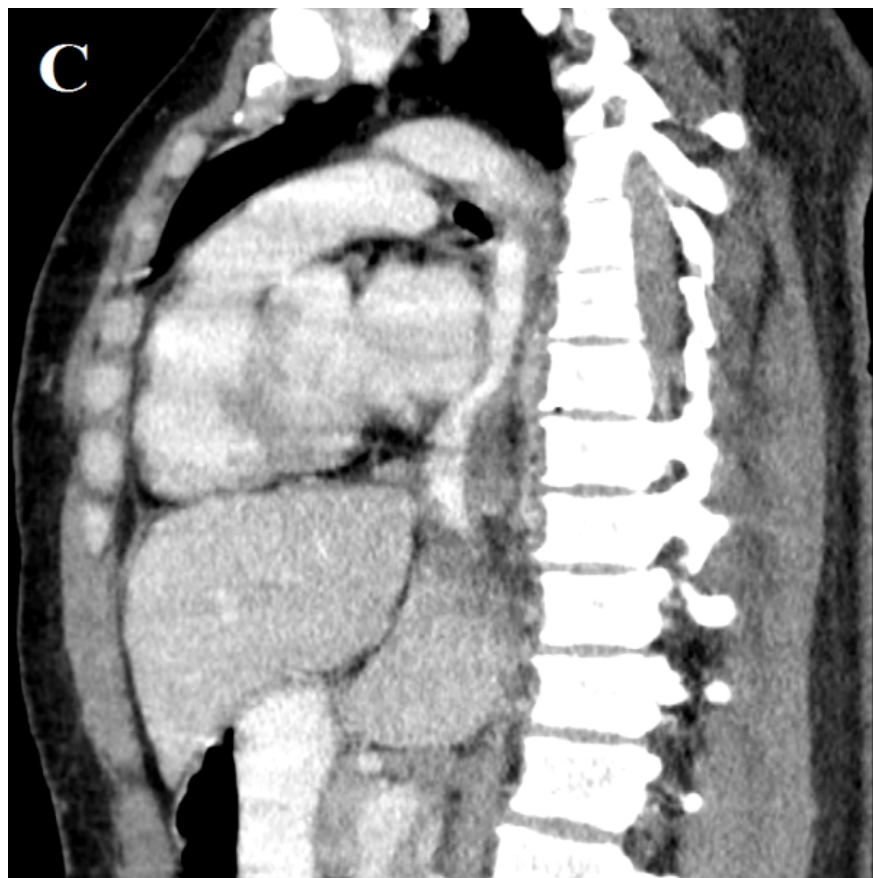
After the bouginage, due to chest pain with fever and leukocytosis, the patient was suspected of esophageal perforation and mediastinitis, and underwent chest X-ray and CT scan with IV and oral contrast. No pathological findings were seen in the patient's Chest X-ray (figure 1).

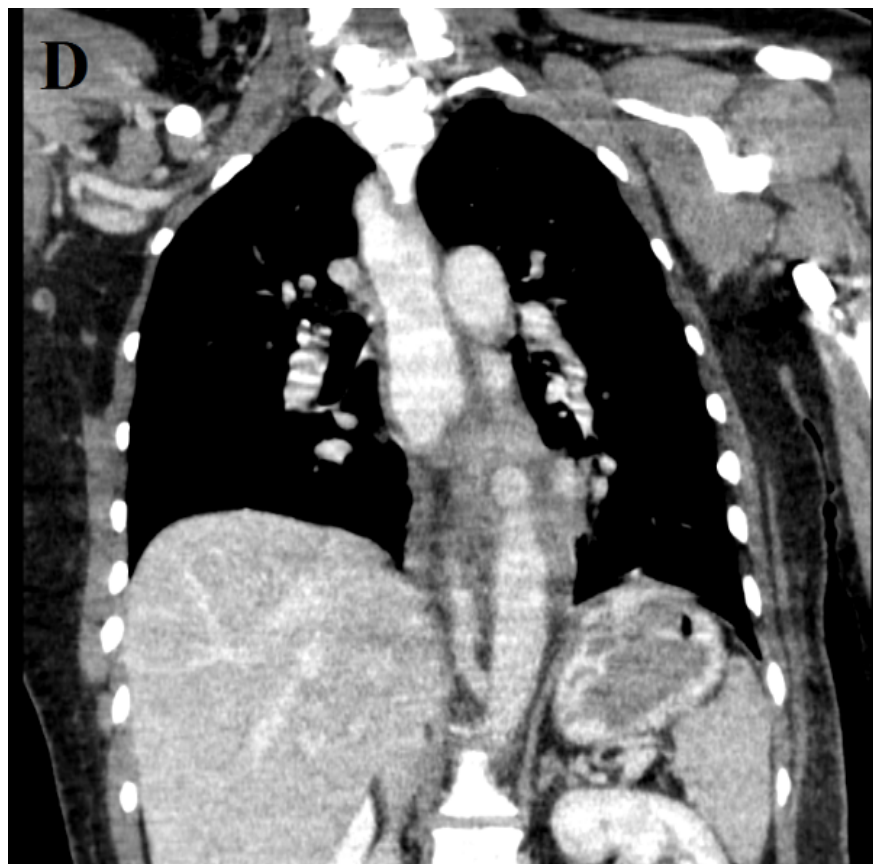
In the CT scan, an out-pouching with a diameter of 10 mm with gas densities and fat stranding around it was seen at the level of the T7-T8 vertebra, suggesting an aortic pseudoaneurysm, which probably suggests an aortoesophageal fistula and esophageal microperforations in that area. There was no evidence in favor of pneumomediastinum, pneumothorax and pneumoperitoneum. Also, there was no evidence in favor of obvious perforation in the esophagus (Figure 2).

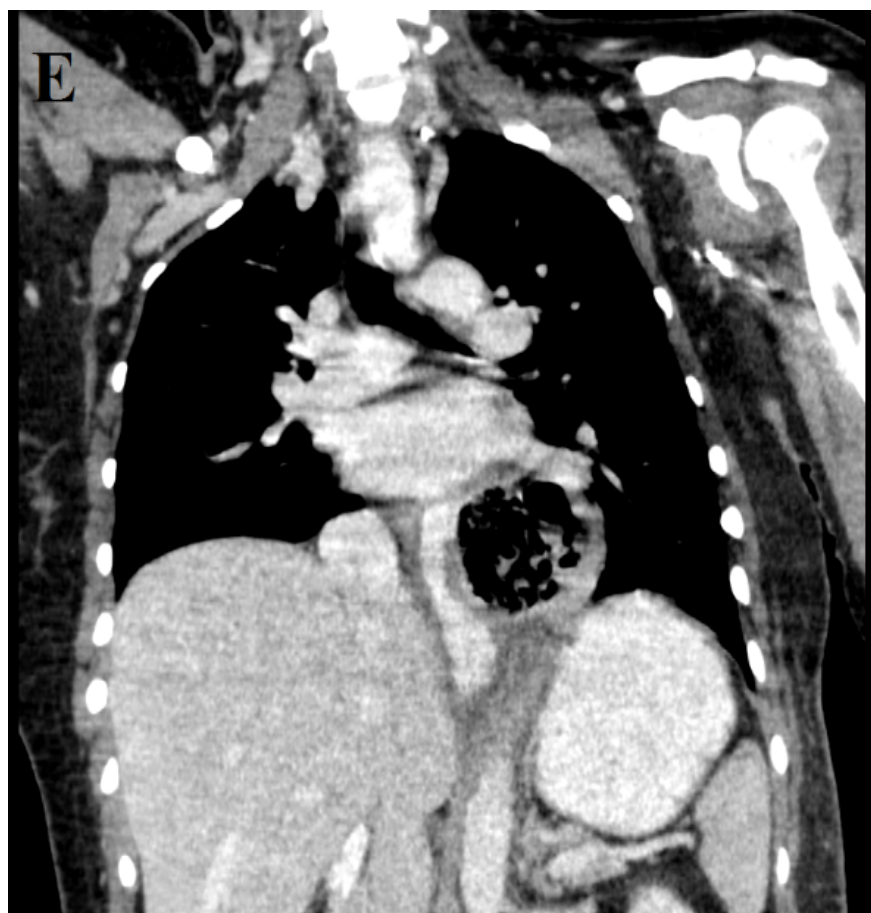
The patient had no evidence of GI bleeding and coffee ground contents. Hemoglobin drop was not seen in the labs and the patient's coagulation profile was normal. Therefore, the patient underwent supportive treatment and necessary preparations were made for surgical procedures. However, after a few hours of CT scan and before surgery, the patient had massive upper GI bleeding. Despite supportive fluid therapy and blood transfusion, the patient progressed to hypovolemic shock. Unfortunately, after the necessary resuscitation measures and adequate hemostasis, finally circulatory collapse occurred and patient expired due to cardiac arrest.











Discussion

Aortoesophageal Fistula (AEF) is an abnormal connective tract between the aorta and esophagus. There are multiple reasons for this condition. Its most common causes are thoracic aortic aneurysm, foreign body, and esophageal malignancies. Other common causes are complications after surgery, GERD and Tuberculosis (5). In a case report, Suzuki et al. reported the death of a Parkinsonian patient due to AEF caused by drug-induced esophagitis (6). Ju et al. et al also reported a case of AEF in a patient with dermatomyositis, which was probably caused by drug induced esophagitis and NG tube irritation (5). Chao et al. reported the incidence of AEF as a result of inflammation caused by botulinum injection in the esophagus (7). In most cases, pathologic process was inflammatory destruction of the aortic wall with pressure necrosis of soft tissue between the aorta and the esophagus that leading to formation of a fistula between the aorta and esophagus (8). we are imagine incident of AEF in our patient is result of inflammation and esophageal wounds caused by continuous vomiting and endoscopic procedures. so that the wound of the esophagus eventually deepened and passed through the wall of the esophagus and penetrated into the thoracic aorta.

Symptoms of AEF usually include chest pain and sentinel bleeding, after which there is an asymptomatic period of several hours to several days (Chiari triad). Then the patient has massive bleeding (9, 10). However, these symptoms have not been reported in all patients, so that sentinel bleeding has been reported in 50 to 90% of patients (2). Our patient did not have the typical symptoms of AEF. The patient's only symptom was chest pain after the bougienage procedure. Due to the absence of typical triad and lack of clinical suspicion of AEF, its diagnosis was delayed.

Chest X-ray and ECG are usually taken in a patient with chest pain. In a patient with AEF, mediastinal

widening may be seen (11). However, there was no significant change in Chest X-ray evaluation of our patient.

In the study of Saers et al. Only 38% of AEF cases were diagnosed at endoscopy (12). Therefore, endoscopy is not a good modality to diagnose AEF. As in our case, endoscopy did not useful in diagnosing this complication. However, classic endoscopic findings that favor the diagnosis of AEF include pulsatile bleeding and a submucosal mass with a adherent clot. Esophageal mucosa may also appear blue-gray due to submucosal hematoma (1).

On the other hand, due to the lack of contrast extravasation due to the temporary blockage of the fistula with a clot, angiography is not a suitable modality to diagnose AEF (8, 13).

In the study of Saer et al. It was shown that CT scan with IV contrast was useful in AEF diagnosis in more than 50% of patients. Therefore, in patients with suspected AEF, CT scan with IV contrast is the most favorable modality (12). Typical findings in CT scan are the presence of ectopic gas densities around the aortic lumen and loss of peri-aortic fat plane. Extravasation of contrast material from aorta to esophagus is characteristic but very rare finding.

Mycotic aneurysm is one of the causes of AEF. The presence of ectopic gas and aortic bulge and peri-aortic fat stranding in association with leukocytosis even without the presence of fever and positive blood culture can suggest it (2). In our patient, these findings were also present along with leukocytosis of 14.6×10^3 (PMN Dominant) and C-reactive protein equal to 46 mg/L, which can suggest the possibility of an underlying mycotic aneurysm. Mycotic aneurysm is caused by an infection of the aorta with microorganisms, and in a patient who has a perforation in the esophagus, mediastinal infection and invasion of the aorta wall by infectious agents can lead to this condition (14). In the CT scan performed on our patient, the evidence of microperforation of the esophagus and the resulting gas densities was also seen.

AEF treatment methods include surgery and thoracic endovascular aortic repair (TEVAR) (15). TEVAR has recently been recognized as a bridge therapy in a patient with AEF who is in shock (16). In a patient who is in shock due to severe bleeding and needs emergency measures to control the bleeding, TEVAR is a good option to stabilize the patient's condition and reduce mortality in the short term. As soon as the patient's conditions are suitable for AEF repair surgery (including aortic replacement, esophagectomy, and greater omentum wrapping), the patient undergoes surgical procedures (17-19).

In a summery, inflammation is the basis of fistula formation between aorta and esophagus. Also, endoscopic procedures and the resulting inflammation can lead to AEF. According to this case report, the occurrence of AEF can be with non-specific symptoms and without the classic Chiari triad. On the other hand, in the evaluation of endoscopy, in most cases, no specific findings are seen in favor of it. Therefore, the best modality to prove the diagnosis of AEF is CT scan with IV contrast injection.

consent statement

Written informed consent was obtained from the patient to publish this report in accordance with the journal's patient consent policy

Conflict of Interest

The authors declared no conflicts of interest.

Orcid

Hossein Bozorgi <https://orcid.org/0000-0002-8570-4116>

References

1. Heckstall R, Hollander J. Aortoesophageal Fistula: Recognition and Diagnosis in the Emergency Department. *Annals of Emergency Medicine*. 1998;32(4):502-5.
2. Monteiro A, Martins R, Martins da Cunha C, Moleiro J, Patrício H. Primary Aortoesophageal Fistula: Is a High Level of Suspicion Enough? *European journal of case reports in internal medicine*. 2020;7(8):001666.

3. Yang Y, Hu D, Peng D. Primary aorto-esophageal fistula: A fatal outcome. *The American Journal of Emergency Medicine*. 2018;36(2):343.e1-.e3.
4. Akin M, Yalcinkaya T, Alkan E, Arslan G, Tuna Y, Yildirim B. A Cause of Mortal Massive Upper Gastrointestinal Bleeding: Aorto-esophageal Fistula. *Medical archives (Sarajevo, Bosnia and Herzegovina)*. 2016;70(1):79-81.
5. Ju T, Lee C, Lin Y. Aorto-esophageal Fistula Causing Massive Gastrointestinal Bleeding and Death in a Patient with Dermatomyositis: A Case Report. *The American journal of case reports*. 2018;19:1025-9.
6. Suzuki H, Kawai S, Okada R, Hayashi Y, Kanazawa A, Mizuno Y, et al. Autopsy results of an elderly case of Parkinson's disease and aorto-esophageal fistula who died of a massive hematemesis during prolonged bed rest. *Nihon Ronen Igakkai zasshi Japanese Journal of Geriatrics*. 1993;30(5):387-92.
7. Chao C, Raj A, Saad N, Hourigan L, Holtmann G. Esophageal perforation, inflammatory mediastinitis and pseudoaneurysm of the thoracic aorta as potential complications of botulinum toxin injection for achalasia. *Digestive Endoscopy*. 2015;27(5):618-21.
8. Hollander J, Quick G. Aorto-esophageal Fistula: A comprehensive review of the literature. *The American Journal of Medicine*. 1991;91(3):279-87.
9. Carter R, Mulder G, Snyder E, Brewer L. Aorto-esophageal fistula. *The American Journal of Surgery*. 1978;136(1):26-30.
10. Macchi V, Porzionato A, Bardini R, Parenti A, De Caro R. Rupture of Ascending Aorta Secondary to Esophageal Perforation by Fish Bone. *Journal of Forensic Sciences*. 2008;53(5):1181-4.
11. Flores J, Shiiya N, Kuniyama T, Yoshimoto K, Yasuda K. Aorto-esophageal fistula: alternatives of treatment case report and literature review. *Annals of thoracic and cardiovascular surgery*. 2004;10(4):241-6.
12. Saers S, Scheltinga M. Primary aortoenteric fistula. *British Journal of Surgery*. 2005;92(2):143-52.
13. Khawaja F, Varindani M. Review of Clinical, Radiographic, and Endoscopic Features. *Journal of Clinical Gastroenterology*. 1987;9(3):342-4.
14. Zeng L, Shu W, Ma H, Hu J. Aortic injury caused by esophageal foreign body-case reports of 3 patients and literature review. *Medicine*. 2020;99(26):e20849.
15. Jonker F, Heijmen R, Trimarchi S, Verhagen H, Moll F, Muhs B. Acute management of aortobronchial and aorto-esophageal fistulas using thoracic endovascular aortic repair. *Journal of Vascular Surgery*. 2009;50(5):999-1004.
16. Canaud L, Ozdemir B, Bee W, Bahia S, Holt P, Thompson M. Thoracic endovascular aortic repair in management of aorto-esophageal fistulas. *Journal of Vascular Surgery*. 2014;59(1):248-54.
17. Akashi H, Kawamoto S, Saiki Y, Sakamoto T, Sawa Y, Tsukube T, et al. Therapeutic strategy for treating aorto-esophageal fistulas. *General Thoracic and Cardiovascular Surgery*. 2014;62(10):573-80.
18. Kubota S, Shiiya N, Shingu Y, Wakasa S, Ooka T, Tachibana T, et al. Surgical strategy for aorto-esophageal fistula in the endovascular era. *General Thoracic and Cardiovascular Surgery*. 2013;61(10):560-4.
19. Mezzetto L, Treppiedi E, Scorsone L, Giacomuzzi S, Perandini S, Macrì M, et al. Thoracic Aortic Pseudoaneurysm after Esophageal Perforation and Mediastinitis Caused by Accidental Ingestion of a Mutton Bone: A Case Report on Staged Endoscopic and Endovascular Treatments. *Annals of Vascular Surgery*. 2016;30:307.e15-.e19.

