

A CASE OF VAGAL CEPHALGIA AS A MANIFESTATION OF A LUNG NEOPLASM – A CASE REPORT AND REVIEW OF LITERATURE

Vivek Sanker¹, Sanjana Devaragudi², Sanobar Shariff³, Sheryl Deva⁴, Robert Mathew⁵, and Umang Gupta⁶

¹Noorul Islam Institute of Medical Science and Research Foundation Medicity

²Apollo Institute of Medical Sciences and Research

³Yerevan State Medical University Named after Mkhitar Heratsi

⁴Kamineni Academy of Medical Sciences and Research Centre

⁵Sree Mookambika Institute of Medical Sciences

⁶Nepalgunj Medical College

February 20, 2023

Abstract

Lung cancer can present with unilateral atypical facial pain, a rare symptom due to vagus nerve involvement or paraneoplastic syndrome. This manifestation is usually missed, delaying the diagnosis and prognosis. We discuss a case of a 45-year-old male who presented with right-sided hemifacial pain and with normal neurological investigations.

A CASE OF VAGAL CEPHALGIA AS A MANIFESTATION OF A LUNG NEOPLASM – A CASE REPORT AND REVIEW OF LITERATURE

Vivek Sanker^{1,2}, Sanjana Devaragudi^{2,3}, Sanobar Shariff^{2,4}, Sheryl Deva^{2,5}, Robert Mathew^{2,6}, Umang Gupta^{2,7}

¹Noorul Islam Institute of Medical Sciences, Trivandrum, India

²Team Erevnites, India

³Department of General Medicine, Apollo Institute of Medical Sciences and Research, Hyderabad

⁴ Yerevan State Medical University, Armenia

⁵Kamineni Academy of Medical Sciences and Research Centre, India

⁶ Professor, Department of Neurology, Sri Mookambika Institute of Medical Sciences, India

⁷Nepalgunj medical college, BP Chowk-12, Nepalgunj Banke, Nepal.

Corresponding author:

Umang Gupta

Nepalgunj medical college, BP Chowk-12, Nepalgunj Banke, Nepal

Email: dr.umaang@gmail.com

ORCID: 0000-0002-7911-8663

ORCID Ids:

Vivek Sanker: 0000-0003-0615-8397

Sanjana Devaragudi: 0000-0002-9667-8590 Sheryl Deva: 0000-0001-9525-9995 Sanobar Shariff: 0000-0002-2915-958X

KEYWORDS: Facial pain, Lung cancer, Vagal cephalgia, Vagus nerve

INTRODUCTION:

Unilateral facial pain has many medical and dental causes, like cluster headaches, trigeminal neuralgia, giant cell arteritis, temporomandibular joint dysfunction, oral abscess, dental decay, etc. However, when there is no definitive aetiology, it may be described as “Atypical facial pain” [1]. De Prez and Freemon reported the first case of atypical facial pain in association with lung cancer in 1983 [2]. Since then, cases have been reported where Facial pain was the first presenting symptom of Lung cancer. To our knowledge, there are 40 cases of this manifestation in the literature.

The term “Vagal Cephalgia” was first proposed by Evans for the facial pain and headache associated with non-metastatic lung cancer due to vagal nerve stimulation. This pain is usually persistent and severe. It is most commonly around the ear, jaw, and temporal region. Lung cancer is not always discovered on initial chest radiographs [3]. Therefore, physicians do not widely recognize lung cancer presentation, delaying the diagnosis and increasing morbidity and mortality [4]. We describe a case of a patient with lung cancer who presented with unilateral facial pain.

CASE REPORT:

Presentation and history of symptoms

The patient is a 45-year-old businessman with no history of Hypertension or Diabetes mellitus. There is no history of cancer in his family. He is an occasional smoker. The patient presents with pain on the right side of the face and hoarseness of voice for the past month. The patient also complained of losing appetite and weight for the past three months. The hemifacial pain had an insidious onset and was gradually progressing. The patient described it as a “constant, dull ache.” It was more prominent over the molar region, jaw, ear, and neck, all on the right side. Suspecting dental cause, he even underwent tooth extraction but had no relief.

There is no history of eye congestion or numbness of the face. No earache, tinnitus, or hearing loss was observed. The pain was not precipitated by chewing/swallowing. There is no positive history of jaw claudication, myalgias, or visual changes. No phonophobia or photophobia with vomiting and no family history of headache was observed. There was no history of cough, dyspnoea, haemoptysis, and epistaxis. There was also no history of memory loss, behavioural disturbances, dysphagia, dysarthria, or cranial nerve (CN) deficits. Motor, sensory deficits, or ataxia was not found. There was no history of fever, diarrhoea, melaena, or jaundice in the anamnesis.

General and organ-specific examinations

On general examination, the patient was afebrile. The pulse was 88/minute, and blood pressure (BP) was 150/90 Hg. There was no sign of pallor, clubbing, icterus, or lymph node enlargement. There was no scalp tenderness. The systemic examination started with the cardiovascular system, and the first and second heart sounds were normal. In the respiratory system, the lung fields were clear. Per abdominal examination, no hepatosplenomegaly or masses/free fluid was found. There was mild hoarseness of voice with the uvula in the central position. The palatal movements and gag reflex were normal. There were no abnormal tongue movements, motor/sensory deficits/cerebellar signs, or neck stiffness. The skull and spine appeared normal, and the Hypo Geomagnetic field (HMF) was normal. In the ophthalmological examination, the fundus

appeared normal. The extraocular movements and corneal/conjunctival reflex were normal. There was no abnormal sensation over the face or paresis of muscles of mastication.

Investigations

The Erythrocyte Sedimentation Rate (ESR) was 44 mm at 1 Hr. The remaining blood investigations were normal. The CSF study showed Protein at 22, glucose was 94, and no abnormal cells were found. The CSF cytology showed no malignant cells. The Computed Tomography (CT) scan of the brain showed a hypodense lesion in the Left Occipital region (Figure 1). An MRI scan of the neck and mediastinum was performed to rule out structural causes for the hoarseness of the voice. After extensive imaging, no structural cause of hemifacial pain syndrome was found. The ENT consultation revealed right vocal cord palsy. Given the suspicious cerebral lesion search for primary malignancy was made. CECT scan of the thorax showed a relatively well-defined enhancing soft tissue density lesion in the right lung with contiguous mediastinal lymphadenopathy (Figure 2). Squamous cell carcinoma was confirmed to be the diagnosis after the biopsy.

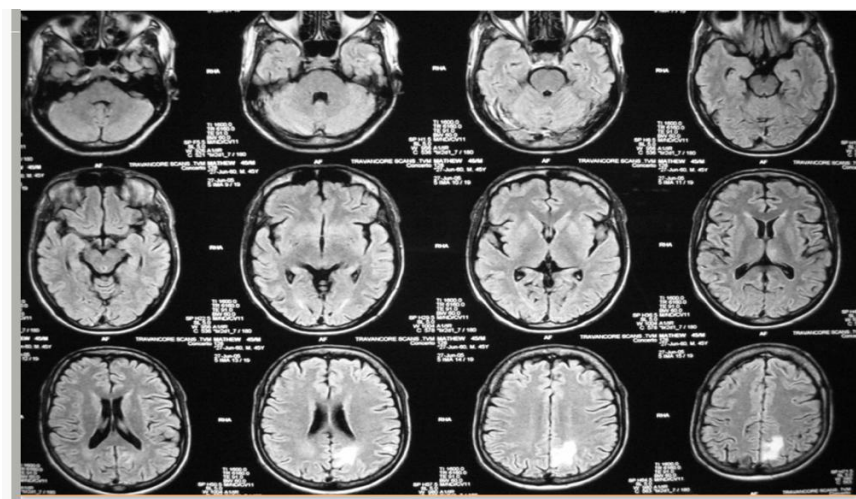


Figure 1. CT Brain: showed a hypodense lesion in the Left Occipital region (d/d: infarct, space-occupying lesion (SOL))

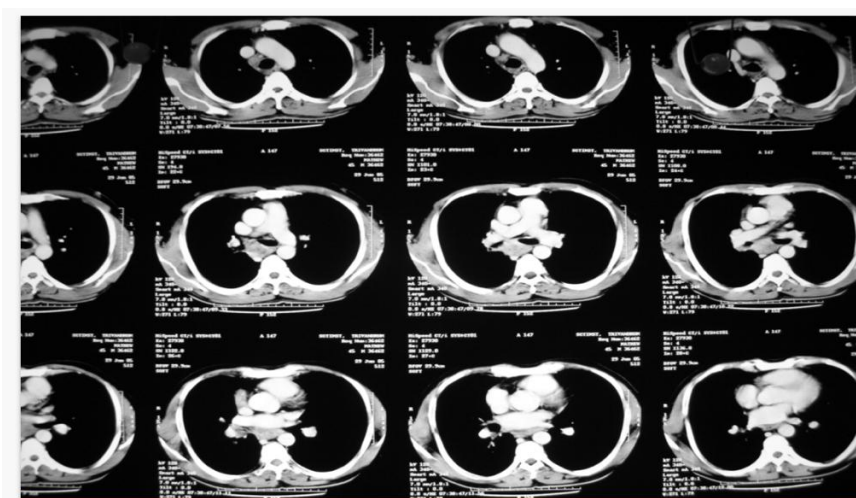


Figure 2: Contrast-enhanced Computed Tomography (CECT) Thorax: A relatively well-defined enhancing soft tissue density lesion in the right lung with contiguous mediastinal lymphadenopathy

DISCUSSION:

Our patient had a lung malignancy presenting as hemifacial pain syndrome and vocal cord palsy. In addition, the pain had the features of vagal cephalalgia, a type of atypical facial pain syndrome.

This facial pain is characterized by its unilateral nature, an aching quality that worsens over minutes and is localized around the ear, jaw, and temple. One of the causes of this type of pain is lung cancer, with the pain occurring ipsilateral to the cancer site, showing a dextral dominance [5]

The clinical characteristics of several documented cases of facial pain associated with lung cancer can be found in the literature. The ear, the mandible, and the temporal region are the most typical locations for face pain, which is nearly invariably unilateral. The discomfort may be constant or intermittent and is commonly described as intense and painful. Digital clubbing, an elevated ESR, and hypertrophic osteopathy may also influence the diagnosis. Treatment of face pain with radiotherapy and tumor removal via vagotomy is quite successful. Lung cancer should be considered when making a differential diagnosis for facial pain that is unusual or unresponsive to treatment. Face pain related to non-metastatic lung cancer may be caused by referred pain from vagal nerve invasion or compression and paraneoplastic syndrome brought on by the generation of circulatory humoral factors by the cancerous cells.

This is an uncommon presentation of lung malignancy. This pain arises as a referred pain from the lung via the vagus nerve. The visceral and somatic afferents terminate in the trigeminal nucleus. Due to the convergence of somatic and visceral afferents in the central nervous system (CNS), visceral pain is referred to as the somatic segment where they enter the CNS. Dextral dominance can be explained by the relationship of the right vagus nerve with the main bronchus and trachea, as the tumor can directly infiltrate the nerve.

In contrast, the left vagus is separated by the great vessels. Afferent impulses travel via the visceral afferents and connect with their somatic counterparts. Due to the extensive synapsing of cranial nerves V, VII, IX, and X in the trigeminal nucleus, a larger area of the face can be involved [6].

Sarlani E et al. also postulated the role of circulating humoral factors produced by the tumor causing a paraneoplastic syndrome as a possible explanation of facial pain in lung carcinoma [7].

A few similar cases in the literature are described below:

Study; Country; year	Demographic features	Past History	Duration of illness	Investigations	Treatment given
A case of intractable facial pain secondary to metastatic lung cancer; Italy;2008 [8]	70-year female	Non smoker	15-month history of constant facial pain.	Clinical examination: abnormal breath sounds, loss of sensation on right side of face. Chest X-ray: mass in right hilar region	Treatment with amitriptyline 40 mg/day and gabapentin (up to 2000 mg/day) was not successful. Pain resolved with radiation therapy and chemotherapy.

Lung cancer presenting with unilateral facial pain: remission after laryngeal nerve palsy; Italy;2006 [9]	39-year female	Smoked 1 pack of cigarettes a day for 20 years.	2-month history of facial pain on the left side.	Clinical examination: Supraclavicular lymphadenopathy CT scan chest: Mass in left mediastinum.	Gabapentin, carbamazepine, and prednisone did not relieve pain. The patient was treated with chemotherapy: gemcitabine and cisplatin
A review of intractable facial pain secondary to underlying lung neoplasms, USA;2003 [10]	63-year-old male	65 pack-year history of smoking	5 weeks of facial pain	ESR elevated Chest X-ray: right hilar mass.	Opioids were unsuccessful. Treated with radiation and chemotherapy.
Facial pain as the presenting symptom of lung carcinoma with normal chest radiograph; USA,2003 [1]	52-year-old man	Smoked 3 packs of cigarettes per day for 40 years. Family history of his father having died of lung cancer.	6 months of sharp facial pain	WBC count elevated Chest X-Ray: Right lower lobe mass.	Pain did not reduce with NSAIDs and narcotic analgesics. Did not respond to radiation therapy.
Facial pain as the presenting symptom of lung carcinoma with normal chest radiograph; USA;2003 [1]	63-year-old male	History of left lower lobectomy for adenocarcinoma-of the lung. 120 pack-year smoking history.	1-month history of progressive pain	ESR elevated. CT chest: subcarinal mass	Radiotherapy.
Persistent unilateral facial pain in lung cancer patients with mediastinal nodal involvement; UK;2013 [4]	62-year-old man	History of wedge resection for lung cancer.	After 5 months of resection, he developed facial pain.	CT, MRI showed mass in lung and brain	Opioids, NSAIDs and neuropathic adjuvants failed. Palliative radiotherapy and cisplatin – etoposide chemotherapy relieved the pain.
Persistent unilateral facial pain in lung cancer patients with mediastinal nodal involvement; UK;2013 [4]	65-year-old woman	No	12 months history of right jaw pain	Investigations revealed a T4NXM0 squamous cell carcinoma of the lung. She was given palliative radiotherapy to the chest, 36 Gy in 12 fractions	Amitriptyline gave little pain relief. Palliative radiotherapy to the chest completely resolved the pain.

Facial pain associated with lung cancer: a case report;1983 [2]	45-year-old male	No	4 months of deep, boring pain near maxilla	ESR elevated Chest X ray: mass in right lower lobe	Ibuprofen, carbamazepine and diphenhydramine Hydrochloride did not reduce pain but, aspirin and acetaminophen did. Pain completely resolved on surgical resection.
Unilateral facial pain as the first symptom of lung cancer: are there diagnostic clues? Belgium;1992 [11]	53-year-old	Smoker	12-month history of facial pain	Adenocarcinoma of the right superior lobe was diagnosed	Pain was not relieved by analgesics and sphenopalatine ganglion anaesthesia. Radiotherapy completely resolved pain.
Facial pain as a symptom of nonmetastatic lung cancer; USA;1995 [5]	68-year-old woman	40 pack year smoking history	1-year history of right sided facial pain	Clubbing present Chest X ray: Middle lobe nodular infiltrate	The pain did not respond to amitriptyline, narcotic medications, carbamazepine, phenytoin. Radiotherapy and chemotherapy resolved pain.

For diagnosis of atypical facial pain (ATFP), the international classification of headache disorders has described the following criteria [12]:

1. Facial pain recurring for more than 2 hours in a day for a period of 3 months
2. Poorly localized, dull aching, or nagging pain
3. Clinical neurological examination and dental examination are normal

Physicians still diagnose atypical facial pain by exclusion as all these symptoms are nonspecific. A complete clinical examination must rule out other causes like dental infections, vascular factors, craniofacial tumors, trigeminal neuralgia, and migraine. Radiological diagnosis, including computed tomography or magnetic resonance imaging, should support the diagnosis [12,13]. Especially if the patient is a smoker, a chest radiograph is essential to rule out lung neoplasms presenting as facial pain [6]

Thus, a multidisciplinary approach is essential for the diagnosis of atypical facial pain [14]

Treatment of ATFP is often unsatisfactory, so patient education often becomes essential [15]. Antidepressants [4], which include amitriptyline, duloxetine, venlafaxine, and Anticonvulsants [10] (carbamazepine,

oxcarbazepine, phenytoin, gabapentin, lamotrigine) have been used to treat ATFP. Other agents that give relief are botulinum toxin A, local anaesthetics like lignocaine, muscle relaxants (baclofen), phentolamine, and selective serotonin receptor agonists (sumatriptan) [16]. As this is neuropathic pain, high-frequency repetitive transcranial magnetic stimulation (rTMS) on the right somatosensory cortex aborted pain significantly [17]. Chemotherapy is the least effective [15]. Radiotherapy, vagotomy, and tumor resection are the standard forms of treatment for ATFP [7]. Patients respond excellently to resection, but surgery is not possible due to delayed diagnosis as 79 of patients have had a regional spread. Radiation therapy also helps to ameliorate pain, but the response occurs over months. Most patients die before pain relief is obtained [15].

CONCLUSION:

Early detection of lung carcinoma has to be accomplished to prevent morbidity and mortality, and atypical facial pain should be considered a possible manifestation.

CONFLICTS OF INTEREST:

None declared.

AUTHOR CONTRIBUTION:

All the authors contributed equally in drafting, editing, revising and finalizing the case report.

ETHICAL APPROVAL:

The ethical approval was not required for the case report as per the country's guidelines.

CONSENT:

Written informed consent was obtained from the patient to publish this report.

DATA AVAILABILITY STATEMENT:

The data that support the findings of this article are available from the corresponding author upon reasonable request.

References:

1. Abraham PJ, Capobianco DJ, Cheshire WP. Facial pain as the presenting symptom of lung carcinoma with normal chest radiograph. Headache [Internet]. 2003;43(5):499–504. Available from:<http://dx.doi.org/10.1046/j.1526-4610.2003.03097.x>
2. Des Prez RD, Freemon FR. Facial pain associated with lung cancer: a case report. Headache [Internet]. 1983;23(1):43–4. Available from:<http://dx.doi.org/10.1111/j.1526-4610.1983.hed2301043.x>
3. Evans RW. Hemicrania Continua-like headache due to nonmetastatic lung cancer—a vagal cephalalgia. Headache [Internet]. 2007;47(9):1349–51. Available from:<http://dx.doi.org/10.1111/j.1526-4610.2007.00936.x>
4. Pembroke CA, Byrne A, Lester JF, Button M. Persistent unilateral facial pain in lung cancer patients with mediastinal nodal involvement. Lung Cancer [Internet]. 2013;82(1):173–5. Available from:<http://dx.doi.org/10.1016/j.lungcan.2013.06.024>
5. Capobianco DJ. Facial pain as a symptom of nonmetastatic lung cancer. Headache [Internet]. 1995;35(10):581–5. Available from:<http://dx.doi.org/10.1111/j.1526-4610.1995.hed3510581.x>
6. Bindoff L, Heseltine D. Unilateral facial pain in patients with lung cancer: A referred pain via the vagus? Lancet [Internet]. 1988;331(8589):812–5. Available from:[http://dx.doi.org/10.1016/s0140-6736\(88\)91668-6](http://dx.doi.org/10.1016/s0140-6736(88)91668-6)

7. Sarlani E, Schwartz AH, Greenspan JD, Grace EG. Facial pain as the first manifestation of lung cancer: a case of lung cancer-related cluster headache and a review of the literature. *J Orofac Pain*. 2003 Summer;17(3):262–7.
8. Ruffatti S, Zanchin G, Maggioni F. A case of intractable facial pain secondary to metastatic lung cancer. *Neurol Sci* [Internet]. 2008;29(2):117–9. Available from: <http://dx.doi.org/10.1007/s10072-008-0871-z>
9. Palmieri A. Lung cancer presenting with unilateral facial pain: remission after laryngeal nerve palsy. *Headache* [Internet]. 2006;46(5):813–5. Available from: <http://dx.doi.org/10.1111/j.1526-4610.2006.00458.x>
10. Eross EJ, Dodick DW, Swanson JW, Capobianco DJ. A review of intractable facial pain secondary to underlying lung neoplasms. *Cephalalgia* [Internet]. 2003;23(1):2–5. Available from: <http://dx.doi.org/10.1046/j.1468-2982.2003.00478.x>
11. Schoenen J, Broux R, Moonen G. Unilateral facial pain as the first symptom of lung cancer: are there diagnostic clues? *Cephalalgia* [Internet]. 1992;12(3):178–9. Available from: <http://dx.doi.org/10.1046/j.1468-2982.1992.1203178.x>
12. Headache classification committee of the international headache society (IHS), the international classification of headache disorders, 3rd edition. *Cephalalgia* [Internet]. 2018;38(1):1–211. Available from: <http://dx.doi.org/10.1177/0333102417738202>
13. Clarkson E, Jung E. Atypical facial pain. *Dent Clin North Am* [Internet]. 2020;64(1):249–53. Available from: <http://dx.doi.org/10.1016/j.cden.2019.08.014>
14. Benoliel R, Gaul C. Persistent idiopathic facial pain. *Cephalalgia* [Internet]. 2017;37(7):680–91. Available from: <http://dx.doi.org/10.1177/0333102417706349>
15. Agostoni E, Frigerio R, Santoro P. Atypical facial pain: clinical considerations and differential diagnosis. *Neurol Sci* [Internet]. 2005;26 Suppl 2(S2):s71–4. Available from: <http://dx.doi.org/10.1007/s10072-005-0412-y>
16. Do TM, Unis GD, Kattar N, Ananth A, McCoul ED. Neuromodulators for atypical facial pain and neuralgias: A systematic review and meta-analysis. *Laryngoscope* [Internet]. 2021;131(6):1235–53. Available from: <http://dx.doi.org/10.1002/lary.29162>
17. Lindholm P, Lamusuo S, Taiminen T, Pesonen U, Lahti A, Virtanen A, et al. Right secondary somatosensory cortex-a promising novel target for the treatment of drug-resistant neuropathic orofacial pain with repetitive transcranial magnetic stimulation. *Pain* [Internet]. 2015;156(7):1276–83. Available from: <http://dx.doi.org/10.1097/j.pain.000000000000175>