

PERICARDIAL BELT RING-INDUCED CARDIAC CHAMBER MALFORMATION

Lam Truong Hoai¹, Duyen Nguyen Thi¹, Trang Nguyen Thu¹, and Oanh Nguyen Thi¹

¹Tam Anh Hospital

February 1, 2023

Abstract

Pericardial calcification (PC) typically appears following pericarditis or trauma. The aetiologies of other conditions, such as chronic idiopathic pericarditis, post-cardiac surgery, and mediastinal irradiation, can result in the development of calcified pericardium. This case reports an encounter treating constrictive pericardium which is a belt ring resulting in cardiac chamber malformation.

Introduction

The pericardium is a fibrous, stiff, avascular sac whose main purposes include minimal anchoring, lubricating, preventing heart chamber distention, and enhancing diastolic filling. Calcium deposits are often absent from the pericardium, therefore calcification could indicate an underlying inflammatory condition or a more severe cause. Chest computed tomography is the radiographic procedure that most frequently identifies pericardial calcification(1). The results of necrosis, fibrosis, and inflammation are pericardial calcification. The most frequent causes of this inflammation include viral infections, exposure to chest radiation, and subsequent heart surgery. Uremic pericarditis, trauma, cancer, rheumatologic conditions, and connective tissue illnesses are among other known etiologies. Despite these recognized correlations, it is believed that more than 50% of pericardial calcification cases are idiopathic(2). When a patient presents with predominant right-sided heart failure (HF), cardiologists should have a high index of suspicion for CP, especially if there is a history of cardiac surgery, pericarditis, or pericardial effusion. The most reliable way to diagnose CP in the majority of patients is through transthoracic two-dimensional and Doppler echocardiography, which may accurately detect the condition due to the heart's distinctive real-time motion and hemodynamic properties. When clinical or echocardiographic results are ambiguous, computerized tomography and magnetic resonance imaging are very helpful in providing incremental data for the diagnosis and management of CP.

Presentation

A 48-year-old man who had underlying medical conditions appeared with cirrhosis diagnosed during the previous two years. Additionally, abdominal distension, bilateral leg edema, and jaundice were linked to it. Other than that, he denied experiencing any orthopnea, paroxysmal nocturnal dyspnea, or chest pain. He revealed a history of pericardial effusion which was idiopathic when he was 4 years old.

He started to occasionally experience bilateral leg edema and abdominal distension as the symptoms grew worse over time. He sought therapy from a general practitioner because of the unsolved symptoms. He was directed to a cardiologist for additional testing because oral drugs were unable to completely relieve his symptoms.

He was found to have a calcified pericardium from the imaging examinations (Figures 1A and 1B), hence

constrictive pericarditis with calcified pericardium was identified which figure out the belt ring led to deformation ventricular

Echocardiography showed deformation of the left ventricular with preserved ejection fraction, mild dilation of atrial, and mild pulmonary hypertension (Video 1). ECG showed atrial fibrillation (Figure 2).

Later, after receiving counseling, he was admitted to our cardiothoracic unit, where a pericardiectomy was decided upon. The goal of this treatment was to partially remove the calcified pericardium to free the heart from its constricted space (Figure 3). To access his calcified pericardium, the surgeon performed the procedure through an open median sternotomy. The postoperative course was uncomplicated, and the two ventricular chambers were well dilated. On the 20th day after surgery, the patient was discharged.

Discussion

Anatomical pericardial calcification is a significant discovery when constrictive physiology is present. Because of this, imaging for the condition involves both the detection of pericardial calcification and its hemodynamic effects.

Chest radiography has a low sensitivity, which makes it difficult to detect pericardial calcification. Alkaline phosphatase and serum creatinine levels may be elevated according to the laboratory workup. Additionally, the natriuretic peptides B-type and N-terminal pro-brain are typically utilized to distinguish CP from restrictive cardiomyopathy(3). Two-dimensional (2-D) echocardiography and tissue Doppler imaging are perhaps the most important methods for diagnosing CP since they may be used to assess the functional importance of pericardial calcification. Abnormal septal motion increased interventricular interdependence, and many inferior vena cava are all seen on 2-D echocardiography (2). Cardiac MRI can be used to characterize the cardiac structure and pericardial thickness, but it can also reveal details on ventricular septal motion, displaying the so-called "septal bounce" and "septal shudder." (2) Although cardiac MRI does not detect pericardial calcification as precisely as CT, it is a good tool for determining the degree of edema and scarring, which improves in evaluating the course of the disease and identifying which patients are more susceptible to developing CP(4). In the absence of symptoms, pericardial calcification does not need to be treated. Anti-inflammatory medication may be effective in subacute cases of constrictive pericarditis with underlying inflammation (such as colchicine, corticosteroids, and non-steroidal anti-inflammatory drugs). Anti-inflammatory drugs, however, are generally unable to repair fibrosis and calcification and are instead primarily intended to stop the spread of inflammation and further scarring. The gold standard for CP treatment and a potentially curative procedure is pericardiectomy surgery. The rate of success of pericardiectomy is typically high (70–80%), however, there is a substantial perioperative number of fatalities of 5–10%. According to the New York Heart Association, patients with heart failure in NYHA Classes I and II often had better postoperative results than those with heart failure in NYHA Classes III and IV. Typically, the presence and degree of pericardial calcification have no impact on the results of surgical procedures (5). If there are symptoms along with pericardial calcification, further testing should be done since constrictive pericarditis may be present and may be treatable. Due to complications related to heart failure and the low output state, constrictive pericarditis portends a very bad prognosis in the absence of surgical pericardiectomy. The best course of treatment for constrictive pericarditis is early pericardiectomy with complete decortication (if technically possible), which offers effective symptom alleviation before severe constriction and myocardial atrophy develop.

Conclusion

In the long run, Cirrhosis is caused by a constrictive pericardium, which is a belt ring that causes cardiac chamber deformity and decreased diastolic function. Primary cirrhosis-like symptoms are caused by this condition. To relieve the ventricles' stiffness, surgery is the best course of action.

References

1. Nguyen T, Phillips C, Movahed A. Incidental findings of pericardial calcification. *World J Clin Cases*. 2014;2(9):455-8.

2. Miranda WR, Oh JK. Constrictive Pericarditis: A Practical Clinical Approach. *Prog Cardiovasc Dis.* 2017;59(4):369-79.
3. Diaz-Arocutipa C, Saucedo-Chinchay J, Imazio M, Argulian E. Natriuretic peptides to differentiate constrictive pericarditis and restrictive cardiomyopathy: A systematic review and meta-analysis. *Clin Cardiol.* 2022;45(3):251-7.
4. Al-Mallah MH, Almasoudi F, Ebid M, Ahmed AM, Jamiel A. Multimodality Imaging of Pericardial Diseases. *Curr Treat Options Cardiovasc Med.* 2017;19(12):89.
5. Depboylu BC, Mootoosamy P, Vistarini N, Testuz A, El-Hamamsy I, Cikirikcioglu M. Surgical Treatment of Constrictive Pericarditis. *Tex Heart Inst J.* 2017;44(2):101-6.

ACKNOWLEDGEMENTThe author would like to thank the patient who agreed to participate in this study and Tam Anh Hospital for financial support.**CONFLICTS OF INTEREST**Conflict of interest relevant to this article was not reported.**AUTHOR CONTRIBUTIONS**All authors contributed to data analysis, drafting, or revising the article, have agreed on the journal to which the article will be submitted, gave final approval of the version to be published, and agree to be accountable for all aspects of the work.**FUNDING INFORMATION**Not applicable.**CONSENT**Written informed consent form was given to patient.**ORCID**Lam Truong Hoai <https://orcid.org/0000-0002-7579-2909> **Data Availability Statement:** availability of data and materials supporting our findings will be shared upon request.

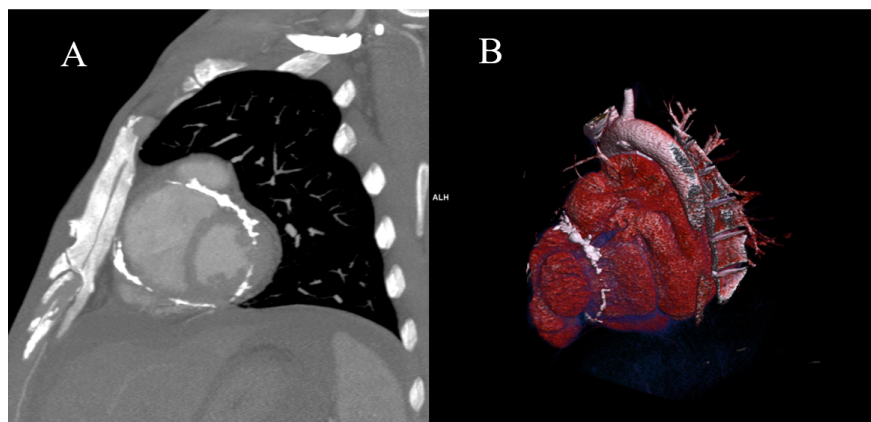


Figure 1 A and B: Chest Computed Tomography showed constrictive pericardium which was pericardial calcification

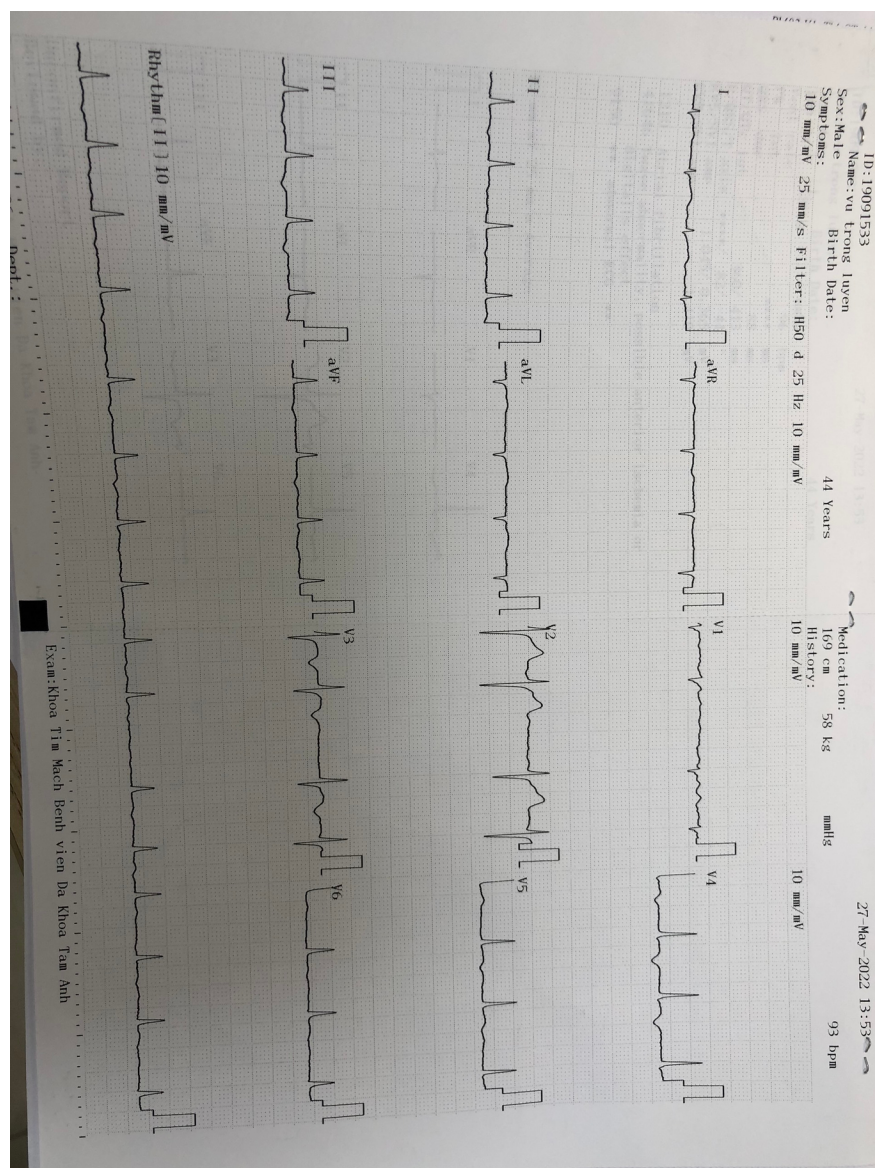


Figure 2 Echocardiogram showed atrial fibrillation

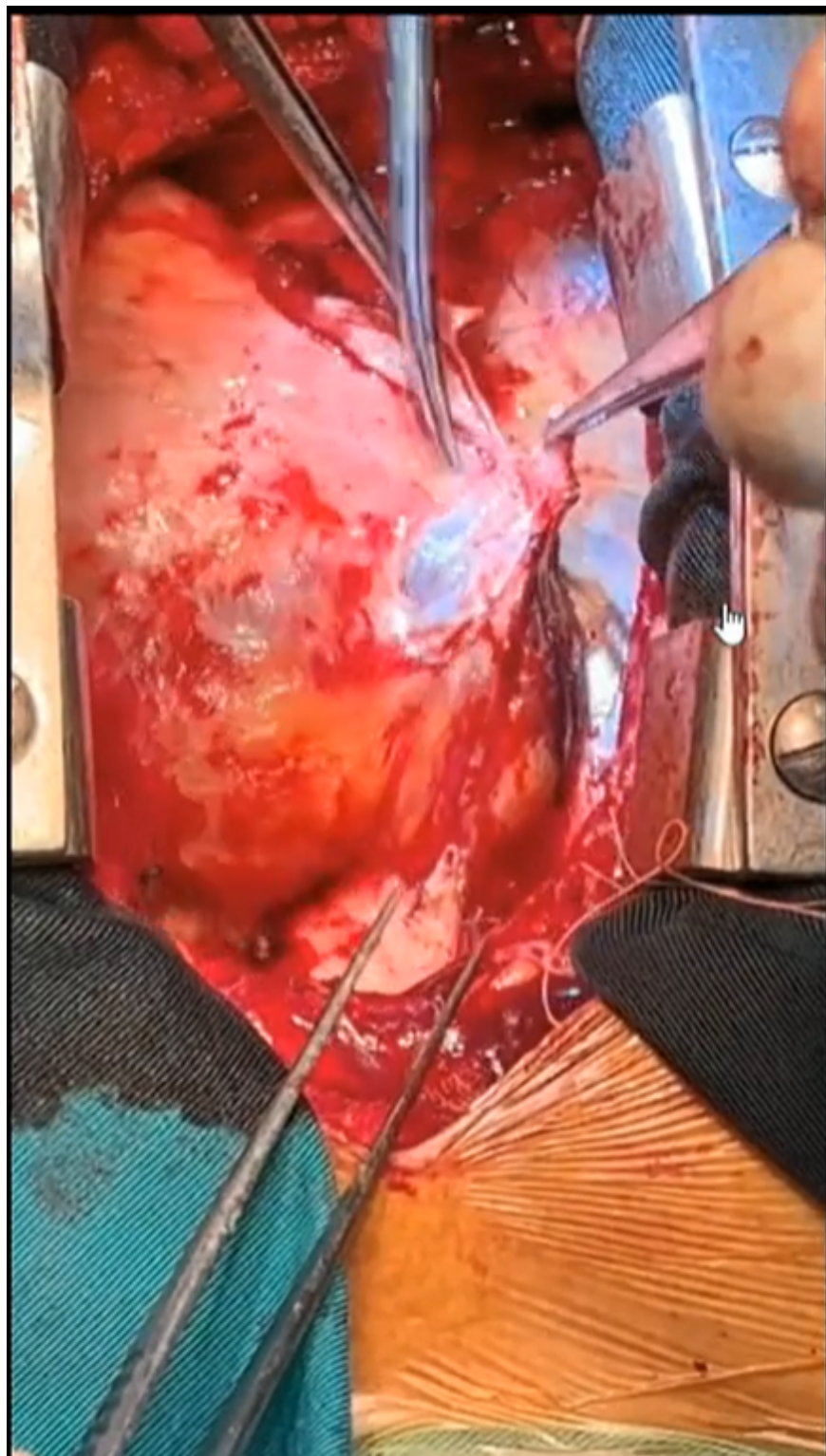
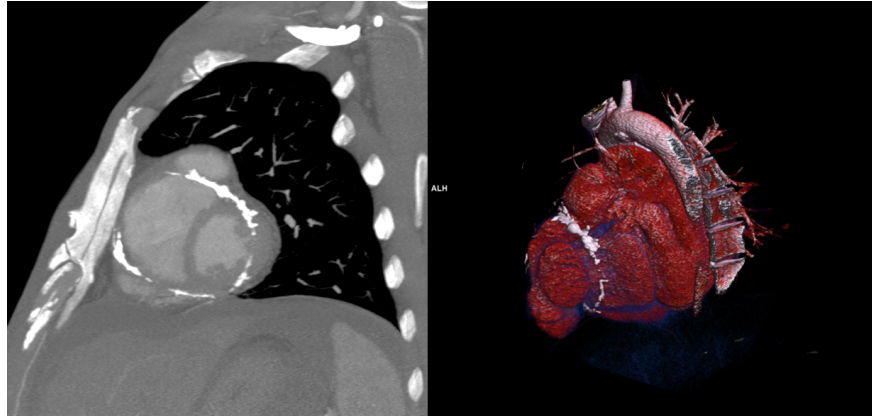
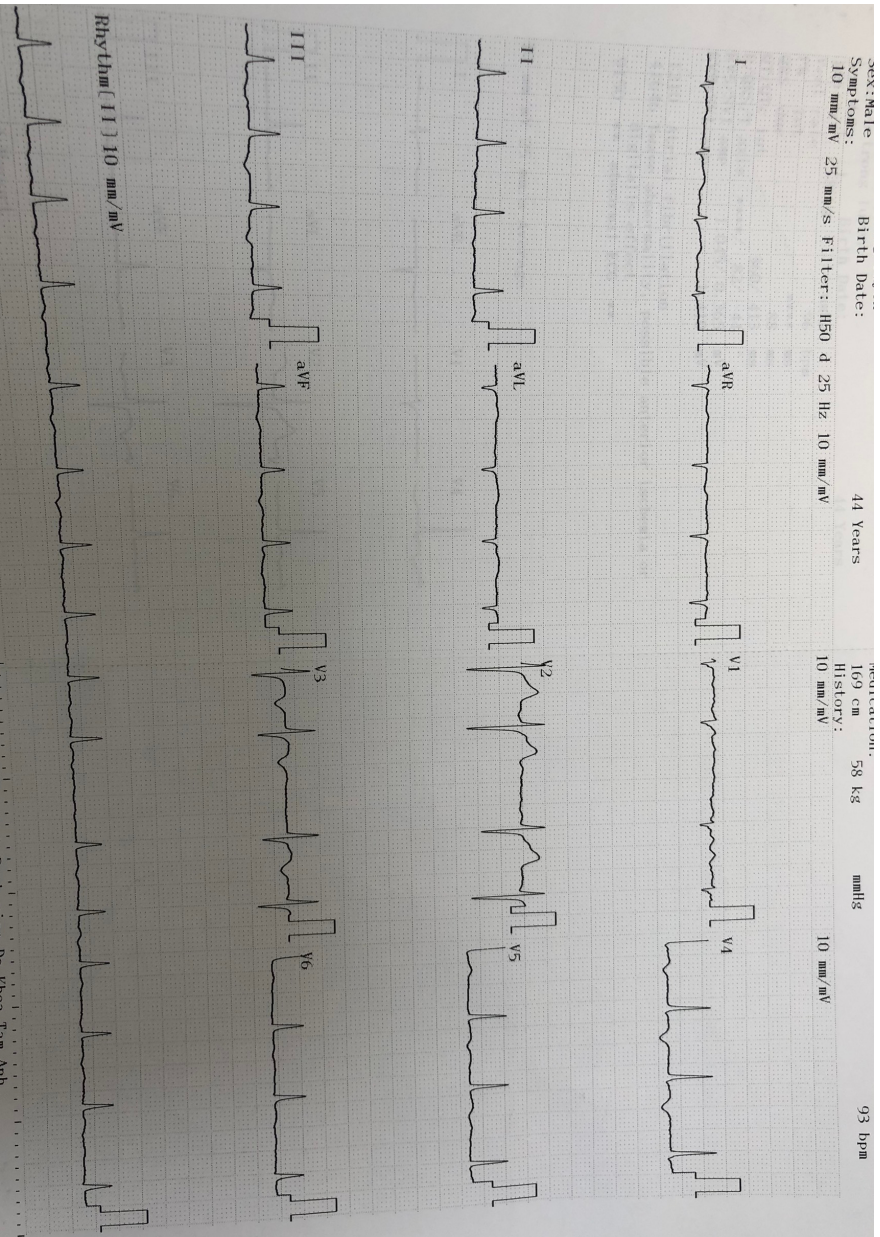
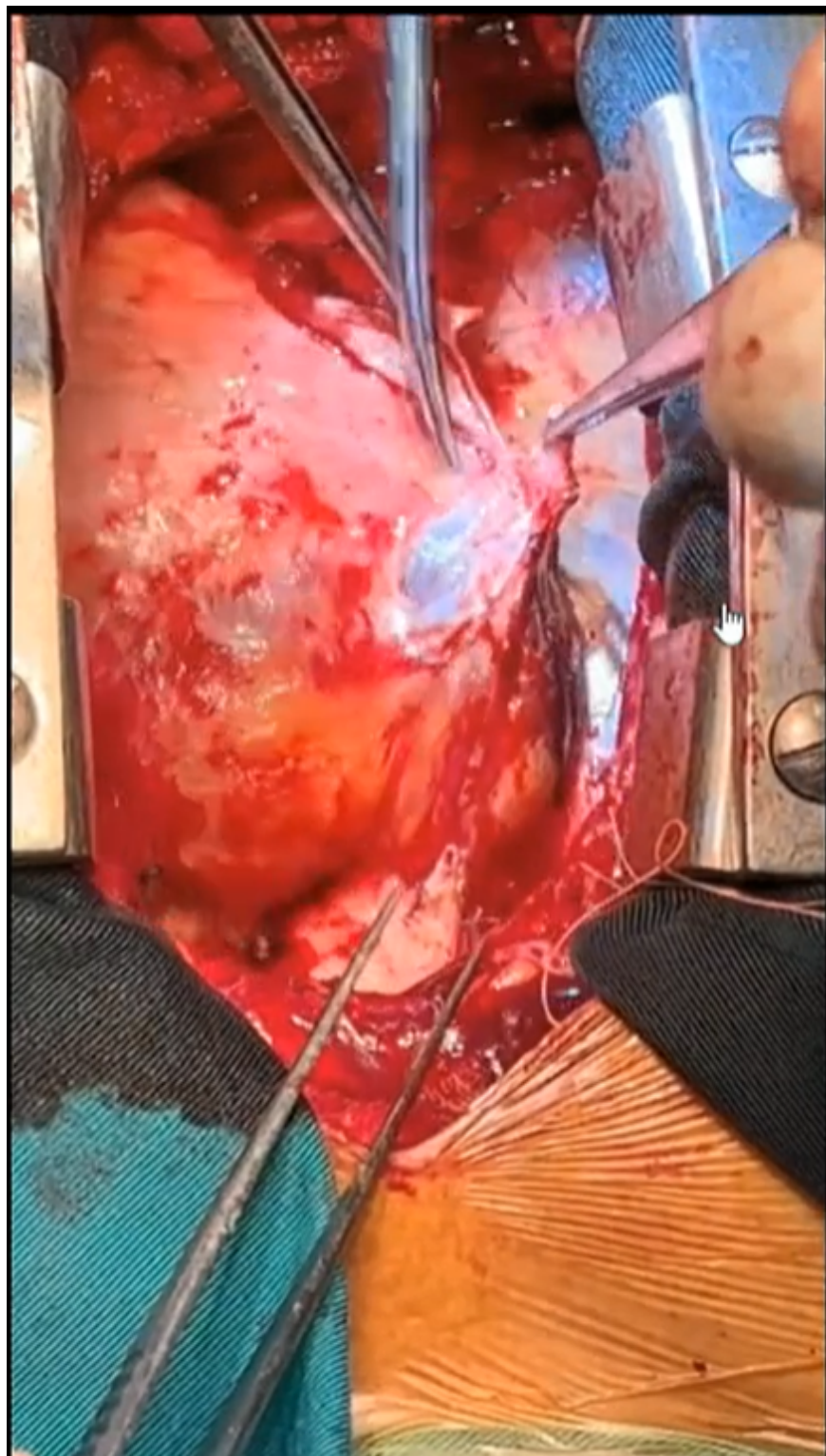


Figure 3: The pericardium was removed from phrenic to phrenic during an anterior pericardiectomy.

Video 1: Echocardiography showed deformation of left ventricular and mild atrial dilation







Hosted file

Title page.docx available at <https://authorea.com/users/424725/articles/622171-pericardial-belt-ring-induced-cardiac-chamber-malformation>