

# A Rare Case of Biatrial Myxoma in a Young Male Presenting with Cerebrovascular Accident

Harnek Singh<sup>1</sup>, Cynthia Chen-Joea<sup>1</sup>, and Tana Parker<sup>2</sup>

<sup>1</sup>Emanate Health Queen of the Valley Hospital

<sup>2</sup>Clinica Sierra Vista

November 12, 2022

## Abstract

Biatrial cardiac myxomas are extremely rare, as the reported incidence is less than 2%. This report highlights a young 23-year-old, previously healthy male who presented with a cerebrovascular accident likely secondary to biatrial myxomas that were incidentally found during the stroke evaluation.

Title Page:

**A Rare Case of Biatrial Myxoma in a Young Male Presenting with Cerebrovascular Accident**

**Authors:** Singh, Harnek, MD. Chen-Joea, Cynthia, DO, MPH. Parker, Tana, MD

Emanate Health Family Medicine Residency Program  
1115 S. Sunset Ave, West Covina, CA 91790

1. Harnek Singh, MD, Core Faculty  
Emanate Health Family Medicine Residency Program  
1115 S. Sunset Ave, West Covina, CA 91790
2. Cynthia Chen-Joea DO, MPH.  
Associate Program Director  
Emanate Health Family Medicine Residency Program  
1115 S. Sunset Ave, West Covina, CA 91790
3. Tana Parker, MD, Associate Program Director  
Rio Bravo Family Medicine Residency Program  
7800 Niles St, Bakersfield, CA 93306

Corresponding author information:

Harnek Singh, MD  
Cell: 714-271-9834  
Email: harnek08@gmail.com

Consent:

Written informed consent was obtained from the patient to publish this report in accordance with the journal's patient consent policy.

Patient's name is not mentioned in this case report.



## **Abstract**

Cardiac myxomas are the most common primary noncancerous neoplasms found in the heart. Most cardiac myxomas arise in the left atrium (over 85%), and the rest much less frequently from the mitral valve (6%) , right atrium (4%) and occasionally from the ventricles. Biatrial cardiac myxomas are extremely rare, as the reported incidence is less than 2%. This case report describes a young 23-year-old previously healthy male who presented with unilateral weakness and was admitted for an ischemic stroke likely secondary to biatrial myxomas that were incidentally found during the stroke evaluation. Given the rarity of biatrial myxomas, early cardiac evaluations for young adults presenting with cardiovascular and/or neurologic symptoms may be crucial to diagnosis, treatment and potential prevention of subsequent systemic embolic events. Further analysis, data collection and insight is needed to better understand the potential correlations between biatrial myxomas and cerebrovascular events.

**Keywords:** biatrial myxoma, stroke, male, weakness, cardiothoracic surgery, cardiac tumors, embolization

## Introduction

Primary cardiac tumors are extremely rare. In one series of over 12,000 autopsies, only 7 were identified, for an incidence of less than 0.1 percent [1]. Myxomas are the most common type of cardiac tumors, with most being noncancerous as they do not invade other tissues (cite).

Histologically, these tumors are composed of cells that originate from a multipotent mesenchymal cell capable of neural and endothelial differentiation [2]. Myxomas vary in size and consistency, with appearances being smooth, villous or friable measuring anywhere between 1 and 15 cm in diameter. They are most often found in the left atrium ( over 85%) and the rest much less frequently arise from the mitral valve (6%) , right atrium (4%) and occasionally from the ventricles. [3-6]. Biatrial myxomas are extremely rare, and even rarer for them to grow individually from both atria. Myxomas may present with a multitude of symptoms within the cardiovascular and neurologic systems. Cardiovascular symptoms, which may include dyspnea, orthopnea, edema and fatigue, are present in 67% of the patients with left atrial myxomas. Symptoms that develop may depend on the location of the tumor, with the most common being mitral valve obstruction associated with left atrial hypertrophy [7]. About 29% of the patients show evidence of systemic embolization and 20% have subsequent neurologic events and/or deficits, such as syncope or stroke [7]. Multiple studies show that left atrial myxomas increase the risk of an embolizing event. However, there is little to no literature explaining whether multiple myxomas may increase the likelihood of experiencing cardiovascular and/or neurological events. Unfortunately, cardiac tumors such as myxomas are often discovered incidentally during evaluation for a seemingly unrelated problem or physical finding. There are currently no screening guidelines for myxomas. However, it is important to keep myxomas as a differential, especially in the case of an embolizing event in a young previously healthy adult.

## Case Report

A 23 year old male with no significant past medical history presented to the hospital with new onset right-sided weakness for one hour prior to arrival. He was at work when his coworkers noticed slurred speech in mid-conversation.

**Vitals:** Tmax 37 C (oral), HR: 98, RR: 20, BP: 140/81, SpO2: 99%

### **Physical exam:**

General: anxious appearing, profound aphasic speech

CV: regular rate and rhythm, **no murmurs**, gallops or rubs

Lungs: clear to auscultation bilaterally

Abd: soft and non tender

Neuro: Right facial weakness, no blink, asymmetric palatal elevation and tongue movement

Motor: Right arm and leg are flaccid, not able to move against gravity but slight flexion of the right arm to pain. Left arm and leg can move against gravity but needs assistance

Sensory: Able to feel pain bilaterally

Code Stroke was activated in the emergency room that consisted of stat orders of labs, EKG, imaging and consultation to teleneurology to determine whether the patient is a candidate for tPA treatment. Imaging and labs were obtained which showed:

### **Labs:**

CBC: WBC 10.7, Hgb 12.5, Hct 37.2, Platelet 400

Coag: PT 14.5, INR 1.3, PTT 28.1

Comprehensive metabolic panel: all within normal limits

Troponin: <0.030

COVID test: negative

ESR: 53

CRP: 14.1

Hemoglobin a1c: 5.6%

Lipid panel: Chol 190, HDL 43, LDL 138, Trig 66

Folate: 17.6

Vitamin B12: 230

**Imaging:**

**Chest X-ray:**

No acute cardiopulmonary disease

**CT Brain/Head without Contrast:**

No acute intracranial abnormality

**CT Brain and Neck:**

Left MCA M1 segment occlusion/thrombus formation with attenuated distal branches. No cervical carotid artery stenosis

**MRI head/brain wo con:** Multifocal regions of acute to subacute ischemia within the left middle cerebral artery territory

**Echocardiogram/Transesophageal echocardiogram:**

Shows a large mobile mass in the left atrium. There is also a smaller mass in the right atrium.

The right atrial mass appears to be attached to the septum. Attachment point for the left atrial mass is unclear, may be the septum or may be the anterior leaflet of the mitral valve.

The patient was admitted for an acute cerebrovascular accident (CVA) due to a large vessel occlusion in the left middle cerebral artery M1 segment based on the imaging findings.

Neurology evaluated the patient, and felt he was a candidate for a left cerebral artery thrombectomy and tPA treatment. A transthoracic echocardiogram ordered as part of the stroke work up showed a mass in the left atrium concerning a myxoma. The patient had a TEE, which showed a large mobile mass in the left atrium and a smaller mass in the right atrium. Cardiothoracic surgery was consulted and evaluated for possible intervention. The patient was immediately transferred to a partner cardiac center at a neighboring hospital for resection of the atrial mass. Upon transfer, his right-sided weakness resolved significantly, with persistent symptoms of Broca's aphasia. Once neurologic symptoms stabilized the patient underwent cardiothoracic surgery on cardiopulmonary bypass for resection of the mass. During the operation, a large 4x6 cm mass in the left atrium (Image A), and a small 1x2 cm mass in the right atrium (Image B) were excised and sent for pathology for confirmation. The patient had an uneventful recovery following the surgery, and subsequently was admitted to inpatient cardiac rehab where he underwent extensive physical, speech and occupational therapy. The patient had a swift recovery, and was discharged home within the week. The patient was discharged with metoprolol 25 mg, simvastatin 20mg, aspirin 81 mg and instructions to continue outpatient cardiac rehabilitation. Follow up appointments were made for the patient with cardiology, cardiothoracic surgery, and neurology in the outpatient clinics.



## Discussion

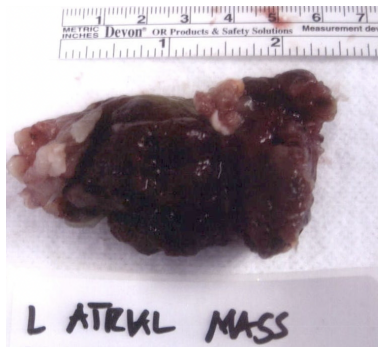
Cardiac involvement by primary and secondary tumors is one of the least investigated subjects in oncology. Myxomas are the most common type of cardiac tumors. Though mostly benign in nature, they are not without complications. There is evidence in literature that suggests myxomas can lead to cardiovascular and neurologic complications [7]. A single myxoma in the left atrium has the propensity to cause systemic embolization in 29% [7] of the patients. Consequently, the presence of multiple myxomas may lead to a higher risk of developing an embolization event such as a stroke. Although myxomas occur most commonly in adults ages 30 to 60, the patient was a 23 year old healthy male. This may be due to the fact that the patient had biatrial myxomas, which increased his likelihood of having neurologic complications at a younger age. Most cardiac tumors are caught in infancy, and intervention is provided at that time. For adults, there are no current screening methods for myxomas. Consequently, myxomas, although rare, are an important differential to have for young adults presenting with neurologic and/or cardiovascular symptoms.

Cardiac myxomas are mostly sporadic thought to arise from a combination of genetic and environmental factors. There is a small incidence of around 7% of myxomas that may be considered a familial and/or genetic correlation. Carney complex is an inherited, autosomal dominant disease characterized by cutaneous pigmentation abnormalities, cardiac and extracardiac myxomas, and endocrinopathies (10 - cite). This disease is transmitted through a mutation in the PRKAR1 alpha gene located on chromosome 17. The patient presented in this case is a healthy 23-year-old male who previously did not have any symptoms that would otherwise explain his clinical state. He was at work when his coworkers noted that the patient was slurring his words and had severe weakness on his right side. A thorough review of his past

medical history did not suggest possible genetic mutation as the cause of the myxomas. The patient did not have family members with cardiac tumors, or other cardiac or neurological problems. This suggests a sporadic development of the biatrial myxomas, with possible contributing environmental factors of chronic inflammation or infection (11-cite). Further research is required to explore the correlations between environmental contribution to a genetic predisposition for myxomas.

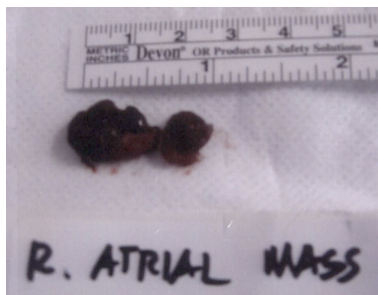Prompt surgical resection of myxomas is the treatment of choice once the tumor(s) is identified. Cardiology and cardiothoracic surgery should be consulted, and the patient should have a thorough cardiac workup to determine the best course of action in a timely manner. Our patient arrived within the window for receiving tPA and was able to undergo a thrombectomy for his stroke. However, it is important to note that anticoagulation and antiplatelet is not considered an alternative to surgery due to a high incidence of stroke that develop in patients with myxomas placed on these medications for bridging to surgery (13- cite). Postoperative recovery following myxoma resection is usually rapid, as was the case with our patient. Myxomas may recur following its resection in about 2 to 5% of cases usually due to incomplete resection of the tumor or having an inherent genetic predisposition (12 - cite). Patients who have early development of myxomas, atypical myxoma location or whose primary tumor was multicentric have a high risk for development of recurrent myxomas. For our patient, it is important to keep a close postoperative follow up with himself and screening of his family for prevention of serious neurologic and cardiovascular complications, including sudden death. Analysis of the genetic composition of families with myxomas may also yield additional information regarding its risk factors.

**Image A:**



Size: 4x6 cm

**Image B:**



Size: 1 x 2 cm

Acknowledgements:

None

Conflicts of Interest Statement:

We declare no competing interests.

Funding:

We declare no funding was applied

Ethics approval and consent to participate

Not applicable

Consent:

Written informed consent was obtained from the patient to publish this report in accordance with the journal's patient consent policy.

Patient's name is not mentioned in this case report.

Guarantor

Harnek Singh, MD.

## References:

1. Lam KY, Dickens P, Chan AC. Tumors of the heart. A 20-year experience with a review of 12,485 consecutive autopsies. *Arch Pathol Lab Med*. 1993 Oct;117(10):1027-31. PMID: 8215825
2. Pucci A, Gagliardotto P, Zanini C, Pansini S, di Summa M, Mollo F. Histopathologic and clinical characterization of cardiac myxoma: review of 53 cases from a single institution. *Am Heart J*. 2000 Jul;140(1):134-8. doi: 10.1067/mhj.2000.107176. PMID: 10874274.
3. Kuon E, Kreplin M, Weiss W, Dahm JB. The challenge presented by right atrial myxoma. *Herz*. 2004 Nov;29(7):702-9. doi: 10.1007/s00059-004-2571-7. PMID: 15580325.
4. Keeling IM, Oberwalder P, Anelli-Monti M, Schuchlenz H, Demel U, Tilz GP, Rehak P, Rigler B. Cardiac myxomas: 24 years of experience in 49 patients. *Eur J Cardiothorac Surg*. 2002 Dec;22(6):971-7. doi: 10.1016/s1010-7940(02)00592-4. PMID: 12467822.
5. ElBardissi AW, Dearani JA, Daly RC, Mullany CJ, Orszulak TA, Puga FJ, Schaff HV. Analysis of benign ventricular tumors: long-term outcome after resection. *J Thorac Cardiovasc Surg*. 2008 May;135(5):1061-8. doi: 10.1016/j.jtcvs.2007.10.048. PMID: 18455585.
6. Jelic J, Milicić D, Alfirević I, Anić D, Baudoin Z, Bulat C, Corić V, Dadić D, Husar J, Ivančan V, Korda Z, Letica D, Predrijevac M, Ugljen R, Vućemilo I. Cardiac myxoma: diagnostic approach, surgical treatment and follow-up. A twenty years experience. *J Cardiovasc Surg (Torino)*. 1996 Dec;37(6 Suppl 1):113-7. PMID: 10064362.
7. Salm, T. V. (2022, April 19). *Cardiac tumors*. UpToDate. Retrieved September 21, 2022, from [https://www.uptodate.com/contents/cardiac-tumors?search=cardiac+tumors&source=search\\_result&selectedTitle=1~150&usage\\_type=default&display\\_rank=1#references](https://www.uptodate.com/contents/cardiac-tumors?search=cardiac+tumors&source=search_result&selectedTitle=1~150&usage_type=default&display_rank=1#references)
8. Azari A, Moravvej Z, Chamanian S, Bigdelu L. An unusual biatrial cardiac myxoma in a young patient. *Korean J Thorac Cardiovasc Surg*. 2015 Feb;48(1):67-9. doi: 10.5090/kjtc.2015.48.1.67. Epub 2015 Feb 5. PMID: 25705602; PMCID: PMC4333846.
9. Reeder GS, Khandheria BK, Seward JB, Tajik AJ. Transesophageal echocardiography and cardiac masses. *Mayo Clin Proc*. 1991 Nov;66(11):1101-9. doi: 10.1016/s0025-6196(12)65788-7. PMID: 1943240.
10. MacGowan SW, Sidhu P, Aherne T, Luke D, Wood AE, Neligan MC, et al. Atrial myxoma: national incidence, diagnosis and surgical management. *Ir J Med Sci* 1993;162(6):223-6.
11. Jantuan E, Chiu B, Chiu B, Shen F, Oudit GY, Sergi C. The tumor microenvironment may trigger lymphoproliferation in cardiac myxoma. *Transl Oncol*. 2021 Jan;14(1):100911. doi: 10.1016/j.tranon.2020.100911. Epub 2020 Oct 23. PMID: 33129111; PMCID: PMC7586245.

12. McCarthy PM, Piehler JM, Schaff HV, Pluth JR, Orszulak TA, Vidaillet HJ Jr, et al. The significance of multiple, recurrent and “complex” cardiac myxomas. *J Thorac Cardiovasc Surg* 1986;91:389-96
13. Stefanou MI, Rath D, Stadler V, Richter H, Hennersdorf F, Lausberg HF, Lescan M, Greulich S, Poli S, Gawaz MP, Ziemann U, Mengel AM. Cardiac Myxoma and Cerebrovascular Events: A Retrospective Cohort Study. *Front Neurol*. 2018 Oct 3;9:823. doi: 10.3389/fneur.2018.00823. PMID: 30337904; PMCID: PMC6178925.

Cardiac myxomas are the most common primary noncancerous neoplasms found in the heart. Most cardiac myxomas arise in the left atrium and the rest much less frequently from the mitral valve, right atrium and occasionally from the ventricles. Biatrial cardiac myxomas are extremely rare, as the reported incidence is less than 2%. This report highlights a young 23-year-old, previously healthy male who presented with a cerebrovascular accident likely secondary to biatrial myxomas that were incidentally found during the stroke evaluation.