

Ashraf ALAkkad¹

¹Affiliation not available

October 6, 2022

Abstract

A 22 year old adult male shifted from Congo 2 months ago presented to the Emergency Department with complaints of having a fever for the last three weeks. The fever was associated with chills and sweating, and occasional dizziness. Two weeks later, the man developed a cough, which was productive and caused him to develop shortness of breath with its onset. The patient's overall condition rendered him appetite less, with a poor-quality oral intake of food and fluids. His COVID19 PCR came out negative, and he had no contact with a positive patient. Further history revealed that the patient had developed Malaria a long time ago and was prophylactically treated for it. He is a non-smoker yet occasionally drinks alcohol. His chest x-ray revealed patchy consolidations in the middle and lower zones of the left lung, whereas the chest CT revealed mediastinal lymphadenopathy and air bronchograms. His sputum for AFB and Rapid



HIV-ASSOCIATED TUBERCULOSIS

Ashraf Al Akkad

Internal Medicine department, Madinat Zayed Hospital, UAE

***Corresponding Author:**

Ashraf Al Akkad

Internal Medicine department, Madinat Zayed Hospital, UAE

Type of Publication: Case Report

Conflicts of Interest: Nil

Abstract

A 22 year old adult male shifted from Congo 2 months ago presented to the Emergency Department with complaints of having a fever for the last three weeks. The fever was associated with chills and sweating, and occasional dizziness. Two weeks later, the man developed a cough, which was productive and caused him to develop shortness of breath with its onset. The patient's overall condition rendered him appetite less, with a poor-quality oral intake of food and fluids. His COVID19 PCR came out negative, and he had no contact with a positive patient. Further history revealed that the patient had developed Malaria a long time ago and was prophylactically treated for it. He is a non-smoker yet occasionally drinks alcohol. His chest x-ray revealed patchy consolidations in the middle and lower zones of the left lung, whereas the chest CT revealed mediastinal lymphadenopathy and air bronchograms. His sputum for AFB and Rapid Mycobacterium PCR came positive, after which he was admitted to isolation and maintained on Anti-TB drugs. The patient was also sexually active with a girlfriend and also had oral thrush for which his respective tests for CAP, including x-ray chest, sputum culture and PCR test for HIV/AIDS were ordered, and they came out to be positive. This patient was suspected of suffering from HIV-associated tuberculosis. The coexistence of tuberculosis and HIV infection among the people has posed a serious threat to the human race for a long time. HIV is seen to be correlated with tuberculosis in those particular areas where either of the diseases are seen to be among the high burden diseases. HIV-associated tuberculosis was seen to greatly contribute to the morbidity and mortality of the affected patients, considering there was also insufficiency of resources and treatment facilities available for immediate treatment. This paper reviews the background of HIV-associated tuberculosis and the diagnostic criteria of the disease and reflects on the available treatment plans that simultaneously work to reduce the burden of the disease.

Keywords: HIV/AIDs, AFB, Tuberculosis, CAP

Introduction

Tuberculosis is considered to be one of the most prevalent and common opportunistic infections to present in patients suffering from HIV infection. There is a 4.6/100 patient-year incidence rate of developing tuberculosis in HIV-infected patients.¹

During the entire course of HIV, approximately 70% of the affected individuals develop one or another form of respiratory illness. Moreover, these

pulmonary complications are not only common but also seen to be increasing in incidence over the years.

In these patients, it was also noticed that the CD4 cell counts decreased to up to 200 cells/mm³ as the disease or the symptoms progressed.²

In these circumstances, the timely diagnosis and immediate treatment protocols have been seen to govern a favorable outcome in such patients. Moreover, the spread of the disease forward to other

unaffected people and also other HIV patients could also be prevented through early diagnosis.

The clinical diagnosis of patients suffering from pulmonary tuberculosis especially remains a challenge in clinical settings. The reason for this is the increased prevalence of negative sputum smear tests in these patients.

Furthermore, a good majority of these patients present with extrapulmonary symptoms. The radiological features are also often seen to not comply with the anticipated findings in the HIV-affected patients.

In such patients, two modes of diagnostic testing are preferred: eligibility for Isoniazid preventive therapy and also chest radiography, which is also seen to be the cornerstone of diagnosis in many patients. Despite the confusions that are encountered during HIV infections associated with chest complications, there are several characteristic features that prove to be of diagnostic value when combined with the detailed history and physical findings and examination of the patient.³

Tuberculosis was seen to present with upper lung infiltrates accompanied with consolidations or patchy areas, or often with lower and middle zone consolidation that often get misdiagnosed for bacterial pneumonia.⁴

Other findings such as pleural effusion, adenopathy, cavitation elsewhere are also encountered, but in these cases, the diagnosis relies upon the other findings, such as a decreased CD4 cells, which is exactly what was seen in the presented patient from Congo that leads to the diagnosis of HIV-associated tuberculosis in this patient.

Case Report

A young male patient who had recently shifted from Congo was presented to the Emergency Department. This male patient was previously healthy and normal and had encountered no such symptoms as he had previously.

This patient had a complaint of suffering from fever, associated with chills, dizziness, and sweating for three weeks. His appetite had been lost, and he was also facing difficulty in intaking either foods or fluids from the oral route.

Moreover, the patient also developed a productive cough, often accompanied by breathlessness for two weeks. COVID history and testing were both negative.

The patient was sexually active back in Congo. His lab reports were ordered, which revealed that the ECG findings were normal, showing no abnormality.

However, the chest X-ray and CT-Scans were not so favorable. They revealed that the patient had consolidations in the lower and middle zones of the left lung, same as bacterial pneumonia, as pointed out earlier. There was middle and lower consolidation in the right lung, accompanied by air bronchograms.

Mediastinal lymphadenopathy was also noted, which, consistent with the persistent fever history, was favorable for the appropriate diagnosis in the patient.

The patient was immediately admitted to isolation, after which his AFB sputum culture was ordered, which isolated *Mycobacterium* complex (*M. tuberculosis*, *M. africanum*, *M. Bovis*, *BCB*, *M. microti*, and *M. pinnipedii*).

The patient's rapid *Mycobacterium* PCR test was also found to be positive, thus favoring the confirmed diagnosis for tuberculosis in this patient. The sexually active history in this male patient prompted a test for suspected HIV infection, which in turn, came out to be positive as well.

Diagnosis

Fever with chills and sweating, mediastinal lymphadenopathy, appetite loss, persistent productive cough for two weeks are positive signs of active tuberculosis infection. The positive culture, low CD4 cell counts, and consistent findings in the chest X-ray and CT scans were hallmarks of tuberculosis. The positive sexual history with a resultant HIV-positive test for further correlations confirmed that the patient suffered from HIV-associated tuberculosis.

The background of the patient was from Congo. HIV-associated tuberculosis is considered to be a prevalent disease in the Democratic Republic of Congo.⁵

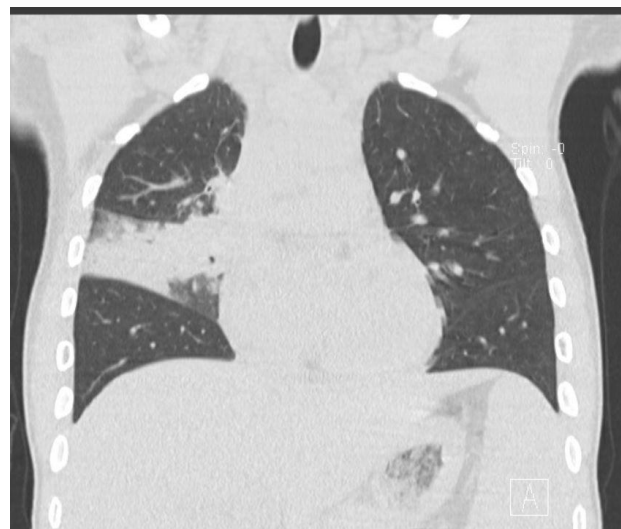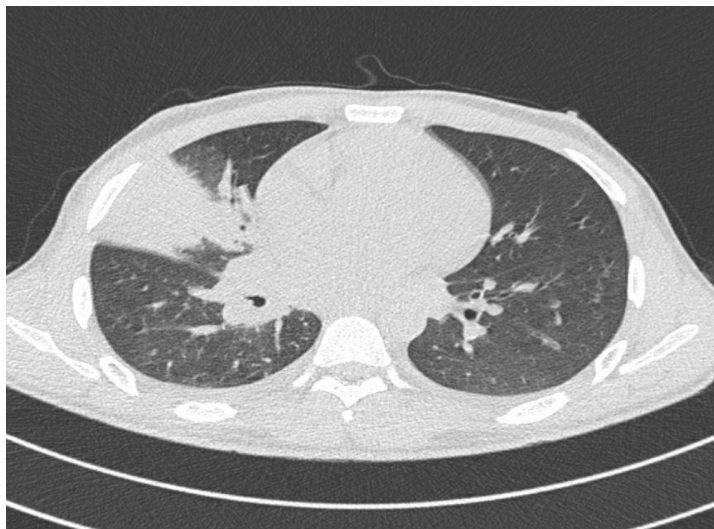


Figure 1.

CT chest showed middle and lower consolidation in the right lung, accompanied by air bronchograms

Management Plan

The patient was promptly admitted to an isolation ward to contain the infection. Simultaneous Anti-TB Therapy (Isoniazid, Pyrazinamide, Ethambutol, Rifampicin, Pyridoxine) and HIV medication (Emtricitabine/Tenofovir, and Dolutegravir), along with Sulfamethoxazole-Trimethoprim was started.

During the entire course of treatment of 40 days, the patient was repeatedly tested for AFB cultures. He was not let out of the isolation until three negative culture samples were reported.

Discussion

Background

Tuberculosis has been a great challenge for humanity for a long while. Patients suffering from *Mycobacterium tuberculosis* pose a significant burden on patient morbidity and mortality in a given area.

The correlation of Tuberculosis and AIDS being diagnosed together has become a significant source of disease burden, especially in those areas where the disease is found to occur as an endemic disease.

Both HIV and Tuberculosis and now HIV-associated tuberculosis have become potentially epidemic diseases in the Democratic Republic of Congo.

Epidemiology

Tuberculosis (TB) is among the leading infectious diseases in the world. However, approximately 14-15 million people are seen to suffer from a dual infection of HIV/AIDS and TB. Therefore, it is better to say that TB is one of the leading opportunistic infections that cause death in patients suffering from HIV/AIDS.

75-80% of these HIV-associated tuberculosis cases were prevalent in India, Kenya, Mozambique, Nigeria, South Africa, Ethiopia, United Republic of Tanzania, Uganda, Zambia, and Zimbabwe.⁶

Clinical Features

The clinical picture of classic HIV-associated tuberculosis often resembles that of post-primary pulmonary tuberculosis. The sputum smear is most often positive, whereas, in severely immunocompromised patients, the clinical picture could be the complete opposite.

Severely immunocompromised patients may present a clinical picture consistent with symptoms of primary tuberculosis, with a negative sputum smear test and atypical chest x-ray findings.

Usually, patients suffering from HIV-associated tuberculosis display bilateral or unilateral lung infiltrates, pleural effusion, cavitation, and fibrosis.

The CD4 cell count was also found to vary in these patients. Some patients had lower than 200 cells/mm³, whereas others had higher than this value.

Diagnosis

Chest radiography is considered to be the hallmark for diagnosing this disease. Even though it has been proven that the chest radiographs may vary in terms of their features from patient to patient, a detailed medical history along with the other factors noted in the history (family history, social history, previous medical history) could all contribute towards elucidating the exact cause that has been causing the said abnormalities in a given patient.

Apart from these, sputum cultures and HIV workup have proven to be immensely helpful in further confirming the diagnosis in suspected cases like these.

Management

Several recommended therapy regimens exist for the treatment of HIV/AIDS, tuberculosis, and coexistent infections.

The first-line treatment regimen for HIV/AIDS begins with opting for a nucleoside reverse transcriptase inhibitor. In contrast, TB begins with opting for the standard four-drug regimen (Isoniazid, Ethambutol, Rifampicin, Pyrazinamide) for two months and later on alternating it with two (Isoniazid and Rifampicin) for the next four months. The treatment is highly selective and varies from patient features to patient features, along with their intensity.

Conclusion

HIV-associated tuberculosis is a major problem in some of the epidemic areas of the world. It may arise unexpectedly, but the long and tedious treatment course could often make the patient withdraw from their treatment well before time.

It is because of reasons like these that it is preferred that routine testing be carried out in all these regions where the disease poses a threat to the people and where controlling the disease once it is diagnosed is

not possible due to the lack of resources and facilities.

References

1. Naidoo, K., Naidoo, K., Padayatchi, N., & Abdool Karim, Q. (2011). HIV-Associated Tuberculosis. *Clinical & developmental immunology*, 2011, 585919. <https://doi.org/10.1155/2011/585919>
2. Padyana, M., Bhat, R. V., Dinesha, M., & Nawaz, A. (2012). HIV-Tuberculosis: A Study of Chest X-Ray Patterns in Relation to CD4 Count. *North American journal of medical sciences*, 4(5), 221–225. <https://doi.org/10.4103/1947-2714.95904>
3. Getahun, H., Gunneberg, C., Granich, R., & Nunn, P. (2010). HIV infection-associated tuberculosis: the epidemiology and the response. *Clinical infectious diseases : an official publication of the Infectious Diseases Society of America*, 50 Suppl 3, S201–S207. <https://doi.org/10.1086/651492>
4. Yarchoan, R., Mitsuya, H., & Broder, S. (1988). AIDS therapies. *Scientific American*, 259(4), 110–119.
5. Wembonyama, S., Mpaka, S., & Tshilolo, L. (2007). Médecine et santé en République Démocratique du Congo: de l'Indépendance à la 3e République [Medicine and health in the Democratic Republic of Congo: from Independence to the Third Republic]. *Médecine tropicale : revue du Corps de santé colonial*, 67(5), 447–457.
6. Bruchfeld, J., Correia-Neves, M., & Källenius, G. (2015). Tuberculosis and HIV Coinfection. *Cold Spring Harbor perspectives in medicine*, 5(7), a017871. <https://doi.org/10.1101/cshperspect.a017871>