

Intra-abdominal Lymphatic Malformations: A Case Series

Joseph G. Brungardt¹, Jo Cooke-Barber¹, Greg Tiao¹, Adrienne M. Hammill², Kiersten Ricci², Manish Patel¹, and Roshni Dasgupta¹

¹Cincinnati Children's Hospital Medical Center

²Cincinnati Children's Hospital Medical Center Cancer and Blood Diseases Institute

September 8, 2022

Abstract

Background: Intra-abdominal lymphatic malformations are rare entities without a clear consensus on management or prognosis. These malformations are medically and surgically complex and often require a sophisticated, multi-disciplinary approach to treatment. **Methods:** A single quaternary institutional, retrospective chart review between January 2000-December 2019 was performed on all patients with an initial diagnosis of a non-solid organ intra-abdominal lymphatic malformation. Demographics, presentation, treatment, and outcome were reviewed. **Results:** 24 patients were identified, 62.5% were male. Median age at time of diagnosis was 2.5 years old, 33% were present at birth, 50% presented before 2 years old, and 29% presented [?]10 years of age. 75% were lymphatic (majority macrocystic), 20.8% were mixed lymphatic-venous malformations (LVM). 54% had other associated lymphatic or vascular malformations including 4 patients with PIK3CA-Related Overgrowth Spectrum (PROS), 3 with Generalized Lymphatic Anomaly, and 2 with Capillary Venous Lymphatic malformation (CVLM). Patients most often presented with abdominal pain (50%). 95.8% required an intervention. 87.5% were managed initially with sclerotherapy. Most interventions were performed for abdominal symptoms either before three years of age or during adolescence. 41.7% underwent laparoscopic or open surgery. 8.3% underwent surgery as their primary therapy. **Conclusion:** Intra-abdominal lymphatic malformations have a bimodal distribution pattern of presentation; shortly after birth and again at puberty. Most patients present with abdominal symptoms and have other associated vascular anomalies. MRI appears to be the most accurate modality for treatment planning. Interventional procedures such as sclerotherapy and medical therapy with sirolimus are safe and effective and should be considered first line therapies. Surgical resection is often required when the diagnosis is in question or when more conservative therapies are no longer efficacious.

1. Introduction

Intra-abdominal vascular malformations are rare entities, reported in the literature to have a 1% incidence, with the true incidence likely higher given small asymptomatic lesions.¹⁻³ There are three general types of vascular malformations which are seen in non-solid organs of the abdomen which include venous, lymphatic, arteriovenous, and combinations such as lymphatic-venous malformations.⁴ Lymphatic malformations (LM) occur during embryonic development as a result of abnormally formed lymphatic vessels and represent the most common form of low-flow, non-solid organ, intra-abdominal vascular malformation.^{1,4}

Intraabdominal lymphatic malformations (ILM) are medically and surgically complex and require a sophisticated, multi-disciplinary approach to treatment. There are no consensus guidelines on the management or prognosis of these lesions. Recent studies have demonstrated that though LM are rare entities, both inpatient charges and resource utilization as well as mortality are on the rise for patients with lymphatic malformations.⁵ Intraabdominal lymphatic malformations have a known association with other vascular malformations, especially those involving the trunk. Patients with CLOVES syndrome (Congenital lipomatous overgrowth, vascular malformations, epidermal nevi, and scoliosis/skeletal/spinal anomalies syndrome), a PIK3CA related overgrowth syndrome (PROS), frequently manifest with involvement/features on the flanks

or abdomen.^{4,6} Sirolimus therapy has been used to treat PROS and has demonstrated safety and efficacy, though it is accepted that it does not cause shrinkage of the malformations, but rather stabilizes them and reduce symptoms including pain.^{4,7-10} The purpose of this study was to investigate the natural history and clinical course of this disease process including required and delivered therapies and treatments.

2. Methods

A retrospective chart review was performed at a single quaternary institution. Patients with a diagnosis of intra-abdominal vascular malformation treated at Cincinnati Children's Hospital Medical Center Hemangioma and Vascular Malformations Center between January 2000 and December 2019 were included. Patients with an initial diagnosis of non-solid organ intra-abdominal lymphatic malformation were included. Isolated solid organ malformations such as those patients with pancreatic, splenic, liver, or bowel were excluded for the purposes of this study. Data was collected on demographics, presentation, treatment and outcomes, and follow-up.

3. Results

3.1 Demographics

Twenty-four patients with intra-abdominal lymphatic malformations were identified. Fifteen patients, 62.5%, were male, and the remaining 37.5% (n=9) were female. The median age at time of diagnosis was 2.5 (SD 6.19) years (range 0 – 17 years). Seven cases, 29%, were present at birth, 50% present (n=12) before 2 years old, and 29% (n=7) presented in patients older than 10 years. The ages at presentation created a bimodal distribution pattern (Fig. 1). Notably, the peak presentations appear before 2 years old and over 10 years old. The majority, 75% (n=18) were Caucasian, with 12.5% (n=3) African American and 8.3% (n=2) Hispanic. Most patients were privately insured (58.3%, n=14). See Table 1 for further demographic details of the population.

3.2 Malformation Characteristics

Primarily lymphatic malformations, and lymphatic-venous malformations were noted in this study group.² Eighteen (75%) were lymphatic malformations (LM), 20.8% (n=5) were mixed lymphatic-venous (LVM). The majority of the LM in our patient population were primarily macrocystic (n=18, 75%) with 20.8% (n=5) being mixed macro-microcystic and one (4.2%) primarily microcystic (Table 2).

One patient with presumed LVM based on imaging was ultimately found to have extra-osseous Ewing's Sarcoma of the abdomen. CT and MRI were consistent with LVM of the mesentery with multiple macrocysts as well as microcystic features. However, fluid from the sclerotherapy procedure was sent for cytology and noted to be consistent with Ewing's sarcoma.

3.3 Clinical Features

Thirteen patients, 54.2%, had other lymphatic or vascular malformations including 4 patients with PROS, 3 with Generalized Lymphatic Anomaly (GLA), 2 with Capillary Venous Lymphatic malformation (CVLM), and 4 with other lymphatic malformations. Twelve patients, 50%, presented with abdominal pain, 20.8% were discovered incidentally on screening imaging, 16.7% presented with abdominal distension, rectal bleeding, or a palpable abdominal mass, and one was diagnosed incidentally during an inguinal hernia repair.

All patients in our study underwent some form of imaging to either confirm or diagnose ILM. Ultrasound and computed tomography scan were often performed, typically used in order to work up a patient with abdominal signs or symptoms or as part of a workup for another issue (i.e., trauma work up). Once an intra-abdominal malformation was identified, MRI was utilized in all patients as the primary modality of imaging for more complete evaluation of the ILM, surveillance, and treatment and intervention planning.

3.4 Management

Of the twenty-four patients, 23 (95.8%) required an intervention at some point during their clinical course. Twenty-one, 87.5%, were managed initially with sclerotherapy. Most interventions were performed for ab-

dominal symptoms before 3 years old or during adolescence. Ten patients (41.7%) underwent laparoscopic or open surgery. Two patients (8.3%) underwent surgery as their primary therapy. 13 of 19 patients (68.4%) who underwent sclerotherapy did not require further invasive intervention. Four patients, 21%, received sclerotherapy and then underwent surgical resection for progressive disease. Six patients (25%) were treated with sirolimus at some point during their clinical course.

4. Discussion

Lymphatic malformations are a rare but costly disorder with a recent trend towards higher inpatient costs and resource utilization.⁵ A recent study examining characteristics of inpatients with LM showed more admissions in urban centers and in children under age 3.¹¹ Our series of patients with ILM demonstrated a bimodal distribution. This is consistent with hormonal sensitivity of these lesions as patients demonstrate hormonally driven growth in the first two years of life as well as hormone surges around the onset of puberty.

MRI was the most commonly used form of imaging for the diagnosis of ILM and has been shown to be sensitive and specific for the diagnosis of low-flow ILM.^{1,12} With recent MRI advances, fetal diagnosis is possible.¹³ Ultrasound provides convenient growth monitoring though MRI evaluates the anatomic extent and involvement of the LM respective to other structures.¹⁴ There are three subtypes of lymphatic malformations: macrocystic, microcystic, and mixed macro-microcystic. Macrocystic LM's have cysts >2 cm. Microcystic malformation often appear as a "cluster of grapes" on MRI (Fig. 2).^{1,12}

Most patients presented with mild to moderate symptoms, generally pain, mass, or distension.² 95.8% of our patients needed either sclerotherapy or surgery, with interventional treatment rates ranging from 60-100% similar to other reports.¹⁵ Sclerotherapy was highly effective with only 4 of 16 sclerotherapy patients needing subsequent treatment with laparoscopic or open surgery. Sclerotherapy at our institution is typically image guided by ultrasound and fluoroscopy, the lesion aspirated, fluid collections drained, and doxycycline instilled as the sclerosing agent. Sclerotherapy for intraabdominal vascular malformations has been shown to be safe and effective in previous studies with demonstrated success rates of 96.7% and a low rate of complications.² Success with sclerotherapy on these lesions is characterized by both symptomatic relief and volumetric reduction in size of these lesions and not based on complete radiographic resolution as this is rarely achieved and should not be the goal of therapy.² Sclerotherapy is traditionally known to be more helpful in patients with macrocystic lesions, however, Chaudry, et al. demonstrates the utility of bleomycin as a sclerosing agent for the treatment of microcystic or mixed lesions.¹⁶ One patient who developed a recurrent ILM years after treatment with sclerotherapy underscores the importance for long term management in a multi-disciplinary clinic and a high index of suspicion if recurrent symptoms develop.

Sirolimus has demonstrated both safety and efficacy in multiple studies on the use in patients with PROS and other lymphatic malformations.⁷⁻¹⁰ This therapeutic benefit is believed to be related to sirolimus' ability to inhibit lymphatic vessel invasion and regeneration through the mTor pathway.^{17,18} Twenty-five percent of patients in our study were treated with sirolimus, which plays an important role in the multi-modal treatment of patients with PROS. It was difficult in this study to delineate with certainty if the patients treated with sirolimus required less interventions, however their treatment was aimed toward improvement in symptoms. New medications that also target the mTOR/PIK3CA pathway are on the horizon. BYL719 has shown to have promise in both safety and efficacy and shown relatively dramatic improvement in the size of malformations.¹⁹ It is still in clinical trials and will hopefully be approved for use in the coming years.

Childbearing females may also note exacerbations or enlargement of their vascular malformations during pregnancy. One patient successfully brought two pregnancies to term and developed increase pain in her head and neck lymphatic malformation but did not report any significant increase in symptoms relating to her intraabdominal malformation. Female patients should be counseled to avoid taking exogenous estrogen containing medications as these can worsen symptoms from vascular malformations. Counseling becomes especially important as the patients near puberty and late adolescence, as many are lost to follow up.

One patient in our study was presumed to have mixed macro-microcystic ILM on preoperative MRI, however the surgical pathology returned Ewing's Sarcoma. This underscores the importance of following the patient

and considering surgical resection or at least biopsy should the course of the lesion not follow typical patterns. Rapid growth and changing symptoms should raise suspicion for malignancy.²⁰

Limitations of this study are its retrospective nature as well as the challenge of gathering data from a complex chart review process. Many of our patients are referred from outside facilities including across the country as well as from international centers which may affect our rates of procedures or interventions. There is also a limitation of identifying patients with intraabdominal malformations in a retrospective manner. The ICD-10 codes for vascular malformations are ambiguous and therefore limited the ability to capture all patients that may have met inclusion criteria.

Intra-abdominal vascular malformations have a bimodal distribution pattern of presentation, shortly after birth and at puberty. Half of our patients presented with abdominal signs and symptoms such as abdominal pain, distension, constipation, and nausea which was consistent with presentations reported in existing literature.²¹ Many of our patients had other associated vascular anomalies. Patients with PIK3-CA Related Overgrowth Syndromes, Generalized Lymphatic Anomaly syndrome, and those who have other vascular malformations are at risk for intra-abdominal vascular malformations. There is a population of patients who have isolated intra-abdominal vascular malformations, therefore clinical suspicion and abdominal signs and symptoms should guide the diagnostic work up to rule out ILM. MRI appears to be the most accurate modality for treatment/intervention planning.^{1,12} Interventional procedures such as sclerotherapy and medical therapy with sirolimus can be used with excellent efficacy and should be considered first line therapies. Surgery should not be considered as primary therapy unless the patient develops peritonitis or bowel obstruction. Despite the use of sirolimus, most patients will need an intervention at some point during childhood or adolescence for symptoms related to their ILM. Only one patient in our series was treated with sirolimus alone, the rest requiring some form of procedure. Surgical resection is often required when the diagnosis is in question or when more conservative therapies are no longer efficacious.

Conflict of interest:

The authors have no conflicts of interest.

References

1. Francavilla ML, White CL, Oliveri B, Lee EY, Restrepo R. Intraabdominal Lymphatic Malformations: Pearls and Pitfalls of Diagnosis and Differential Diagnoses in Pediatric Patients. *AJR Am J Roentgenol* . 2017;208(3):637-649. doi:10.2214/AJR.16.17008
2. Madsen HJ, Annam A, Harned R, Nakano TA, Larroque LO, Kulungowski AM. Symptom Resolution and Volumetric Reduction of Abdominal Lymphatic Malformations With Sclerotherapy. *J Surg Res* . 2019;233:256-261. doi:10.1016/j.jss.2018.07.031
3. Alqahtani A, Nguyen LT, Flageole H, Shaw K, Laberge JM. 25 years' experience with lymphangiomas in children. *J Pediatr Surg* . 1999;34(7):1164-1168. doi:10.1016/s0022-3468(99)90590-0
4. Adams DM, Ricci KW. Vascular Anomalies: Diagnosis of Complicated Anomalies and New Medical Treatment Options. *Hematol Oncol Clin North Am* . 2019;33(3):455-470. doi:10.1016/j.hoc.2019.01.011
5. Cheng J, Liu B, Farjat AE, Routh J. The Public Health Burden of Lymphatic Malformations in Children: National Estimates in the United States, 2000-2009. *Lymphat Res Biol* . 2017;15(3):241-245. doi:10.1089/lrb.2017.0009
6. Martinez-Lopez A, Blasco-Morente G, Perez-Lopez I, et al. CLOVES syndrome: review of a PIK3CA-related overgrowth spectrum (PROS). *Clin Genet* . 2017;91(1):14-21. doi:10.1111/cge.12832
7. Adams DM, Trenor 3rd CC, Hammill AM, et al. Efficacy and Safety of Sirolimus in the Treatment of Complicated Vascular Anomalies. *Pediatrics* . 2016;137(2):e20153257. doi:10.1542/peds.2015-3257
8. Hammill AM, Wentzel M, Gupta A, et al. Sirolimus for the treatment of complicated vascular anomalies in children. *Pediatr Blood Cancer* . 2011;57(6):1018-1024. doi:10.1002/pbc.23124

9. Tian R, Liang Y, Zhang W, et al. Effectiveness of sirolimus in the treatment of complex lymphatic malformations: Single center report of 56 cases. *J Pediatr Surg* . 2020;55(11):2454-2458. doi:10.1016/j.jpedsurg.2019.12.021
10. Triana P, Dore M, Cerezo VN, et al. Sirolimus in the Treatment of Vascular Anomalies. *Eur J Pediatr Surg* . 2017;27(1):86-90. doi:10.1055/s-0036-1593383
11. Cheng J, Liu B, Farjat AE, Routh J. National Characteristics of Lymphatic Malformations in Children: Inpatient Estimates and Trends in the United States, 2000 to 2009. *J Pediatr Hematol Oncol* . 2018;40(3):221-223. doi:10.1097/MPH.0000000000001078
12. Akita H, Yamada Y, Ito Y, et al. Retroperitoneal low-flow vascular malformations: characteristic MRI findings correlated with histopathological findings. *Abdom Imaging* . 2015;40(6):1713-1720. doi:10.1007/s00261-014-0319-2
13. Barrera CA, Victoria T, Escobar FA, et al. Imaging of fetal lymphangiectasias: prenatal and postnatal imaging findings. *Pediatr Radiol* . 2020;50(13):1872-1880. doi:10.1007/s00247-020-04673-6
14. Liu YP, Huang YL, Tsai PS, Lin DC, Chen CP. Prenatal diagnosis of abdominal lymphatic malformations. *Taiwan J Obs Gynecol* . 2021;60(1):13-19. doi:10.1016/j.tjog.2020.11.003
15. Elbaaly H, Piche N, Rypens F, Kleiber N, Lapierre C, Dubois J. Intra-abdominal lymphatic malformation management in light of the updated International Society for the Study of Vascular Anomalies classification. *Pediatr Radiol* . 2021;51(5):760-772. doi:10.1007/s00247-020-04930-8
16. Chaudry G, Guevara CJ, Rialon KL, et al. Safety and efficacy of bleomycin sclerotherapy for microcystic lymphatic malformation. *Cardiovasc Interv Radiol* . 2014;37(6):1476-1481. doi:10.1007/s00270-014-0932-z
17. Ricci KW. Advances in the Medical Management of Vascular Anomalies. *Semin Interv Radiol* . 2017;34(3):239-249. doi:10.1055/s-0037-1604297
18. Ozeki M, Nozawa A, Yasue S, et al. The impact of sirolimus therapy on lesion size, clinical symptoms, and quality of life of patients with lymphatic anomalies. *Orphanet J Rare Dis* . 2019;14(1):141. doi:10.1186/s13023-019-1118-1
19. Venot Q, Blanc T, Rabia SH, et al. Targeted therapy in patients with PIK3CA-related overgrowth syndrome. *Nature* . 2018;558(7711):540-546. doi:10.1038/s41586-018-0217-9
20. Scorletti F, Patel MN, Hammill AM, Ricci KW, Myer CM th, Dasgupta R. Sclerotherapy for intramuscular vascular malformations: A single-center experience. *J Pediatr Surg* . 2018;53(5):1056-1059. doi:10.1016/j.jpedsurg.2018.02.040
21. Kosir MA, Sonnino RE, Gauderer MW. Pediatric abdominal lymphangiomas: a plea for early recognition. *J Pediatr Surg* . 1991;26(11):1309-1313. doi:10.1016/0022-3468(91)90607-u

Legends/Figures

Figure 1. Bimodal distribution of age at diagnosis of intra-abdominal lymphatic malformations.

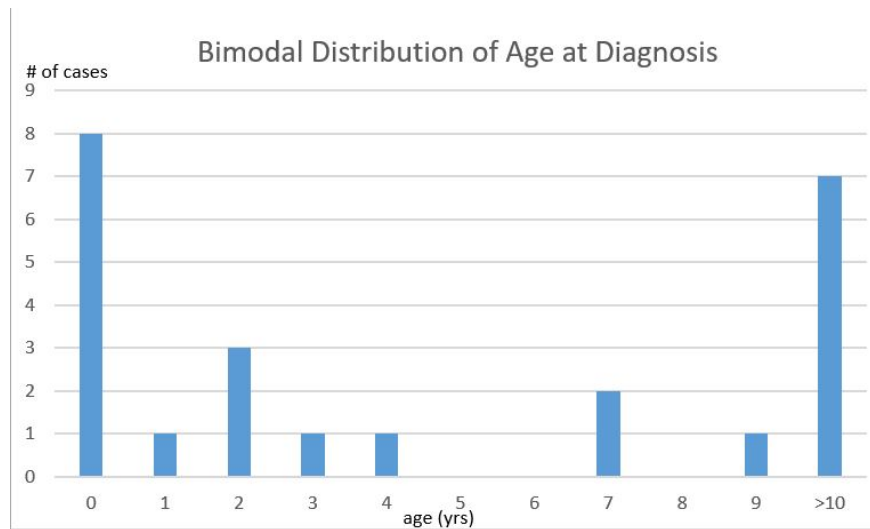


Figure 2. Magnetic resonance imaging of extensive intra-abdominal lymphatic malformation demonstrating both macrocystic and microcystic features.

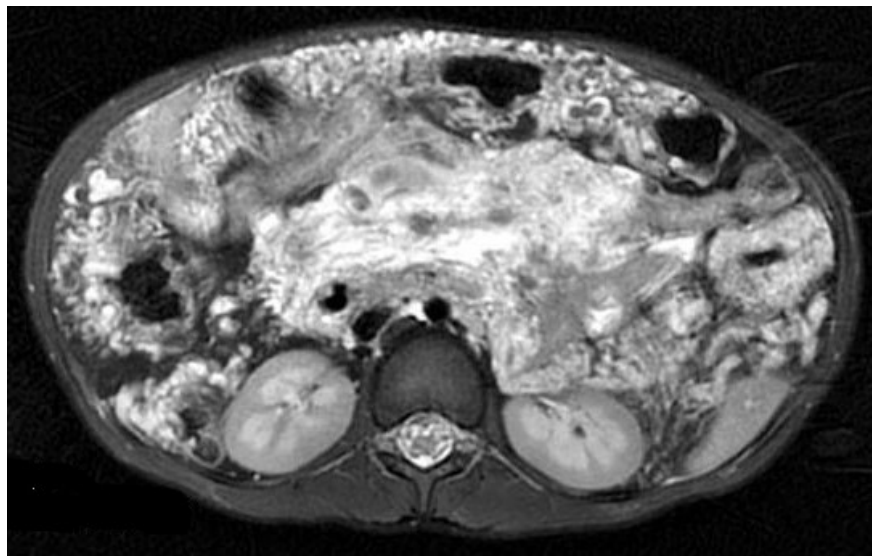


Table 1. Demographics of patients with intra-abdominal lymphatic malformations.

	(n=24) percent
Sex	
Male	(15) 62.5%
Female	(9) 37.5%
Demographics	
White	(18) 75%
Black	(3) 12.5%
Hispanic	(2) 8.3%
Other, non-Hispanic	(1) 4.2%

	(n=24) percent
Payer status	
Private insurance	(14) 58.30%
Public/Medicaid	(9) 37.50%
Uninsured	(1) 4.20%

Table 2. Malformation and therapy data of patients with intra-abdominal lymphatic malformations.

	(n=24) percent
Malformation	
LM	(18) 75%
LVM	(5) 20.8%
Subtype	
Macrocystic Microcystic Mixed (Macro/Microcystic)	(18) 75% (1) 4.2% (5) 20.8%
Presentation	
Abdominal pain	(12) 50%
Screening imaging	(5) 20.8%
Incidental Finding	(1) 4.2%
Other abdominal complaint	(4) 16.7%
Intervention	
Required an intervention	(22) 91.7%
Sclerotherapy	(21) 87.5%
Laparoscopic or open surgery	(10) 41.7%
Surgery as primary/index therapy	(2) 8.3%
Treated with sirolimus	(6) 25%
LM, lymphatic malformation. LVM, lymphatic-venous malformation.	LM, lymphatic malformation. LVM, lymphatic-venous malformation.

