Don´t exclude zebras when you hear hoof beats - a rare case of an isolated flailed P1 segment of the mitral valve

Philipp Patrick Müller[1], Ehab Nooh[1], Michael Weyand[1], and Christian Heim[1]

[1]Friedrich-Alexander-Universitat Erlangen-Nurnberg

July 27, 2022

Abstract

Degenerative mitral valve disease is the most common cause for mitral valve surgery in the United States and Europe. Most commonly, a prolapse of the P2 segment of the mitral valve leaflet leads to an impairment of valve coaptation classified as Carpentier Type II. Here we want to present a rare case of an isolated P1 prolapse, which was successfully repaired in a 53-year old female patient.

Don´t exclude zebras when you hear hoof beats - a rare case of an isolated flailed P1 segment of the mitral valve

Philipp Patrick Müller, M.D.[1], Ehab Nooh, M.D.[1], Michael Weyand, M.D., Ph.D.[1], Christian Heim, M.D., Ph.D.[1]

1 Friedrich-Alexander-University Erlangen-Nuremberg; Department of Cardiac Surgery

Disclosure Statement:

The authors declare that they have no competing interests.

Funding Statement:

University of Erlangen Foundation within the funding program Open Access Publishing.

Corresponding Author:

Philipp Patrick Müller, M.D.

Krankenhausstr. 12

91054 Erlangen

GERMANY

Tel: 0049 9131 85 33319

Fax: 0049 9131 85 32768

Email: philippmueller90@gmx.de

Word count:

750 words.

Ethics approval and consent to participate

Patient signed informed consent related to clinical course; therefore and due to its retrospective nature of the case report, the IRB (Clinical Ethics Committee (CEC) at the University Hospital Erlangen) was waived.

Abbreviations:

CT : Computed tomography

LV-EF : Left Ventricular Ejection Fraction

MV : Mitral valve

MVR : Mitral Valve Regurgitation

Abstract:

Degenerative mitral valve disease is the most common cause for mitral valve surgery in the United States and Europe. Most commonly, a prolapse of the P2 segment of the mitral valve leaflet leads to an impairment of valve coaptation classified as Carpentier Type II. Here we want to present a rare case of an isolated P1 prolapse, which was successfully repaired in a 53-year old female patient.

Introduction:

Mitral valve regurgitation is the second most common valvular lesion requiring treatment in developed countries. Etiology of MVR is typically categorized in degenerative and functional causes [1]. While surgical treatment of functional MVR is controversially discussed, there is a clear indication for surgery in degenerative MVR. Surgical repair strategies are determined by the underlying valve pathology, which makes valve analysis crucial in the operative planning process. A common cause for MVR is a prolapse of the P2 segment, caused by papillary muscle or chordae elongation/rupture or fibromyxomatous changes due to degenerative diseases like Marfan syndrome, Barlow disease or fibroelastic deficiency [2], leading to a coaptation failure due to excess of leaflet motion (Carpentier Type II). The P2 segment is the largest of the three scallops and located centrally. Due to the large surface area and its central location, the P2 segment is more prone to systolic stress, which may be an explanation for the higher frequency of isolated P2 prolapse. Other typical prolapses affect the P3 segment or combined prolapses, also including the anterior segments. Due to its extremely rare propensity for isolated prolapse, Carpentier describes the P1 segment of the mitral valve as an anatomical "reference point" for functional mitral valve analysis [3] which is key for an successful MV reconstruction strategy.

Case Presentation:

Here we present a case of a 53-year-old female patient with MVR. The patient initially presented with symptoms of fatigue, dyspnea and palpitations with a progress of these symptoms over the past 8 weeks before admission to an external cardiology clinic. Physical examination at the time of admission showed a grade 3 systolic murmur at the left parasternal 3rd intercostal space, while blood values showed no abnormalities or signs of systemic inflammation. The patient's history included hypertension, obesity and hypothyreosis. Both transthoracic and transesophageal echocardiographic assessments as well as three-dimensional echocardiography were performed, showing a moderate to severe mitral regurgitation with an eccentric jet due to a prolapse of the posterior leaflet at the P1 segment and a preserved ejection fraction (Figure 1). There were no signs for other valve pathologies. Subsequently coronary artery disease was ruled out by coronary angiography and the patient was then admitted to our cardiac surgery department for minimally invasive mitral valve repair. To complete diagnostics a CT of the aorta was performed to rule out anatomical contraindications for the establishment of cardiopulmonary bypass through the femoral vessels.

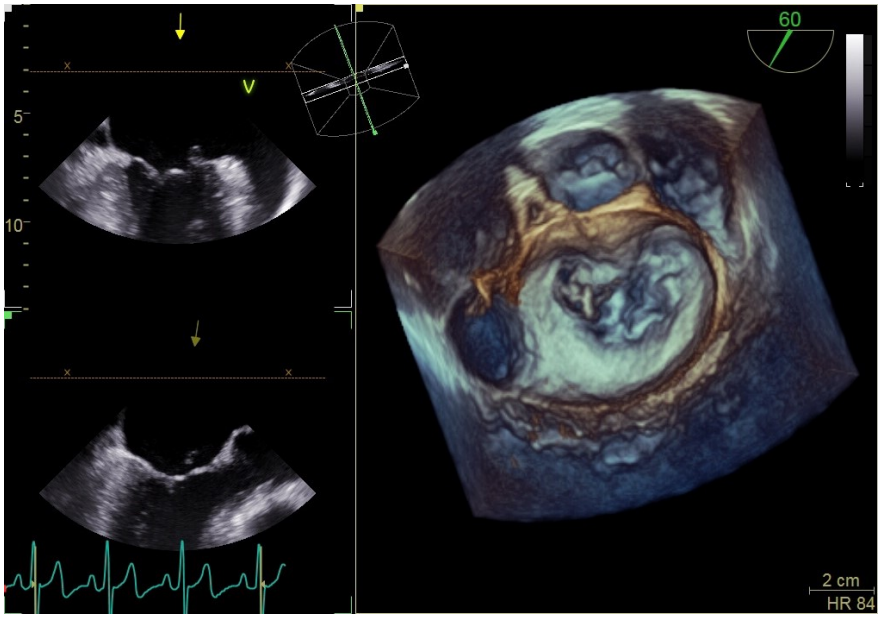

Figure 1: Trans-esophageal-echocardiography with three-dimensional reconstruction (right) showing an isolated prolapse of the P1 segment of the mitral valve

After further pre-operative preparations, the procedure was performed minimally invasive. Cardiopulmonary bypass was established using transcutaneous cannulation of the femoral artery and vein, followed by a 5 cm incision in the fifth intercostal space to gain access to the heart. After the opening of the pericardium and cross clamping with administration of Bretschneider cardioplegia (Custodiol®) into the aortic root, the left atrium was opened to visualize the mitral valve. The intraoperative perspective is shown in Figure 2a.

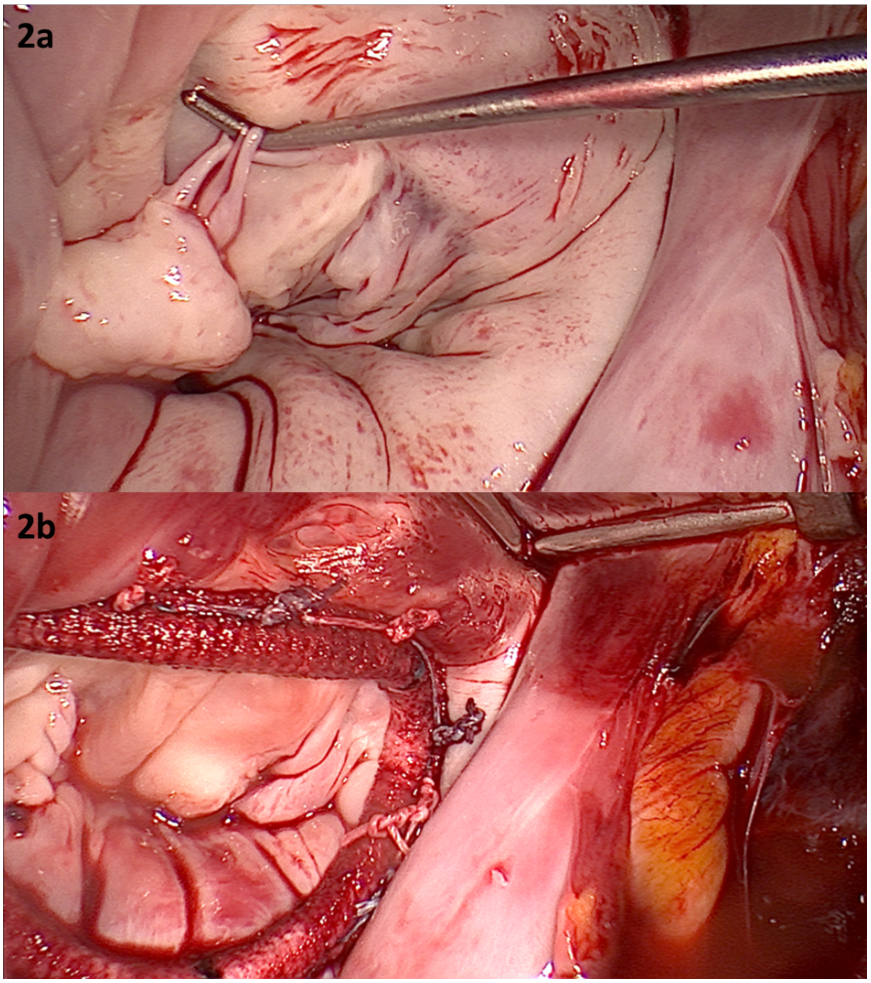

Figure 2: a) P1 segment of the mitral valve and b) Reconstructed mitral valve

When examining the valve we found ruptured primary chordae of only the P1 segment. Therefore, a triangular resection of the prolapsed segment was performed and the scallop was reconstructed with 5-0 cardionyl sutures (Cardionyl® - PETERS SURGICAL). Additionally a downsized 28mm annuloplasty-ring was implanted. To validate the competency of the reconstructed valve an ordeal by water and later with transesophageal echocardiography were conducted, showing satisfying results (Figure 2b).

After the procedure, the patient was transferred to the ICU and extubated on the same day. Further clinical course was uneventful and the patient was discharged home 7 days after surgery.

Discussion:

To our knowledge, an isolated prolapse of the P1 segment of the mitral valve was never described in literature. Due to its extremely rare tendency for prolapse, Carpentier describes the P1 segment of the mitral valve as an anatomical "reference point" for functional mitral valve analysis [3] which is key for a successful MV reconstruction approach. The P2 segment is the scallop mostly affected by prolapse, due to the previously mentioned anatomical conditions. Valve analysis and the underlying valve pathology remain crucial components in the operative planning process of patients with degenerative MVR [4]. Despite being a relatively rare condition, it represents a special challenge losing one of the landmarks that guides the reconstruction. Thankfully in this case it was an isolated pathology which made the valve analysis somewhat straight for-

ward, but imagining this in a complex valve prolapse, it could be easily misleading in the assessment valve height. In the end, common is common, but you may trust your eyes. It could be a zebra when you hear hoof beats coming from behind.

References :

1. El Sabbagh, A., Y.N.V. Reddy, and R.A. Nishimura, Mitral Valve Regurgitation in the Contemporary Era: Insights Into Diagnosis, Management, and Future Directions. JACC Cardiovasc Imaging, 2018.**11** (4): p. 628-643.

2. Le Tourneau, T., et al., Genetics of syndromic and non-syndromic mitral valve prolapse. Heart, 2018. **104** (12): p. 978-984.

3. Wells, F., Carpentier's Reconstructive Valve Surgery. Ann R Coll Surg Engl. 2011 May;93(4):330.

4. Salik, I., L.S. Lee, and J. Widrich, Mitral Valve Repair, in StatPearls. 2022

Figure legends:

Figure 1: Trans-esophageal-echocardiography with three-dimensional reconstruction (right) showing an isolated prolapse of the P1 segment of the mitral valve

Figure 2: a) P1 segment of the mitral valve and b) Reconstructed mitral valve