

Thrombosed ductus arteriosus aneurysm: prenatal diagnosis and perinatal outcome

Ana Mendez¹, Ángel Chimenea², Lutgardo García-Díaz², and Guillermo Antiñolo²

¹Hospital Universitario Virgen del Rocío

²Instituto de Biomedicina de Sevilla

July 13, 2022

Abstract

Ductus arteriosus aneurysm (DAA) is characterized by a saccular or fusiform dilatation of the ductus arteriosus. The formation of a thrombus at that level is infrequent and potentially lethal. We present a case of a fetus with a DAA diagnosed during fetal life by 2-D, 3-D, and 4-D STIC echocardiography. Although a thrombus in the ductus and hypertrophy of the right ventricle was identified in postnatal echocardiography, a conservative approach was adopted with good outcome. The features of our case highlight the importance of serial ultrasound in the fetal and neonatal period to assess fetal aneurysm growth as well as to notice any modification of the flow within.

INTRODUCTION

Improvements in fetal ultrasound have increased the number of congenital ductus arteriosus aneurysm (DAA) reported in the last years, but identifying high-risk aneurysms is today a challenge (1). In most fetuses, DAA is an incidental finding during the third trimester, but earlier diagnosis has been reported (2). The exact pathogenesis remains unclear.

Most fetuses and neonates with DAA and no other associated complications may be asymptomatic and follow a benign course with spontaneous regression (3). However, potential complications may be severe, including thrombosis, compression of adjacent structures, or spontaneous DAA rupture (3). Thrombosis of DAA has been previously reported with severe consequences (2, 4-7). Currently, management of ductus arteriosus thrombosis in fetuses and neonates remains controversial, ranging from a conservative to a surgical approach.

CASE REPORT

A 31-year-old woman, (gravida 1, para 0) was referred to our department at 37 weeks' gestation for evaluation after ultrasound suspicion of coarctation of the aorta. Until that moment the pregnancy was uncomplicated, and the morphological fetal scan at 20 weeks showed no abnormalities. 2-D echocardiography showed an enlarged dilated structure, 14 mm in diameter, that protruded leftward of the aortic arch. 4-D STIC ultrasound showed a turbulent, swirling flow within the aneurysm with no restrictive aspect of the Doppler ductal flow at that time (Figure 1). No other fetal structural anomalies were observed.

A female infant was born at 40 weeks' gestation weighted 3.170 gr, with an Apgar score of 10 and 10 at 1 and 5 minutes respectively. Physical examination was normal. Neonatal echocardiography confirmed the presence of a DAA on the left of the left side of the pulmonary artery (Figure 2). A thrombus was also identified in the ductus (arrow) with hypertrophy of the right ventricle (RV). Follow-up echocardiograms revealed a left-to-right shunt through the ductus, from the aorta to the pulmonary artery, with stability of the thrombus. A conservative approach was adopted with clinical and echocardiographic surveillance with

good outcome and spontaneous ductus closure at 3 days. The infant is now asymptomatic at twenty months of life.

DISCUSSION

This case report characterizes the morphology of a DAA diagnosed during fetal life and complicated by a non-obstructive thrombus. Clinical and echocardiographic follow-up demonstrated a total resolution with an excellent outcome.

Echocardiography is the standard imaging modality used to demonstrate DAA anatomy. In fetal life, the three-vessel view is useful to recognize this entity (8). Typically, a dilated vascular structure is identified protruding leftward of the aortic arch. Color flow Doppler, power Doppler, and pulsed-wave Doppler will help to confirm the diagnosis, to notice the presence of turbulence and to rule out the existence of thrombosis. 3-D and 4-D STIC ultrasound can be useful to verify the entire aneurysm and the ductus shape and contour. (Figure 1B)

Usually, isolated DAA is related to a good fetal and neonatal outcome. However, in some cases, severe complications may be associated with this anomaly (2-7). Thrombosis is one of the potential problems that has been reported in the literature (9,10). It seems to be related to turbulent flow or endothelial injury in the narrowed segment of the ductus (6, 11). The formation of a thrombus at that level with obstruction of fetal circulation can lead to hemodynamic decompensation with hydrops and death (2). In infants, the major complications are mass effect with compression of adjacent structures and thromboembolism with fatal consequences (5-7).

Management of fetuses and neonates with DAA thrombosis is controversial and there is no clear consensus regarding surgical treatment. The indications for anticoagulation and antiplatelet therapy remain unclear (12, 13). Otherwise, the majority of DAA regress spontaneously without ever been diagnosed, some by thrombus and others by constriction and reduction in size (14). Thus, some authors state that obliteration is preceded by thrombus formation, in contrast to other authors who have shown that thrombosis is not necessary for the DA closure in most of the cases (11, 15).

The identification of a small thrombus within the aneurysm during fetal life is challenging. Even though a big clot could be detected as an intravascular echogenic structure, color Doppler and pulsed-wave Doppler are essential to suspect a small thrombus. The diagnosis is based on the detection of incomplete filling of the vascular lumen by color Doppler. In addition, a restrictive pattern of the ductus could be found by pulsed-wave Doppler.

In our case, the transthoracic echocardiogram after birth evidenced a non-obstructive thrombus inside the ductal aneurysm (Figure 2). We speculate that the thrombus formation could be initiated antenatally. Fetal echocardiogram at 37 weeks showed complete filling of the aneurysm, no signs of restrictive ductal flow and stable duct dimensions compared to previous exams (Figure 1C). Unfortunately, the patient did not attend the planned follow up during the last weeks of pregnancy and the possibility of thrombi formation over the last weeks cannot be confirmed. However, thrombi formation could well explain the presence of significant right ventricle hypertrophy at birth secondary to the blood flow obstruction across the arterial duct. Serial echocardiograms after birth demonstrated the quick constriction of the ductus that led to a spontaneous regression without complications. Follow-up echocardiogram at 3 months of life showed a normalization of the right ventricle.

Considering that serious complications have been described after a late diagnosis because of the progression of the anomaly (7), we think that is important to assure a continued echocardiographic follow-up in patients with DAA.

In conclusion, ultrasound plays a key role in the diagnosis and management of DAA. Recognition of this anomaly and surveillance of thrombus development in pregnancy and neonatal period is important to avoid complications. Thus, serial echocardiographic examinations to control the aneurysm size, as well as the blood flow pattern in the ductus arteriosus aneurysm, are critical in follow up.

Author contributions

A.C., L.G., A.M. and G.A. contribute to conception and design. A.M. was responsible to acquisition of data. A.C., L.G., A.M. and G.A. contribute to analysis and interpretation of data. All authors contribute to drafting the article or revising it critically for important intellectual content. All authors contributed to the write up of the manuscript and approved the final version for submission.

FIGURES

Figure 1: Ductus arteriosus aneurysm during fetal life.

Figure 2: Ductus arteriosus aneurysm in the neonatal period.

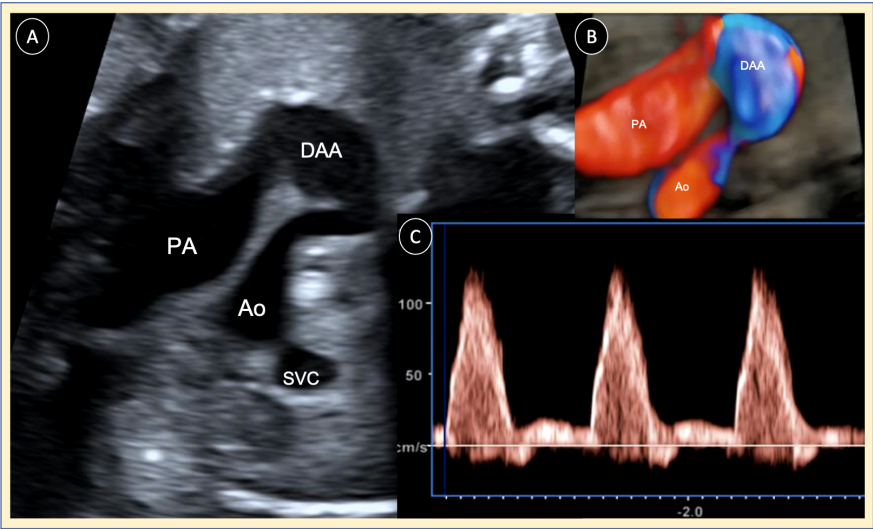
REFERENCES

1. Tseng JJ, Jan SL. Fetal echocardiographic diagnosis of isolated ductus arteriosus aneurysm: a longitudinal study from 32 weeks of gestation to term. *Ultrasound Obstet Gynecol.* 2005;26(1):50-6.
2. Sheridan RM, Michelfelder EC, Choe KA, Divanovic A, Liu C, Ware S, et al. Ductus arteriosus aneurysm with massive thrombosis of pulmonary artery and fetal hydrops. *Pediatr Dev Pathol.* 2012;15(1):79-85.
3. Dyamenahalli U, Smallhorn JF, Geva T, Fouron JC, Cairns P, Jutras L, et al. Isolated ductus arteriosus aneurysm in the fetus and infant: a multi-institutional experience. *J Am Coll Cardiol.* 2000;36(1):262-9.
4. Aly SA, Contreras J, Honjo O, Villemain O. Antenatal occlusion of a ductal arteriosus aneurysm: a potential postnatal surgical emergency. Case report and literature review. *Cardiol Young.* 2020;30(11):1750-2.
5. Ciliberti P, Esposito C, Drago F, Rinelli G. Spontaneous thrombosis of the ductus arteriosus in a newborn, complicated by thrombus migration and massive pulmonary embolism. *Eur Heart J Cardiovasc Imaging.* 2016;17(9):1026.
6. McArdle DJ, Paterson FL, Morris LL. Ductus Arteriosus Aneurysm Thrombosis with Mass Effect Causing Pulmonary Hypertension in the First Week of Life. *J Pediatr.* 2017;180:289.e1.
7. Li H, Wang B, Sun Z, Zhang L, Xie M. Giant Ductus Arteriosus Aneurysm With Thrombus in a 31-Day-Old Infant. *Circ Cardiovasc Imaging.* 2019;12(5):e008939.
8. Jackson CM, Sandor GG, Lim K, Duncan WJ, Potts JE. Diagnosis of fetal ductus arteriosus aneurysm: importance of the three-vessel view. *Ultrasound Obstet Gynecol.* 2005;26(1):57-62.
9. Dworsky M, Kohaut E, Jander P, Ceballos R. Neonatal embolism due to thrombosis of the ductus arteriosus. *Radiology.* 1980;134(3):645-6.
10. Doğan V, Aksoy ÖN, Sayıcı İU, Çitli R. Thrombosis of isolated ductus arteriosus aneurysm in a newborn. *Echocardiography.* 2021;38(4):716-7.
11. Downing GJ, Thibeault DW. Pulmonary vasculature changes associated with idiopathic closure of the ductus arteriosus and hydrops fetalis. *Pediatr Cardiol.* 1994;15(2):71-5.
12. Lund JT, Jensen MB, Hjelms E. Aneurysm of the ductus arteriosus. A review of the literature and the surgical implications. *Eur J Cardiothorac Surg.* 1991;5(11):566-70.
13. Hornberger LK. Congenital ductus arteriosus aneurysm. *J Am Coll Cardiol.* 39. United States 2002. p. 348-50.
14. Oh SJ, Jeung IC. A case of isolated congenital ductus arteriosus aneurysm detected by fetal echocardiography at 38 weeks of gestation. *J Clin Ultrasound.* 2011;39(9):530-3.
15. Fripp RR, Whitman V, Waldhausen JA, Boal DK. Ductus arteriosus aneurysm presenting as pulmonary artery obstruction: diagnosis and management. *J Am Coll Cardiol.* 1985;6(1):234-6.

FIGURES

Figure 1: Ductus arteriosus aneurysm during fetal life.

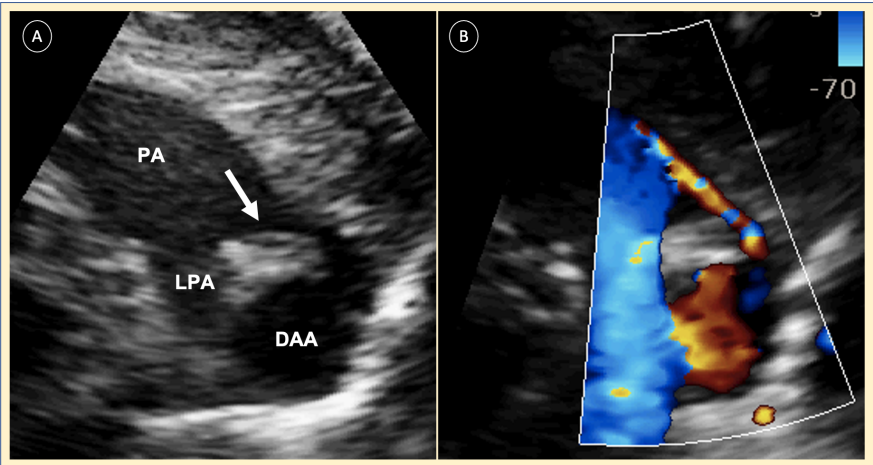
Fetus 37 weeks gestational age, three-vessel view. (A) Two-dimensional echocardiogram demonstrates a ductus arteriosus aneurysm. (B) 4-D STIC ultrasound verifies the ductus shape and contour. (C) Pulsed Doppler in the ductus arteriosus showing a normal Doppler flow at 37 weeks.



Ao, aorta; PA, pulmonary artery; SVC, superior vena cava; DAA, ductus arteriosus aneurysm

Figure 2: Ductus arteriosus aneurysm in the neonatal period.

Neonate 2 days of life, transthoracic echocardiogram, parasternal short-axis view. (A) Two-dimensional echocardiogram demonstrates a small thrombus (arrow) in the narrowed pulmonary duct segment, on the left of the left pulmonary artery. (B) In color-flow Doppler a left-to-right shunt through the ductus was detected, from the aorta to the pulmonary artery.



PA, pulmonary artery; LPA, left pulmonary artery; DAA, ductus arteriosus aneurysm.