

A case report of Bell’s palsy following inactivated COVID-19 vaccination in an adolescent

Manunya Tandhansakul¹, Naruporn Kasemlawan¹, and Tanawat Petrutchatachart¹

¹Chulabhorn Royal Academy

June 8, 2022

Abstract

Bell’s palsy has been reported following COVID-19 vaccination in adults. Here, we report a case of adolescent male with unilateral peripheral facial palsy after receiving BBIBP-CorV vaccine. The diagnosis was confirmed by electrodiagnostic study. The patient had a complete recovery after medical and rehabilitation treatment.

Introduction

Bell’s palsy is an idiopathic facial palsy. It occurs in 20-30 cases per 100,000 people with the highest incidence among adolescents and elderly.⁽¹⁾ Between the ages of 10-20 years, the incidence is approximately 10 cases per 100,000 people. ⁽⁴⁾ The diagnosis is typically made upon a consistent history of rapid onset and unilateral peripheral facial palsy from physical examination. Further investigations are rarely needed unless there are clues toward other possible medical etiology. ⁽¹⁻³⁾ Electrodiagnostic study has been used to predict the prognosis. The study is best performed within 2 weeks after the onset. The best indicators for good prognosis are compound muscle action potential (CMAP) side-to-side determination and the percentage of facial nerve fiber degeneration that does not exceed 90%. ⁽¹⁴⁾ Bell’s palsy is a self-limited condition with a favorable prognosis. Treatment with oral corticosteroids is strongly recommended within 72 hours of onset as the evidence showed significant improvement of facial weakness.^(1,3) Even so, the evidence supporting corticosteroids treatment in children is still controversial. ⁽⁵⁻⁷⁾ Although viral infection, such as Herpes Simplex Virus-1 (HSV-1) or Epstein Barr Virus (EBV), had been proposed to be the etiology. The underlying mechanism of Bell’s palsy remains unknown.^(3,4) However, Bell’s palsy is commonly found following vaccination, especially Influenza vaccine.^(8,9)

Considering the Coronavirus disease 2019 (COVID-19) pandemic, the impacts are detrimental in several aspects, including healthcare system, global economics and mental health. COVID-19 vaccines have become a major role in controlling this pandemic. The aim of vaccination is to decrease the risk of infecting and spreading the virus and to reduce the odds of severe disease and serious complications. There were various adverse events reported following vaccination. According to the COVID-19 Vaccine Adverse Event online reporting system in Hong Kong, there were 33 cases of Bell’s palsy after receiving inactivated (Coronavac) COVID-19 vaccine and 20 cases of Bell’s palsy after mRNA (BNT162b2) vaccine. The incidences of Bell’s palsy following Coronavac and BNT162b2 vaccination are 3.61 per 100,000 doses and 2.04 per 100,000 doses, respectively. ⁽¹⁰⁾ Thus far, mRNA vaccine is the most recommended vaccine for adolescents. Inactivated COVID-19 vaccine is applied only in particular countries. In Thailand, researchers from Chulabhorn Royal Academy have conducted a clinical trial for inactivated BBIBP-CorV (Sinopharm) COVID-19 vaccine in adolescent population age 12-17 years (manuscript in preparation). We studied incidence rate, risk factors and safety after receiving the vaccine. Subsequently, we hereby report a case of adolescent male who developed unilateral peripheral facial palsy after the 1st dose of BBIBP-CorV administration.

Case presentation

On 28 September 2021, A 14-year-old, previously healthy, adolescent male received his 1st dose of inactivated BBIBP-CorV (Sinopharm) COVID-19 vaccine. Five days later, he started to recognize the inability to close his right eye completely. On 11 October 2021, he developed a right facial droop, drooling and worsening of his ability to close his right eye. On that day, his father brought him to the pediatric department. His physical examination demonstrated the inability to raise his right eyebrow, right ptosis, loss of right nasolabial fold and numbness of anterior two-third of tongue, all compatible with right peripheral facial palsy. (Figure 1) His pupillary reflex and other cranial nerve function were intact. His neurological examination was otherwise unremarkable. He had neither pre-existing medical condition nor history of reaction to vaccines. He was diagnosed with Bell's palsy. He was treated with 5-days of oral prednisolone, vitamin B-complex and eye care with artificial tears. Additionally, he was sent to a physiatrist and scheduled for an electrodiagnostic investigation. Apart from the electrodiagnostic test, the patient received no further investigation.

Electrodiagnostic study and Rehabilitation program

The initial nerve conduction study (NCS) and electromyography (EMG) were performed 13 days after the onset of symptom. During the facial nerve stimulation, the active recording was placed on the skin over the right nasalis muscle, the reference electrode placed over contralateral nasalis muscle, and the surface ground electrode placed over his chin.⁽¹³⁾ The physiatrist then applied a handheld bipolar to stimulate the right facial nerve directly at anterior to the tragus. Needle EMG was performed to examine posterior auricular, frontalis, orbicularis oculi, zygomaticus and orbicularis oris muscles.⁽¹⁴⁾ Voluntary motor units were detected in all 5 tested muscles. (Figure2) The CMAP side-to-side determination NCS demonstrated 37% of facial nerve degeneration. (Figure3A) The conclusion was incomplete right facial nerve degeneration (axonopathy). All of which are indicative of a very good prognosis in recovery.

The rehabilitation programs consisted of biostimulation mode of high power laser therapy (MLS®) along right facial nerve and its branches combined with standard physiotherapy, including home electrical stimulation (ES), facial expressive exercise and facial massage. The patient was scheduled for 10 weekly laser therapy sessions. The proper location for Home ES in this patient was just anterior to right tragus, in which the compound action of right facial expressive muscles was observed. During the treatment, this rehabilitation program provided a satisfying outcome. The patient noticed that the numbness of anterior two-third of tongue resolved even before the 2nd high power laser treatment session. After the 6th session, the patient noticed partial recovery of right peripheral facial palsy. He finally reported complete recovery by the end of the 10th session. (Figure4) The physiatrist performed follow-up electrodiagnostic study at the 6th and 10th visit. The percentage of degeneration after 6th and 10th session decreased to 27% and 7%, respectively (Figure 3B and 3C). The patient was closely monitored for facial synkinesis. The condition did not occur throughout the treatment period.

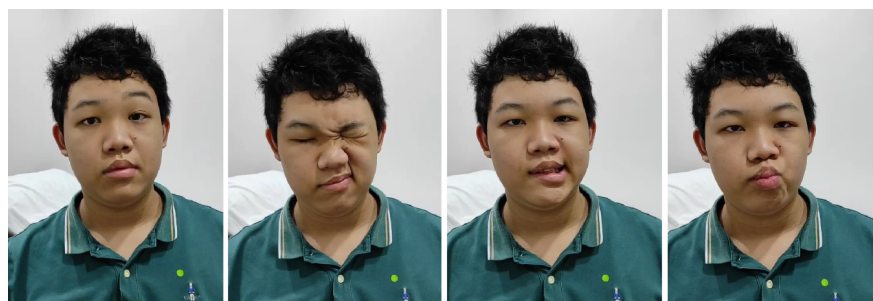

Figure 1 A 14-year-old adolescent with right peripheral facial palsy at 13 days after 1st dose of BBIBP-CorV vaccine (Sinopharm) COVID-19 vaccine

Muscle	Insertion Activity	Spontaneous Activity					Voluntary Activity				Notes
		Fib	PSW	Fasc	CRD	H.F.	Amp (uV)	Dur	Morphology	Recruit	
Right Orbicularis oculi	Increased	0	2+	0	0	0	Normal	Normal	Triphasic	Discrete	
Right Frontalis	Increased	2+	2+	0	0	0	Normal	Normal	Triphasic	Reduced	
Right Orbicularis oris	Increased	0	2+	0	0	1+	Normal	Increased	Complex	Reduced	
Right Zygomaticus	Increased	1+	1+	0	0	0	Normal	Increased	Complex	Discrete	
Right Post auricular	Increased	0	2+	0	0	0	Normal	Normal	Triphasic	-	

Figure 2 Results of electromyography (EMG) conducted in 5 facial muscles.

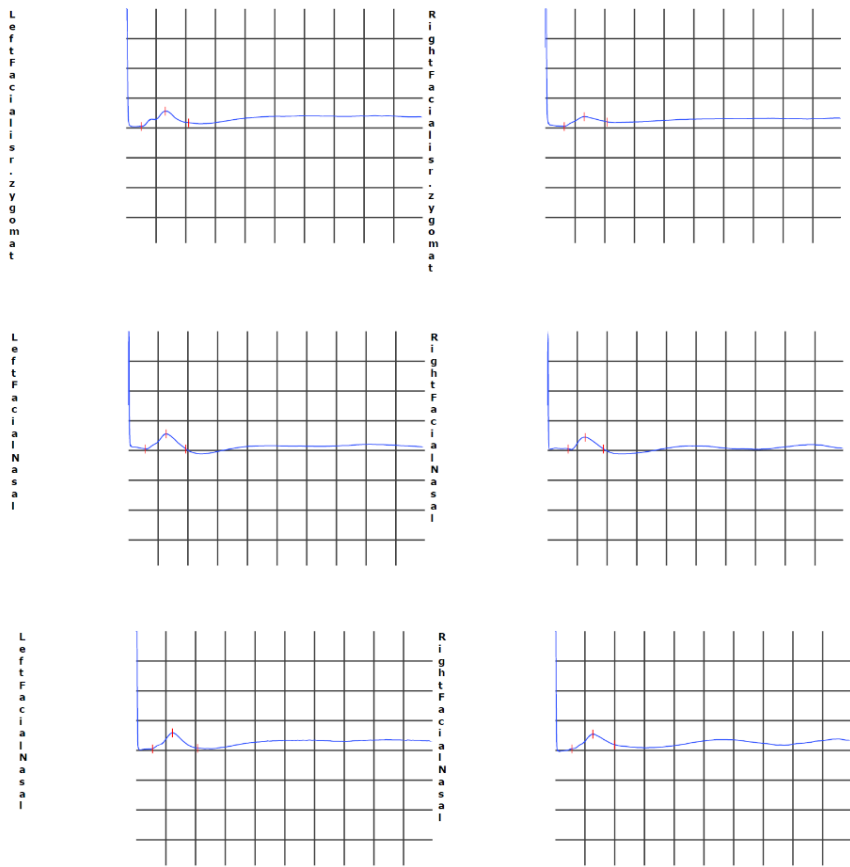


Figure 3 Results from the nerve conduction study (NCV), (3A) The initial study showed 37% degeneration of right facial nerve, (3B) 27% facial nerve degeneration after the 6th session of laser therapy, (3C) 7% of facial nerve degeneration after 10th session.



Figure 4 Complete recovery from right peripheral facial palsy in this patient.

Discussion

Although the underlying mechanism for Bell's palsy is not well-established, the occurrence of such condition after vaccination is not uncommon. In particular, Bell's palsy frequently develops after receiving Influenza vaccine. But the evidence of increased risk of Bell's palsy varies among studies. Some studies demonstrated no evidence of increased risk in both adult and pediatric population.^(8,11) Following both newly developed inactivated and mRNA COVID-19 vaccine, Bell's palsy has been widely reported in adult population older than 18 years of age.^(10,12)

In our study, we reported a case of an adolescent male age 14 years developing unilateral peripheral facial paralysis approximately a week after the 1st dose of inactivated BBIBP-CorV vaccine. The patient had no prior history of possible precipitating factors of Bell's palsy. His neurological examination, besides unilateral peripheral facial palsy, was normal. According to the possibility of Bell's palsy after receiving inactivated vaccine, we concluded that this patient's condition was a potential adverse event from inactivated BBIBP-CorV vaccine. The age of this patient was also compatible with the common age group described in the previous study.^(1,4) Although the benefit of oral corticosteroid is still controversial in pediatric cases⁽⁵⁻⁷⁾, we decided to prescribe a short course of prednisolone to our patient along with a standard eye care. In addition, we consulted for a facial rehabilitation program as we have great rehabilitation facilities in our hospital. After 10 weeks of medical and rehabilitation treatment, the patient had a complete recovery from facial paralysis. This excellent outcome was comparable to the natural history of the disease in conjunction with the positive indicator from the electrodiagnostic study. The percentage of degeneration less than 50% and detection of motor units in at least 4 out of 5 tested muscles indicate satisfying return of function in most patients⁽¹⁴⁾. Both of which were observed in our case, even though the EMG was performed 13 days instead of the recommended 72 hours after the onset. Furthermore, this rapid recovery can be contributed to the application of rehabilitation treatment. Since the laser therapy helps enhancing nerve regeneration and decreases post-traumatic retrograde degeneration of neurons.^(15,16) In addition, the biostimulatory effects of the laser promotes both spontaneous regenerative and anti-inflammatory cellular activities.⁽¹⁷⁾

This is the first case report of Bell's palsy following inactivated COVID-19 vaccines in adolescent. The diagnosis was confirmed by clinical signs and symptoms combined with initial and follow-up electrodiagnostic study. However, there were some limitations regarding the participants in our primary clinical trial to represent the general adolescent population. As they voluntarily registered in the study and generally in good health condition. This reported patient was also in the common age group for developing Bell's palsy. Thus, additional data concerning risk of developing Bell's palsy following inactivated vaccine in adolescent and younger children might be necessary. Particularly if there is further implementation of inactivated COVID-19 vaccines in children and adolescents. Eventually, possible benefit and risk of inactivated COVID-19 vaccine should be weighted in consideration for pediatric patients.

Conclusion

We concluded that Bell's palsy can be the possible adverse event from inactivated BBIBP-CorV (Sinopharm) COVID-19 vaccine in adolescent population.

Acknowledgements

None

Conflict of Interest

All authors declared no conflict of interests

Author Contributions

MT and NK were responsible for the overall data gathering and case discussion. TP mainly participated in the electrodiagnostic study and rehabilitation parts.

Ethical Approval

This manuscript was approved by the ethics committee of Chulabhorn Royal Academy

Consent

Informed consent was obtained from the patient and his parents to publish this case report

Data Availability Statement

There is no new dataset generated in this case report

ORCID

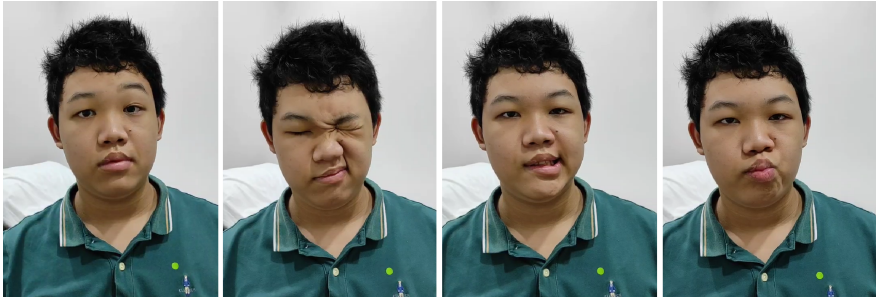Manunya Tandhansakul <https://orcid.org/0000-0003-4764-1924>

Naruporn Kasemlawan <https://orcid.org/0000-0002-8214-327X>

Tanawat Petrutchatachart <https://orcid.org/0000-0002-8791-2824>

References

1. Gilden DH. Clinical practice. Bell's palsy. *N Engl J Med*. 2004;351(13):1323-1331.
2. Karalok ZS, Taskin BD, Ozturk Z, et al. Childhood peripheral facial palsy. *Childs Nerv Syst*. 2018;34(5):911-917.
3. Baugh RF, Basura GJ, Ishii LE, et al. Clinical practice guideline: Bell's palsy. *Otolaryngol Head Neck Surg*. 2013;149(3 suppl):S1-27.
4. Singhi P and Jain V. Bell's palsy in children. *Semin Pediatr Neurol*. 2003;10(4):289-297.
5. Pitaro J, Waissbluth S, Daniel SJ. Do children with Bell's palsy benefit from steroid treatment? A systematic review. *Int J Pediatr Otorhinolaryngol*. 2012;76(7):921-926.
6. Yoo HW, Yoon L, Kim HY, et al. Comparison of conservative therapy and steroid therapy for Bell's palsy in children. *Korean J Pediatr*. 2018;61(10):332-337.
7. Ismail AQ, Alake O, Kallappa C. Do oral steroids aid recovery in children with Bell's palsy? *J Child Neurol*. 2014;29(10):NP96-7.
8. Rowhani-Rahbar A, Klein NP, Lewis N, et al. Immunization and Bell's palsy in children: a case-centered analysis. *Am J Epidemiol*. 2012;175(9):878-885.
9. Bardage C, Persson I, Örtqvist Å, et al. Neurological and autoimmune disorders after vaccination against pandemic influenza A (H1N1) with a monovalent adjuvanted vaccine: population based cohort study in Stockholm, Sweden. *BMJ*. 2011;343:d5956.
10. Wan EYF, Chui CSL, Lai FTT, et al. Bell's palsy following vaccination with mRNA (BNT162b2) and inactivated (CoronaVac) SARS-CoV-2 vaccines: a case series and nested case-control study. *Lancet Infect Dis*. 2022;22(1):64-72.
11. Wijnans L, Dodd CN, Weibel D, Sturkenboom M. Bell's palsy and influenza (H1N1) pdm09 containing vaccines: A self-controlled case series. *PLoS One*. 2017;12(5):e0175539.
12. Sato K, Mano T, Niimi Y, et al. Facial nerve palsy following the administration of COVID-19 mRNA vaccines: analysis of a self-reporting database. *Int J Infect Dis*. 2021;111:310-312.
13. Preston DC and Shapiro BE. *Electromyography and Neuromuscular Disorders: Clinical-Electrophysiologic Correlations*. 3rd ed. London, UK: Elsevier Saunders; 2013.
14. Dumitru D, Amato A, Zwarts M. *Electrodiagnostic medicine*. 2nd ed. Philadelphia: Hanley & Belfus; 2002.
15. Hashmi JT, Huang YY, Osmani BZ, et al. Role of low-level laser therapy in neurorehabilitation. *PM&R*. 2010;2(12 Suppl):S292-305.
16. Santamato A, Solfrizzi V, Panza F, et al. Short-term effects of high- intensity laser therapy versus ultrasound therapy in the treatment of people with subacromial impingement syndrome: a randomized clinical trial. *Phys Ther*. 2009;89(7):643-652.
17. Mester A. Laser biostimulation. *Photomed Laser Surg*. 2013;31(6):237-239.



Muscle	Insertion	Spontaneous Activity						Voluntary Activity				
	Activity	Fib	PSW	Fasc	CRD	H.F.	Amp (uV)	Dur	Morphology	Recruit	Notes	
Right Orbicularis oculi	Increased	0	2+	0	0	0	Normal	Normal	Triphasic	Discrete		
Right Frontalis	Increased	2+	2+	0	0	0	Normal	Normal	Triphasic	Reduced		
Right Orbicularis oris	Increased	0	2+	0	0	1+	Normal	Increased	Complex	Reduced		
Right Zygomaticus	Increased	1+	1+	0	0	0	Normal	Increased	Complex	Discrete		
Right Post auricular	Increased	0	2+	0	0	0	Normal	Normal	Triphasic	-		

