

Contemporary Ablation Techniques for Atrial Fibrillation: An Evidence-Based Analysis

Sutopa Purkayastha¹, Jorge Romero¹, Dhanunjaya Lakkireddy², Juan Carlos Diaz¹, Juan Bello¹, Abhishek Jaiswal¹, Isabella Alviz¹, Miguel Valderrábano³, Andrea Natale⁴, and Luigi Di Biase¹

¹Montefiore Medical Center

²HCA Midwest Health System

³Houston Methodist Debakey Heart & Vascular Center

⁴Saint David's Healthcare

May 28, 2022

Abstract

Since the advent of catheter ablation (CA) for atrial fibrillation (AF) in 1998, our understanding of the pathophysiology, as well as our capacity to target triggers and effectively achieve freedom from AF, has come a long way. However, as the average age of the population and the prevalence of chronic diseases increases, the progression of AF from paroxysmal (PAF) into persistent (PersAF) and long-standing persistent AF (LSPAF) is on the rise. Given the complex mechanisms involved and the presence of multiple trigger sites leading to recurrences, managing non-PAF is a challenge for electrophysiologists around the globe. Multiple ablation techniques have been investigated, some of which have shown promising results, but a standardized technique is yet to be elucidated. In this review, we outline the evidence behind contemporary ablation techniques in the treatment of AF.

Introduction

Atrial fibrillation (AF) is the most common prevalent arrhythmia, estimated to affect approximately 33 million individuals worldwide (1). The cumulative incidence of progression from paroxysmal AF (PAF) to persistent AF (PersAF) and long-standing persistent AF (LSPAF) is estimated at 8.1 per 100 patient-years (2). AF is associated with an elevated risk of thromboembolism, stroke, impaired quality of life, and even mortality (3,4), and achieving rhythm control with catheter ablation (CA) has shown to improve outcomes in recent studies (5). Ectopic foci originating in the pulmonary veins (PVs) represent the main arrhythmia mechanism in PAF as established by Haissaguerre et al. in a landmark trial (6), and as such pulmonary vein isolation (PVI) is the mainstay treatment for PAF. However, in patients with non-PAF, long-term conditions such as hypertension, heart failure, obesity, and sleep apnea lead to structural and cellular changes induced by chronic inflammation, myocyte death and lymphocyte and fatty infiltration, all leading to fibrosis (7). These structural changes within the atria serve as a conduit for fibrillatory waves as they facilitate re-entrant circuits through the fibrotic tissues (8), and the effectiveness of PVI alone for PersAF and LSPAF is far from acceptable (9).

Given these suboptimal results, different ablation strategies and lesion sets have been proposed to increase CA success in the treatment of non-PAF. We will review current evidence surrounding the different approaches for CA of non-PAF and provide evidence-based guidance on best clinical practice.

Pulmonary Vein Isolation

Ever since PVs were demonstrated to participate in AF initiation, PVI has been offered as a strategy to reduce arrhythmia recurrence. Initial trials which were conducted performing ablation at the PV ostia, demonstrated a significant reduction in AF recurrence; however, this strategy was associated with a high risk of PV stenosis (10-12). This eventually reformed into circumferentially isolating the veins at the level of the antrum, a strategy known as wide antral CA (WACA), which has been shown to minimize complications such as PV stenosis while improving AF free survival (13-15) (Figure 1).

As previously stated, WACA alone may not be sufficient to treat patients with non-PAF (16,17). In a prospective study of 2168 patients with non-PAF (18), AF initiation from non-PV trigger sources was demonstrated in 11% of patients referred for CA. Even for PAF, non-PV triggers are being increasingly recognized, especially in patients with systolic dysfunction and during redo procedures despite isolated PVs(19). These non-PV trigger sources have been identified to arise from the posterior wall (PW) of the left atrium (LA), left atrial appendage (LAA), coronary sinus (CS), superior vena cava (SVC), interatrial septum, crista terminalis (CT), Eustachian ridge, the mitral and tricuspid valve annulus, a persistent left superior vena cava (PLSVC), and its remnant the vein of Marshall (VOM) (19,20).

Several ablation techniques targeting these sources have been tested, notably ablation of complex fractionated atrial electrograms (CFAEs), creation of additional linear lesions, rotor ablation, scar tissue ablation, PW isolation (PWI), LAA electrical isolation (LAAEI), ablation of cardiac veins (including the SVC, CS, VOM), cavo-tricuspid isthmus ablation (CTI), renal denervation (RDN), ganglionated plexi (GP) ablation.

Complex Fractionated Atrial Electrograms (CFAEs)

CFAEs were first described by Nademanee et al. (21) as a pattern of continuous atrial activity originating from areas of functional block and slow conduction, and pivot points of reentrant waves. The STAR AF (Substrate and Trigger Ablation for Reduction of Atrial Fibrillation) trial (22) found PVI + CFAEs ablation had higher freedom from AF when compared to PVI or CFAEs ablation alone after one or two procedures. A similar conclusion was derived from a meta-analysis by Hayward et al. (23). However, additional substrate modification was not found to have any benefit over PVI and ablation of non-PV triggers in a subsequent study (24). Verma et al. conducted the STAR AF II (Approaches to Catheter Ablation for Persistent Atrial Fibrillation) trial (25) with a larger sample size, and no reduction in the recurrence rate of AF was observed when CFAEs ablation was performed in addition to PVI. Although CFAE ablation is associated with an increase in intraprocedural AF termination (26), it does not provide any incremental benefit over PVI alone in the reduction of long-term AF recurrence and is associated with longer procedural and fluoroscopy times (27). (Figure 2)

Linear Lesions

Linear ablation is defined as the creation of lines that serve as electrical barriers with the purpose of achieving a bidirectional conduction block to prevent macro-reentrant circuits. This approach typically targets the mitral and cavo-tricuspid isthmus (CTI), and the roof of the LA (Figure 3). However, achieving durable bidirectional block across the lines is often complicated by the formation of gaps, which in turn have pro-arrhythmic effects (28). The STAR AF II trial showed that empirical roof and mitral isthmus lines had no additive benefit to PVI, and the CLEAR-AF (Catheter Ablation Therapy for Persistent Atrial Fibrillation) trial demonstrated similar results (25,29): although more patients achieved sinus rhythm during ablation with ancillary lines, no long-term benefit was related to this finding. Interestingly, in patients with extensive linear ablations atrial tachycardia (AT) was the most common recurrent arrhythmia, as opposed to patients with circumscribed ablations, who most frequently relapsed with AF. In EARNEST-PVI trial, 85% of patients underwent additional linear ablation and did not have a significantly better outcome than the PVI only group at 12 months(30). When performing mitral isthmus ablation, the use of adjunctive VOM ethanol infusion has been shown to be associated with a higher rate of mitral isthmus block and arrhythmia free survival mainly driven by a lower AT recurrence (31-33).

CTI ablation is currently the standard treatment for CTI-dependent atrial flutter (AFL) and has also been proposed as an adjunctive strategy for non-PAF. Pontoppidan et al. (34) conducted a randomized controlled

trial (RCT) on patients with AF undergoing PVI without a history of AFL and failed to show any additional benefit of CTI ablation in terms of freedom from either AF or AFL. Similarly, Mesquita et al. (35) showed in a propensity score analysis that empiric CTI ablation in addition to PVI did not improve AF free survival. Results from a Korean RCT with a longer follow up of 3.4 years were also not in favor of empiric CTI lines (36). Comparable findings were replicated in a sub-group study included in a meta-analysis of 1400 patients, in which CTI ablation did not have any additional benefit in AF with or without AFL (37). These results can be explained by the low frequency of typical AFL after PVI (2.8%), most of which are related to significant right atrial dilation (38). (Figure 4)

Rotors

The idea of rotors as a mechanism for AF has been proposed since 1990 (39,40) and currently is defined as a cyclic activation producing spiral waves which radiate outward into the surrounding tissue around a core of functional block, as opposed to an area of scar tissue, which allow rotors to “move” up to 2-3 cm² around the atrium (41). Interestingly, a significant proportion of rotors have been described in the right atrium (an area not normally targeted during AF ablation) (42), making focal impulse and rotor modulation (FIRM) an appealing adjunctive strategy (43). Although the CONFIRM (Conventional Ablation for Atrial Fibrillation With or Without Focal Impulse and Rotor Modulation) study reported a high degree of freedom from AF with FIRM (42), other studies have demonstrated that, despite the association with a more organized fibrillatory activation within the LA, it does not correlate with an increase in freedom from AF, even after redo procedures (43-46). Furthermore, a head-to-head meta-analysis of six studies including 716 patients (88.5% non-PAF) concluded that FIRM did not add any benefit in improving all-atrial arrhythmia recurrence (47). (Figure 5)

Scar Tissue Ablation

Chronic inflammation and atrial re-modeling lead to areas of fibrosis and scar tissue generation, which serve as substrates for AF. Targeting these areas with either voltage mapping or guided by magnetic resonance images (MRI) has been proposed as an adjunctive strategy. A meta-analysis by Blandino et al. (48) showed that ablation of low voltage areas (LVA) in addition to PVI had a significantly improved freedom from AF at a median follow-up of 17 months.

In contrast, two recent RCTs failed to show any difference in outcomes with MRI-guided fibrosis ablation (49,50). However, in patients with low grade fibrosis (grade I or II) PVI + fibrosis ablation led to a reduction in atrial arrhythmia recurrence (51). Another unique approach called box isolation of fibrotic substrates (BIFA) was successfully tested by Kottkamp et al. (52). Fibrotic areas were identified with voltage mapping and targeted with box isolation and freedom from AF was achieved in 72.2 % of those patients. (Figure 6)

Posterior Wall Isolation (PWI)

The PW of the LA shares its embryologic origin with the PVs (53), which explains its similar electrophysiologic properties and higher arrhythmogenic potential when compared to anterior wall myocytes (54). Furthermore, the PW is exposed to higher stress and tension (which is associated with LVA and electrical scar (55), and is in close proximity to epicardial fat pads and ganglionic plexi (GP), structures known to enhance excitability of the myocardium. The role of GP ablation has been supported in small, randomized studies and a meta-analysis especially for PAF; however, data on long term outcomes is lacking (56-58) (Figure 7). The significant number of AF driver regions located in the PW was further substantiated in a prospective study using non-invasive body surface mapping (59). As such, ablation of the PW has now emerged as an appealing adjunctive strategy to PVI (Figure 8). Several strategies have been developed to achieve PWI, and each approach has theoretical advantages and shortcomings:

- Ablation lines are created either as a single ring encircling the PVs and PW or as a box lesion set, where a roof line connecting the superior PVs and an inferior line between the inferior PVs are done. However, the durability of these lines has remained a challenge due to the formation of conduction gaps.

- Extensive substrate-based ablation, or “debulking of the atrium” where the endpoint is complete electrical silence (60). Nonetheless, although initial results were promising, the small patient population in this study has limited its widespread use.
- A “hybrid” approach, that combines a minimally invasive pericardioscopic epicardial with endocardial ablation, allowing for the formation of durable transmural lesions, while minimizing the risk of injury to adjacent structures(61). Regardless, this strategy is based on a small study, and further trials are required on this novel multi-disciplinary procedure.
- Use of cryoballoon energy to isolate the PW has shown to be promising in two recent RCTs, however complete isolation with cryoablation alone was not achieved in a significant proportion of subjects(62,63). Although no difference in acute complications were reported in these studies, esophageal injury remains a major concern, especially for larger cryoablation balloons. The PIVOTAL study (Comparison of Pulmonary Vein Ablation with or without Left Atrial Posterior Wall Ablation for Persistent AF; NCT03057548) is an ongoing RCT to evaluate the incremental benefit of cryoablation of PWI in addition to PVI.

Despite the evidence behind PW being a vital focus of AF triggers, data regarding its outcomes have been largely conflicting (64-66), perhaps secondary to failure to achieve complete bidirectional block. The RCT PEACEFUL (Electrical Posterior Box Isolation in Persistent Atrial Fibrillation Changed to Paroxysmal Atrial Fibrillation) was unable to find any added benefit of PWI. Reconnection of the PW was observed in all patients who received a second procedure during follow-up (67).

In a meta-analysis of ten studies including patients with PAF and non-PAF, patients who underwent concomitant PWI experienced less recurrence of all-atrial arrhythmias with significant reduction noted in non-PAF subjects(68).

PWI is associated with certain limitations, including technical difficulties in achieving lesions with durable isolation, thermal esophageal injury, and the concern of atrial mechanical dysfunction. The generation of gaps along the ablation lines or the presence of epicardial and sub-epicardial connections are thought to be the triggers for PW reconnection, even after extensive ablations (69,70). These reconnections have been described in 40-70 % of patients (most frequently in the roof line), despite confirmed bidirectional block and the use of adenosine or isoproterenol during the initial ablation procedure (65,71).

Esophageal injury occurs in 47 % of cases of PWI and can range from erythema or ulceration, to the most life-threatening complication, atrio-esophageal fistula (AEF) formation (72). A large global database recorded the incidence of esophageal perforation and AEF to be 0.016 % and 0.011% respectively (73). Continuous luminal esophageal temperature monitoring could theoretically reduce the risk of esophageal lesions. Termination of ablation is advised when esophageal temperature reaches 38°C, as it can continue to rise above 39°C in at least half of patients, even after stopping ablation (74,75). Other techniques, such as adjusting to low irrigation parameters and mechanical displacement of the esophagus, can be considered. The use of contact-force sensing catheters and restricting contact force to < 20 g has been shown to minimize esophageal injury in a single-center randomized study (76).

The concern for deterioration of LA contractile function has been raised with extensive PW ablation. However, LA contractility is primarily a function of the muscular cells at the anterior, septal, inferior, and lateral walls with negligible contribution from the PW. As such, no decline in LA function has been reported after extensive PW ablation (77,78).

Superior Vena Cava Isolation (SVCI)

The SVC has been recognized as a site responsible for both initiation and perpetuation of AF, and several studies have documented its involvement in PAF and non-PAF (79,80). SVCI is achieved with radiofrequency ablation (RFA), using a segmental approach commencing on the septal aspect of the vascular structure. While ablating the lateral aspect, it is crucial to prevent injury to the phrenic nerve and the sinus node. In up to 10 % of patients, complete isolation of SVC is not feasible, due to the risk of damaging the phrenic nerve. In such patients, ablation of right atrial posterior wall can be employed as an alternative (81). The sinus

node lies laterally and below the SVC; RFA should be promptly discontinued if acceleration of the sinus rate is noted (an imminent sign of sinus node injury). It is also imperative to not perform ablation during isoproterenol infusion to avoid masking injury to the sinus node. Cryoballoon has also been used to achieve SVCI and has improved freedom from AT in PAF subjects.(82)

An empirical approach to SVCI has been investigated in a prospective, randomized study (83), which found no significant differences in maintenance of sinus rhythm without antiarrhythmic drugs . The same conclusion was derived from a meta-analysis by Sharma et al. (84)including a total of 526 subjects, in which no difference in AF recurrence when SVCI was added to PVI across all types of AF. When only PAF was analyzed, empiric SVCI showed a trend towards efficacy but failed to reach statistical significance. Yoshiga et al. (85) investigated the incremental benefit of SVCI in recurrent AF after index procedure of PVI without evidence of PVs reconnections on redo procedures and found that SVCI had a success rate of 74 % vs. 66 % in PVI only group. However, SVCI should be attempted with concomitant ablation of other non-PV triggers to obtain better outcomes (86). (Figure 9)

Coronary Sinus (CS) Isolation

In patients with PersAF and LSPAF, some evidence suggests that the CS is a crucial trigger source for AF (87-90). The muscular sleeves of the CS can potentially serve as either an ectopic trigger or be part of a reentrant circuit for AF (91). Given its variable anatomy and, therefore, alternating trigger sites for AF, CS focal ablation is markedly challenging and time-consuming. Della Rocca et al. (92) found that complete CS isolation was associated with a significantly higher arrhythmia-free survival rate than focal CS ablation with a similar incidence of procedural complications. A recent randomized study revealed better outcomes with elimination of distal CS to LA connections compared to PVI and non-PV trigger ablation (93). Given the close relationship between the esophagus and the CS, continuous monitoring of the esophageal temperature is important to avoid complications (94). While ablating along the septal aspect, close monitoring of PR interval is pertinent. Prompt discontinuation of the ablation is recommended if signs of PR prolongation are detected to avoid injury to the atrioventricular (AV) nodal artery. (Figure 10)

Left Atrial Appendage Electrical Isolation (LAAEI)

The LAA is derived from the primordial LA mainly by the adsorption of the primordial PVs and their branches, explaining its role as a potential site of AF triggers. In a non-randomized population of 987 patients undergoing redo AF ablation, 27 % of patients were noted to have triggers arising from the LAA. Moreover, in 8.7 % of the cases, this was the only source of atrial arrhythmia with no PVs or extra-PV reconnection (95).

The RCT BELIEF (Left Atrial Appendage Isolation in Patients with Longstanding Persistent AF Undergoing Catheter Ablation) (96), showed promising results with empiric LAAEI after both index and redo procedures. Among patients who had recurrences and underwent redo ablations, LAAEI was performed in all cases and re-isolated in cases of reconnections. Late LAA reconnections were observed in 37 % of the redo cases. RF and fluoroscopic times were comparable, with no increase in complications. The incremental benefit of LAAEI in addition to PVI was also demonstrated in two meta-analyses including approximately 2000 patients with non-PAF (97,98). This benefit persisted during a 5-year follow-up of 1092 individuals in a propensity score-matched multicenter cohort study. No differences in acute complications or thromboembolic events were evidenced in patients on continued oral anticoagulation (OAC) treatment (99). (Figure 11)

In a propensity score-matched study by Yorgun et al. (100), cryoballoon-based isolation of the PVs and LAA delivered promising results without a significant increase in complications. However, 4 % of the study population had left circumflex artery vasospasm, which resolved with intracoronary nitrate, and 1 % had left phrenic nerve (LPN) injury. It is crucial to prevent mapping and ablation deep into the LAA, as it is a thin structure, and ablation within the lumen is associated with a higher risk of perforation and LPN injury. Imaging integration with cardiac computed tomography and electroanatomic mapping prior to ablation, can help mitigate the potential risk of coronary injury (101). Periprocedural imaging and paced mapping can also delineate the anatomical relationship of the LPN with the LAA, and in case of close proximity a segmental

isolation approach should be considered (102).

The thromboembolic risks associated with LAAEI have been a major concern and have shown mixed results. Rillig et al. (103) showed that at a median follow-up of 6 months after LAAEI, 6 % of patients developed stroke or transient ischemic attack, and 21 % were found to have LAA thrombus on transesophageal echocardiogram (TEE). However, all 3 patients had AF recurrence at the time of stroke, and one was off OAC at the time of event. In contrast, no significantly increased risk for thromboembolic events was reported in the LAAEI groups from two meta-analyses, even after a mean follow-up of 40.5 months (97,98). In a large observational study of 1854 consecutive patients with AF receiving LAAEI along with PVI, thromboembolic events were mainly seen in those who had abnormal LAA function. Moreover, patients who were off OAC, receiving subtherapeutic doses, or were non-compliant had thromboembolic complications at higher rates (104). Interestingly, in patients who had normal LAA function on TEE at 6 months, OAC was discontinued irrespective of the CHA₂DS₂-VASc score, and no thromboembolic events were seen during 2.3 years of follow-up.

For patients in whom long-term OAC is not suitable after LAAEI, LAA occlusion could be considered (105). Another alternative for electrical and mechanical isolation of the LAA is the ligation of the appendage with Lariat, a suture delivery device (SentreHEART, Redwood, CA, USA). This approach has been under investigation, and initially, concerns regarding procedural complications, such as pericardial effusion and the need for urgent cardiac surgery, were reported (106,107). Lakireddy et al. demonstrated improvement in procedural success rate and mortality, while also showing greater freedom from AF recurrence at 1 year follow-up (108). In contrast, the aMAZE (LAA Ligation Adjunctive to PVI for Persistent or Long-standing Persistent Atrial Fibrillation, NCT) trial failed to demonstrate significant differences in arrhythmia recurrence in patients undergoing left atrial ligation + PVI vs. PVI alone (109).

Persistent Left Superior Vena Cava (PLSVC) and the Vein of Marshall (VOM)

PLSVC occurs when the left superior cardinal vein fails to regress to the VOM, as should normally occur (110). A recent study described the possible arrhythmogenic role of PLSVC (111). Data on the use of cryotherapy for isolation of SVC (112) and PLSVC (113,114) has been limited to a few cases but appears to be an attainable alternative.

The VOM is a vestigial fold, which marks the site of the embryological left SVC. This structure has been particularly important in the setting of atrial tachycardias and AFL post-AF ablation (115). In most cases, the VOM triggers can be detected by direct cannulation of the CS with a multipolar catheter. Direct ethanol injection into the VOM has been described, as it allows for specific ablation of the vascular structure, its intrinsic electrical activity, the mitral isthmus, the neighboring myocardium, associated PV connections, and parasympathetic innervation (116). Chugh et al. (117) reported 56 cases in which the VOM was a therapeutic target based on pacing data. The mapping was suggestive of VOM-mediated LA-PVs connections, or VOM-mediated macro-reentrant circuits, or focal tachycardias. The RCT VOM Ethanol Infusion for Persistent Atrial Fibrillation (VENUS) has shown improved freedom from AT/AF with additional VOM ethanol infusion in patients undergoing their first CA (118). However, in patients undergoing redo ablation, addition of VOM EI did not improve outcomes (119). Interestingly as described before, adjunctive VOM EI with linear ablation had favorable outcomes in PersAF (33). (Figure 12)

Renal Denervation (RDN)

RDN has been hypothesized to decrease AF recurrence rate by ablating the renal sympathetic efferent and afferent nerves that interact with the central autonomic nervous system. The ERADICATE-AF trial (Effect of Renal Denervation and Catheter Ablation vs Catheter Ablation Alone on Atrial Fibrillation Recurrence Among Patients with Paroxysmal Atrial Fibrillation and Hypertension) analyzed 302 patients with PAF and showed improved AF freedom with the addition of RDN to PVI (120). Two recent meta-analyses also supported the idea of additional RDN (121,122). However, these studies have been primarily performed on patients with PAF. The SYMPPLICITY AF trial (Renal Nerve Denervation in Patients with Hypertension and Paroxysmal and Persistent Atrial Fibrillation; NCT02064764) is a multicenter trial which explores the

efficacy and safety of additional RDN over PVI.

Final Remarks

Despite the available evidence on the techniques, a standard ablative approach in patients has not yet been elucidated. The figures summarize the most up-to-date evidence on ablation strategies, with each study being scored according to its design and methodology. The final score for each method represents the overall strength of the evidence, either in favor or otherwise. However, we also recommend for the selection of any additional strategy to be guided by the operators' experience, the availability of technological resources (e.g., specialized mapping software, contact force catheters), and patient characteristics.

Decreasing the number of unnecessary ablation lesions within the LA is of paramount importance, as recurrent AT is generally associated with previous lesions (123). As such, strategies that have consistently demonstrated a lack of clinical benefit (i.e., CFAE ablation, CTI ablation) should not be performed, except as a part of a study protocol. Importantly, when managing patients with non-PAF the probability of repeat procedures should be clearly explained to patients, as these might increase the long-term success rate (124).

The ongoing PLEA trial (Systematic Evaluation of Ablation Techniques for Non-Paroxysmal Atrial Fibrillation; NCT04216667) is a multicenter, RCT that will offer further insight into the efficacy and safety of different empirical ablation strategies in non-PAF.

Conclusion

Contributions from non-PV triggers have a significant influence on the progression of PersAF and LSPAF, making it imperative to execute other strategies beyond PVI. With the development of novel approaches, more RCTs are needed to compare each strategy in a head-to-head fashion and to evaluate their efficacy and safety. Importantly, current evidence seems to demonstrate that the use of scar, CFAE and FIRM ablation have no role in the current management of non-PAF, as there is no evidence demonstrating improved outcomes but they are associated with significantly higher risk of procedure related complications. Other strategies, including PWI and LAAEI, are currently being studied and may play a significant role in reducing AF recurrence. Further randomized controlled trials are needed to guide the most appropriate therapy in this group of patients.

References:

1. Chugh SS, Havmoeller R, Narayanan K et al. Worldwide epidemiology of atrial fibrillation: a Global Burden of Disease 2010 Study. *Circulation* 2014;129:837-47.
2. Blum S, Meyre P, Aeschbacher S et al. Incidence and predictors of atrial fibrillation progression: A systematic review and meta-analysis. *Heart Rhythm* 2019;16:502-510.
3. Conen D, Chae CU, Glynn RJ et al. Risk of death and cardiovascular events in initially healthy women with new-onset atrial fibrillation. *JAMA* 2011;305:2080-2087.
4. Wolf PA, Abbott RD, Kannel WB. Atrial fibrillation as an independent risk factor for stroke: the Framingham Study. *Stroke* 1991;22:983-8.
5. Kirchhof P, Camm AJ, Goette A et al. Early Rhythm-Control Therapy in Patients with Atrial Fibrillation. *New England Journal of Medicine* 2020;383:1305-1316.
6. Haïssaguerre M, Jaïs P, Shah DC et al. Spontaneous initiation of atrial fibrillation by ectopic beats originating in the pulmonary veins. *N Engl J Med* 1998;339:659-66.
7. Platonov PG, Mitrofanova LB, Orshanskaya V, Ho SY. Structural abnormalities in atrial walls are associated with presence and persistency of atrial fibrillation but not with age. *J Am Coll Cardiol* 2011;58:2225-32.
8. Lau DH, Linz D, Schotten U, Mahajan R, Sanders P, Kalman JM. Pathophysiology of Paroxysmal and Persistent Atrial Fibrillation: Rotors, Foci and Fibrosis. *Heart Lung Circ* 2017;26:887-893.

9. Calkins H, Hindricks G, Cappato R et al. 2017 HRS/EHRA/ECAS/APHRS/SOLAECE expert consensus statement on catheter and surgical ablation of atrial fibrillation. *Heart Rhythm* 2017;14:e275-e444.
10. Kanagaratnam L, Tomassoni G, Schweikert R et al. Empirical pulmonary vein isolation in patients with chronic atrial fibrillation using a three-dimensional nonfluoroscopic mapping system: long-term follow-up. *Pacing and clinical electrophysiology : PACE* 2001;24:1774-9.
11. Pappone C, Rosanio S, Oreto G et al. Circumferential radiofrequency ablation of pulmonary vein ostia: A new anatomic approach for curing atrial fibrillation. *Circulation* 2000;102:2619-28.
12. Tada H, Oral H, Wasmer K et al. Pulmonary vein isolation: comparison of bipolar and unipolar electrograms at successful and unsuccessful ostial ablation sites. *Journal of cardiovascular electrophysiology* 2002;13:13-9.
13. Proietti R, Santangeli P, Di Biase L et al. Comparative effectiveness of wide antral versus ostial pulmonary vein isolation: a systematic review and meta-analysis. *Circ Arrhythm Electrophysiol* 2014;7:39-45.
14. Medi C, Sparks PB, Morton JB et al. Pulmonary vein antral isolation for paroxysmal atrial fibrillation: results from long-term follow-up. *J Cardiovasc Electrophysiol* 2011;22:137-41.
15. Nilsson B, Chen X, Pehrson S, Køber L, Hilden J, Svendsen JH. Recurrence of pulmonary vein conduction and atrial fibrillation after pulmonary vein isolation for atrial fibrillation: a randomized trial of the ostial versus the extraostial ablation strategy. *Am Heart J* 2006;152:537.e1-8.
16. Mohanty S, Mohanty P, Di Biase L et al. Long-term follow-up of patients with paroxysmal atrial fibrillation and severe left atrial scarring: comparison between pulmonary vein antrum isolation only or pulmonary vein isolation combined with either scar homogenization or trigger ablation. *Europace* 2017;19:1790-1797.
17. Zhao Y, Di Biase L, Trivedi C et al. Importance of non-pulmonary vein triggers ablation to achieve long-term freedom from paroxysmal atrial fibrillation in patients with low ejection fraction. *Heart Rhythm* 2016;13:141-149.
18. Santangeli P, Zado ES, Hutchinson MD et al. Prevalence and distribution of focal triggers in persistent and long-standing persistent atrial fibrillation. *Heart Rhythm* 2016;13:374-82.
19. Gökoğlu Y, Mohanty S, Güneş MF et al. Pulmonary Vein Antrum Isolation in Patients With Paroxysmal Atrial Fibrillation: More Than a Decade of Follow-Up. *Circ Arrhythm Electrophysiol* 2016;9.
20. Mohanty S, Trivedi C, Horton P et al. Natural History of Arrhythmia After Successful Isolation of Pulmonary Veins, Left Atrial Posterior Wall, and Superior Vena Cava in Patients With Paroxysmal Atrial Fibrillation: A Multi-Center Experience. *J Am Heart Assoc* 2021;10:e020563.
21. Nademanee K, McKenzie J, Kosar E et al. A new approach for catheter ablation of atrial fibrillation: mapping of the electrophysiologic substrate. *J Am Coll Cardiol* 2004;43:2044-53.
22. Verma A, Mantovan R, Macle L et al. Substrate and Trigger Ablation for Reduction of Atrial Fibrillation (STAR AF): a randomized, multicentre, international trial. *Eur Heart J* 2010;31:1344-56.
23. Hayward RM, Upadhyay GA, Mela T et al. Pulmonary vein isolation with complex fractionated atrial electrogram ablation for paroxysmal and nonparoxysmal atrial fibrillation: A meta-analysis. *Heart Rhythm* 2011;8:994-1000.
24. Dixit S, Marchlinski FE, Lin D et al. Randomized Ablation Strategies for the Treatment of Persistent Atrial Fibrillation. *Circulation: Arrhythmia and Electrophysiology* 2012;5:287-294.
25. Verma A, Jiang C-y, Betts TR et al. Approaches to Catheter Ablation for Persistent Atrial Fibrillation. *New England Journal of Medicine* 2015;372:1812-1822.
26. Sau A, Al-Aidarous S, Howard J et al. Optimum lesion set and predictors of outcome in persistent atrial fibrillation ablation: a meta-regression analysis. *Europace : European pacing, arrhythmias, and*

cardiac electrophysiology : journal of the working groups on cardiac pacing, arrhythmias, and cardiac cellular electrophysiology of the European Society of Cardiology 2019;21:1176-1184.

27. Chen YH, Lin H, Wang Q, Hou JW, Li YG. Efficacy and Safety of Adjunctive Substrate Modification During Pulmonary Vein Isolation for Atrial Fibrillation: A Meta-Analysis. *Heart, lung & circulation* 2020;29:422-436.

28. Nakai K, Kashiwa A, Kunitomi A, Matsuoka S. Conduction gap mapping of linear ablation lesions with high density mapping. *Journal of cardiovascular electrophysiology* 2020.

29. Yao Y, Hu F, Du Z et al. The value of extensive catheter linear ablation on persistent atrial fibrillation (the CLEAR-AF Study). *Int J Cardiol* 2020;316:125-129.

30. Inoue K, Hikoso S, Masuda M et al. Pulmonary vein isolation alone vs. more extensive ablation with defragmentation and linear ablation of persistent atrial fibrillation: the EARNEST-PVI trial. *Europace* 2021;23:565-574.

31. Gillis K, O'Neill L, Wielandts J-Y et al. Vein of Marshall Ethanol Infusion as First Step for Mitral Isthmus Linear Ablation. *JACC: Clinical Electrophysiology* 2022;8:367-376.

32. Nakashima T, Pambrun T, Vlachos K et al. Strategy for repeat procedures in patients with persistent atrial fibrillation: Systematic linear ablation with adjunctive ethanol infusion into the vein of Marshall versus electrophysiology-guided ablation. *J Cardiovasc Electrophysiol* 2022.

33. Lai Y, Liu X, Sang C et al. Effectiveness of ethanol infusion into the vein of Marshall combined with a fixed anatomical ablation strategy (the "upgraded 2C3L" approach) for catheter ablation of persistent atrial fibrillation. *J Cardiovasc Electrophysiol* 2021;32:1849-1856.

34. Pontoppidan J, Nielsen JC, Poulsen SH et al. Prophylactic cavotricuspid isthmus block during atrial fibrillation ablation in patients without atrial flutter: a randomised controlled trial. *Heart* 2009;95:994-9.

35. Mesquita J, Ferreira AM, Cavaco D et al. Impact of prophylactic cavotricuspid isthmus ablation in atrial fibrillation recurrence after a first pulmonary vein isolation procedure. *Int J Cardiol* 2018;259:82-87.

36. Kim SH, Oh YS, Choi Y et al. Long-Term Efficacy of Prophylactic Cavotricuspid Isthmus Ablation during Atrial Fibrillation Ablation in Patients Without Typical Atrial Flutter: a Prospective, Multicentre, Randomized Trial. *Korean Circ J* 2021;51:58-64.

37. Romero J, Patel K, Briceno D et al. Cavotricuspid isthmus line in patients undergoing catheter ablation of atrial fibrillation with or without history of typical atrial flutter: A meta-analysis. *J Cardiovasc Electrophysiol* 2020;31:1987-1995.

38. Gucuk Ipek E, Marine J, Yang E et al. Predictors and Incidence of Atrial Flutter After Catheter Ablation of Atrial Fibrillation. *The American journal of cardiology* 2019;124:1690-1696.

39. Krummen DE, Swarup V, Narayan SM. The role of rotors in atrial fibrillation. *J Thorac Dis* 2015;7:142-151.

40. Davidenko JM, Kent PF, Chialvo DR, Michaels DC, Jalife J. Sustained vortex-like waves in normal isolated ventricular muscle. *Proceedings of the National Academy of Sciences of the United States of America* 1990;87:8785-9.

41. Narayan SM, Shivkumar K, Krummen DE, Miller JM, Rappel WJ. Panoramic electrophysiological mapping but not electrogram morphology identifies stable sources for human atrial fibrillation: stable atrial fibrillation rotors and focal sources relate poorly to fractionated electrograms. *Circulation Arrhythmia and electrophysiology* 2013;6:58-67.

42. Narayan SM, Krummen DE, Shivkumar K, Clopton P, Rappel WJ, Miller JM. Treatment of atrial fibrillation by the ablation of localized sources: CONFIRM (Conventional Ablation for Atrial Fibrillation

With or Without Focal Impulse and Rotor Modulation) trial. *J Am Coll Cardiol* 2012;60:628-36.

43. Peigh G, Wasserlauf J, Kaplan RM et al. Repeat pulmonary vein isolation with or without FIRM-guided ablation for recurrent atrial fibrillation with pulmonary vein reconnection. *Journal of cardiovascular electrophysiology* 2020;31:1031-1037.

44. Tilz R, Lenz CL, Sommer PS et al. P2846 Focal impulse and rotor modulation ablation versus pulmonary vein isolation for the treatment of paroxysmal atrial fibrillation (FIRMAP AF study). *European Heart Journal* 2019;40.

45. Mohanty S, Mohanty P, Trivedi C et al. Long-Term Outcome of Pulmonary Vein Isolation With and Without Focal Impulse and Rotor Modulation Mapping. *Circulation: Arrhythmia and Electrophysiology* 2018;11:e005789.

46. Liu PR, Friedman DJ, Barnett AS, Jackson KP, Daubert JP, Piccini JP. Focal impulse and rotor modulation of atrial rotors during atrial fibrillation leads to organization of left atrial activation as reflected by waveform morphology recurrence quantification analysis and organizational index. *Journal of arrhythmia* 2020;36:311-318.

47. Romero J, Gabr M, Alviz I et al. Focal impulse and rotor modulation guided ablation versus pulmonary vein isolation for atrial fibrillation: A meta-analysis of head-to-head comparative studies. *Journal of Cardiovascular Electrophysiology* 2021;32:1822-1832.

48. Blandino A, Bianchi F, Grossi S et al. Left Atrial Substrate Modification Targeting Low-Voltage Areas for Catheter Ablation of Atrial Fibrillation: A Systematic Review and Meta-Analysis. *Pacing Clin Electrophysiol* 2017;40:199-212.

49. Bisbal F, Benito E, Teis A et al. Magnetic Resonance Imaging-Guided Fibrosis Ablation for the Treatment of Atrial Fibrillation: The ALICIA Trial. *Circulation: Arrhythmia and Electrophysiology*;0.

50. Dean NFMTGJM. Efficacy of LGE-MRI-guided fibrosis ablation versus conventional catheter ablation of atrial fibrillation: The DECAAF II trial. in press 2021.

51. Yamaguchi T, Tsuchiya T, Nakahara S et al. Efficacy of Left Atrial Voltage-Based Catheter Ablation of Persistent Atrial Fibrillation. *J Cardiovasc Electrophysiol* 2016;27:1055-63.

52. Kottkamp H, Berg J, Bender R, Rieger A, Schreiber D. Box Isolation of Fibrotic Areas (BIFA): A Patient-Tailored Substrate Modification Approach for Ablation of Atrial Fibrillation. *J Cardiovasc Electrophysiol* 2016;27:22-30.

53. Abdulla R, Blew GA, Holterman MJ. Cardiovascular embryology. *Pediatr Cardiol* 2004;25:191-200.

54. Suenari K, Chen YC, Kao YH et al. Discrepant electrophysiological characteristics and calcium homeostasis of left atrial anterior and posterior myocytes. *Basic Res Cardiol* 2011;106:65-74.

55. Hunter RJ, Liu Y, Lu Y, Wang W, Schilling RJ. Left Atrial Wall Stress Distribution and Its Relationship to Electrophysiologic Remodeling in Persistent Atrial Fibrillation. *Circulation: Arrhythmia and Electrophysiology* 2012;5:351-360.

56. Katritsis DG, Pokushalov E, Romanov A et al. Autonomic denervation added to pulmonary vein isolation for paroxysmal atrial fibrillation: a randomized clinical trial. *J Am Coll Cardiol* 2013;62:2318-25.

57. Driessen AHG, Berger WR, Krul SPJ et al. Ganglion Plexus Ablation in Advanced Atrial Fibrillation: The AFACT Study. *J Am Coll Cardiol* 2016;68:1155-1165.

58. Kampaktsis PN, Oikonomou EK, D YC, Cheung JW. Efficacy of ganglionated plexi ablation in addition to pulmonary vein isolation for paroxysmal versus persistent atrial fibrillation: a meta-analysis of randomized controlled clinical trials. *J Interv Card Electrophysiol* 2017;50:253-260.

59. Lim HS, Hocini M, Dubois R et al. Complexity and Distribution of Drivers in Relation to Duration of Persistent Atrial Fibrillation. *Journal of the American College of Cardiology* 2017;69:1257-1269.
60. Bai R, Di Biase L, Mohanty P et al. Proven isolation of the pulmonary vein antrum with or without left atrial posterior wall isolation in patients with persistent atrial fibrillation. *Heart Rhythm* 2016;13:132-40.
61. DeLurgio DB, Crossen KJ, Gill J et al. Hybrid Convergent Procedure for the Treatment of Persistent and Long-Standing Persistent Atrial Fibrillation. *Circulation: Arrhythmia and Electrophysiology* 2020;13:e009288.
62. Ahn J, Shin DG, Han SJ, Lim HE. Does isolation of the left atrial posterior wall using cryoballoon ablation improve clinical outcomes in patients with persistent atrial fibrillation? A prospective randomized controlled trial. *Europace* 2022.
63. Aryana A, Allen SL, Pujara DK et al. Concomitant Pulmonary Vein and Posterior Wall Isolation Using Cryoballoon With Adjunct Radiofrequency in Persistent Atrial Fibrillation. *JACC Clin Electrophysiol* 2021;7:187-196.
64. Mun H-S, Joung B, Shim J et al. Does additional linear ablation after circumferential pulmonary vein isolation improve clinical outcome in patients with paroxysmal atrial fibrillation? Prospective randomised study. *Heart (British Cardiac Society)* 2012;98:480-484.
65. Tamborero D, Mont L, Berruezo A et al. Left atrial posterior wall isolation does not improve the outcome of circumferential pulmonary vein ablation for atrial fibrillation: a prospective randomized study. *Circ Arrhythm Electrophysiol* 2009;2:35-40.
66. Lee JM, Shim J, Park J et al. The Electrical Isolation of the Left Atrial Posterior Wall in Catheter Ablation of Persistent Atrial Fibrillation. *J Am Coll Cardiol EP* 2019;5:1253-1261.
67. Pak H-N, Park J, Park J-W et al. Electrical Posterior Box Isolation in Persistent Atrial Fibrillation Changed to Paroxysmal Atrial Fibrillation: A Multi-center, Prospective, Randomized Study (PEACEFUL). *Circulation: Arrhythmia and Electrophysiology*;0.
68. Romero J, Polanco D, Alviz I et al. Posterior Wall Electrical Isolation in Patients Undergoing Catheter Ablation for Paroxysmal and Non-Paroxysmal Atrial Fibrillation: A Meta-Analysis of Randomized Controlled Trial. *Journal of American College of Cardiology EP* 2021;in press.
69. Hong KL, Baley J, Baranchuk A, Bisleri G, Glover BM. Epicardial Electrical Activation During Atrial Fibrillation. Looking at the Other Side of the Coin 2019;1:401-402.
70. Groot Nd, Does Lvd, Yaksh A et al. Direct Proof of Endo-Epicardial Asynchrony of the Atrial Wall During Atrial Fibrillation in Humans. *Circulation: Arrhythmia and Electrophysiology* 2016;9:e003648.
71. Markman TM, Hyman MC, Kumareswaran R et al. Durability of posterior wall isolation after catheter ablation among patients with recurrent atrial fibrillation. *Heart rhythm : the official journal of the Heart Rhythm Society* 2020.
72. Schmidt M, Nölker G, Marschang H et al. Incidence of oesophageal wall injury post-pulmonary vein antrum isolation for treatment of patients with atrial fibrillation. *Europace* 2008;10:205-9.
73. Barbhuiya CR, Kumar S, John RM et al. Global survey of esophageal and gastric injury in atrial fibrillation ablation: incidence, time to presentation, and outcomes. *J Am Coll Cardiol* 2015;65:1377-1378.
74. Kiuchi K, Okajima K, Shimane A et al. Impact of esophageal temperature monitoring guided atrial fibrillation ablation on preventing asymptomatic excessive transmural injury. *Journal of arrhythmia* 2016;32:36-41.
75. Singh SM, d'Avila A, Doshi SK et al. Esophageal injury and temperature monitoring during atrial fibrillation ablation. *Circulation Arrhythmia and electrophysiology* 2008;1:162-8.

76. Zhang X, Kuang X, Gao X et al. RESCUE-AF in Patients Undergoing Atrial Fibrillation Ablation. *Circulation: Arrhythmia and Electrophysiology* 2019;12:e007044.
77. Verma A, Kilicaslan F, Adams JR et al. Extensive ablation during pulmonary vein antrum isolation has no adverse impact on left atrial function: an echocardiography and cine computed tomography analysis. *J Cardiovasc Electrophysiol* 2006;17:741-6.
78. Kim JS, Shin SY, Na JO et al. Does isolation of the left atrial posterior wall improve clinical outcomes after radiofrequency catheter ablation for persistent atrial fibrillation?: A prospective randomized clinical trial. *Int J Cardiol* 2015;181:277-83.
79. Tsai CF, Tai CT, Hsieh MH et al. Initiation of atrial fibrillation by ectopic beats originating from the superior vena cava: electrophysiological characteristics and results of radiofrequency ablation. *Circulation* 2000;102:67-74.
80. Lin WS, Tai CT, Hsieh MH et al. Catheter ablation of paroxysmal atrial fibrillation initiated by non-pulmonary vein ectopy. *Circulation* 2003;107:3176-83.
81. Gianni C, Sanchez JE, Mohanty S et al. Isolation of the superior vena cava from the right atrial posterior wall: a novel ablation approach. *Europace* 2018;20:e124-e132.
82. Overeinder I, Osório TG, Călburean PA et al. Comparison between superior vena cava ablation in addition to pulmonary vein isolation and standard pulmonary vein isolation in patients with paroxysmal atrial fibrillation with the cryoballoon technique. *J Interv Card Electrophysiol* 2021;62:579-586.
83. Corrado A, Bonso A, Madalosso M et al. Impact of systematic isolation of superior vena cava in addition to pulmonary vein antrum isolation on the outcome of paroxysmal, persistent, and permanent atrial fibrillation ablation: results from a randomized study. *J Cardiovasc Electrophysiol* 2010;21:1-5.
84. Sharma SP, Sangha RS, Dahal K, Krishnamoorthy P. The role of empiric superior vena cava isolation in atrial fibrillation: a systematic review and meta-analysis of randomized controlled trials. *J Interv Card Electrophysiol* 2017;48:61-67.
85. Yoshiga Y, Shimizu A, Ueyama T et al. Strict sequential catheter ablation strategy targeting the pulmonary veins and superior vena cava for persistent atrial fibrillation. *J Cardiol* 2018;72:128-134.
86. Della Rocca DG, Mohanty S, Mohanty P et al. Long-term outcomes of catheter ablation in patients with longstanding persistent atrial fibrillation lasting less than 2 years. *J Cardiovasc Electrophysiol* 2018;29:1607-1615.
87. Oral H, Ozaydin M, Chugh A et al. Role of the coronary sinus in maintenance of atrial fibrillation. *J Cardiovasc Electrophysiol* 2003;14:1329-36.
88. Haïssaguerre M, Hocini M, Takahashi Y et al. Impact of catheter ablation of the coronary sinus on paroxysmal or persistent atrial fibrillation. *J Cardiovasc Electrophysiol* 2007;18:378-86.
89. Knecht S, O'Neill MD, Matsuo S et al. Focal arrhythmia confined within the coronary sinus and maintaining atrial fibrillation. *J Cardiovasc Electrophysiol* 2007;18:1140-6.
90. Chang HY, Lo LW, Lin YJ et al. Long-term outcome of catheter ablation in patients with atrial fibrillation originating from nonpulmonary vein ectopy. *J Cardiovasc Electrophysiol* 2013;24:250-8.
91. Morita H, Zipes DP, Morita ST, Wu J. Isolation of canine coronary sinus musculature from the atria by radiofrequency catheter ablation prevents induction of atrial fibrillation. *Circ Arrhythm Electrophysiol* 2014;7:1181-8.
92. Della Rocca DG, Di Biase L, Mohanty S et al. ELECTRICAL ISOLATION VERSUS FOCAL ABLATION OF THE CORONARY SINUS IN PATIENTS WITH PERSISTENT ATRIAL FIBRILLATION. *Journal of the American College of Cardiology* 2020;75:281.

93. Kuo L, Frankel DS, Lin A et al. PRECAF Randomized Controlled Trial. *Circ Arrhythm Electrophysiol* 2021;14:e008993.
94. Güneş MF, Gökoğlu Y, L DIB et al. Ablating the Posterior Heart: Cardioresophageal Fistula Complicating Radiofrequency Ablation in the Coronary Sinus. *J Cardiovasc Electrophysiol* 2015;26:1376-8.
95. Di Biase L, Burkhardt JD, Mohanty P et al. Left atrial appendage: an underrecognized trigger site of atrial fibrillation. *Circulation* 2010;122:109-18.
96. Di Biase L, Burkhardt JD, Mohanty P et al. Left Atrial Appendage Isolation in Patients With Long-standing Persistent AF Undergoing Catheter Ablation: BELIEF Trial. *J Am Coll Cardiol* 2016;68:1929-1940.
97. Romero J, Gabr M, Patel K et al. Efficacy and safety of left atrial appendage electrical isolation during catheter ablation of atrial fibrillation: an updated meta-analysis. *EP Europace* 2020;23:226-237.
98. Friedman DJ, Black-Maier EW, Barnett AS et al. Left Atrial Appendage Electrical Isolation for Treatment of Recurrent Atrial Fibrillation: A Meta-Analysis. *J Am Coll Cardiol EP* 2018;4:112-120.
99. Romero J, Di Biase L, Mohanty S et al. Long-Term Outcomes of Left Atrial Appendage Electrical Isolation in Patients With Nonparoxysmal Atrial Fibrillation: A Propensity Score-Matched Analysis. *Circ Arrhythm Electrophysiol* 2020;13:e008390.
100. Yorgun H, Canpolat U, Kocyigit D, Çöteli C, Evranos B, Aytemir K. Left atrial appendage isolation in addition to pulmonary vein isolation in persistent atrial fibrillation: one-year clinical outcome after cryoballoon-based ablation. *Europace* 2017;19:758-768.
101. Romero J, Natale A, Cerna L et al. Imaging Integration to Localize and Protect the Left Coronary Artery in Patients Undergoing LAEI. *JACC: Clinical Electrophysiology* 2020;6:157-167.
102. Romero J, Tarantino N, Cerrud-Rodriguez R, Alviz I, Gruppesso V, Di Biase L. Segmental left atrial appendage electrical isolation to avoid left phrenic nerve damage. *HeartRhythm Case Rep* 2019;5:269-273.
103. Rillig A, Tilz RR, Lin T et al. Unexpectedly High Incidence of Stroke and Left Atrial Appendage Thrombus Formation After Electrical Isolation of the Left Atrial Appendage for the Treatment of Atrial Tachyarrhythmias. *Circ Arrhythm Electrophysiol* 2016;9:e003461.
104. Di Biase L, Mohanty S, Trivedi C et al. Stroke Risk in Patients With Atrial Fibrillation Undergoing Electrical Isolation of the Left Atrial Appendage. *J Am Coll Cardiol* 2019;74:1019-1028.
105. Holmes DR, Reddy VY, Turi ZG et al. Percutaneous closure of the left atrial appendage versus warfarin therapy for prevention of stroke in patients with atrial fibrillation: a randomised non-inferiority trial. *Lancet* 2009;374:534-42.
106. Chatterjee S, Herrmann HC, Wilensky RL et al. Safety and Procedural Success of Left Atrial Appendage Exclusion With the Lariat Device: A Systematic Review of Published Reports and Analytic Review of the FDA MAUDE Database. *JAMA Internal Medicine* 2015;175:1104-1109.
107. Bartus K, Han FT, Bednarek J et al. Percutaneous Left Atrial Appendage Suture Ligation Using the LARIAT Device in Patients With Atrial Fibrillation. Initial Clinical Experience 2013;62:108-118.
108. Lakkireddy D, Afzal MR, Lee RJ et al. Short and long-term outcomes of percutaneous left atrial appendage suture ligation: Results from a US multicenter evaluation. *Heart Rhythm* 2016;13:1030-1036.
109. David J Wilber M, Dhanunjaya Lakkireddy M, FHRS. Outcomes of Adjunctive LAA Utilizing LARIAT Compared to Pulmonary Vein Atrial Isolation Alone. in press.
110. Dearstine M, Taylor W, Kerut EK. Persistent left superior vena cava: chest x-ray and echocardiographic findings. *Echocardiography* 2000;17:453-5.

111. Kim YG, Han S, Choi J-I et al. Impact of persistent left superior vena cava on radiofrequency catheter ablation in patients with atrial fibrillation. *EP Europace* 2019;21:1824-1832.
112. Santoro F, Rillig A, Sohns C et al. Second-Generation Cryoballoon Atrial Fibrillation Ablation in Patients With Persistent Left Superior Caval Vein. *JACC Clin Electrophysiol* 2019;5:590-598.
113. Fujino T, Yuzawa H, Kinoshita T, Shinohara M, Okishige K, Ikeda T. A case of successful cryoballoon ablation of paroxysmal atrial fibrillation originating from a persistent left superior vena cava. *J Cardiol Cases* 2019;20:77-80.
114. Briceño DF, Valderrábano M. Recurrent perimitral flutter due to vein of Marshall epicardial connections bypassing the mitral isthmus: response to ethanol infusion. *Circulation Arrhythmia and electrophysiology* 2014;7:988-989.
115. Kurotobi T, Ito H, Inoue K et al. Marshall vein as arrhythmogenic source in patients with atrial fibrillation: correlation between its anatomy and electrophysiological findings. *J Cardiovasc Electrophysiol* 2006;17:1062-7.
116. Rodríguez-Mañero M, Schurmann P, Valderrábano M. Ligament and vein of Marshall: A therapeutic opportunity in atrial fibrillation. *Heart rhythm* 2016;13:593-601.
117. Chugh A, Gurm HS, Krishnasamy K et al. Spectrum of atrial arrhythmias using the ligament of Marshall in patients with atrial fibrillation. *Heart Rhythm* 2018;15:17-24.
118. Valderrábano M, Peterson LE, Swarup V et al. Effect of Catheter Ablation With Vein of Marshall Ethanol Infusion vs Catheter Ablation Alone on Persistent Atrial Fibrillation: The VENUS Randomized Clinical Trial. *JAMA* 2020;324:1620-1628.
119. Lador A, Valderrabano M. B-PO05-066 VEIN OF MARSHALL ALCOHOL IN REPEAT ABLATION OF PERSISTENT ATRIAL FIBRILLATION (MARS-AF). *Heart Rhythm* 2021;18:S398.
120. Steinberg JS, Shabanov V, Ponomarev D et al. Effect of Renal Denervation and Catheter Ablation vs Catheter Ablation Alone on Atrial Fibrillation Recurrence Among Patients With Paroxysmal Atrial Fibrillation and Hypertension: The ERADICATE-AF Randomized Clinical Trial. *Jama* 2020;323:248-255.
121. Ukena C, Becker N, Pavlicev V et al. Catheter-based renal denervation as adjunct to pulmonary vein isolation for treatment of atrial fibrillation: a systematic review and meta-analysis. *J Hypertens* 2020;38:783-790.
122. Kewcharoen J, Vutthikraivit W, Rattanawong P et al. Renal sympathetic denervation in addition to pulmonary vein isolation reduces the recurrence rate of atrial fibrillation: an updated meta-analysis of randomized control trials. *Journal of Interventional Cardiac Electrophysiology* 2020.
123. Kitamura T, Takigawa M, Derval N et al. Atrial tachycardia circuits include low voltage area from index atrial fibrillation ablation relationship between RF ablation lesion and AT. *Journal of Cardiovascular Electrophysiology* 2020;31:1640-1648.
124. Clarnette JA, Brooks AG, Mahajan R et al. Outcomes of persistent and long-standing persistent atrial fibrillation ablation: a systematic review and meta-analysis. *Europace : European pacing, arrhythmias, and cardiac electrophysiology : journal of the working groups on cardiac pacing, arrhythmias, and cardiac cellular electrophysiology of the European Society of Cardiology* 2018;20:f366-f376.
125. Fiala M, Chovančík J, Nevřalová R et al. Pulmonary vein isolation using segmental versus electroanatomical circumferential ablation for paroxysmal atrial fibrillation. *Journal of Interventional Cardiac Electrophysiology* 2008;22:13-21.
126. Liu X, Long D, Dong J et al. Is Circumferential Pulmonary Vein Isolation Preferable to Stepwise Segmental Pulmonary Vein Isolation for Patients With Paroxysmal Atrial Fibrillation?

A Randomized Study. *Circulation Journal* 2006;70:1392-1397.

127. Oral H, Scharf C, Chugh A et al. Catheter ablation for paroxysmal atrial fibrillation: segmental pulmonary vein ostial ablation versus left atrial ablation. *Circulation* 2003;108:2355-60.

128. Arentz T, Weber R, Bürkle G et al. Small or large isolation areas around the pulmonary veins for the treatment of atrial fibrillation? Results from a prospective randomized study. *Circulation* 2007;115:3057-63.

129. Jin Hwang H, Myung Lee J, Joung B et al. Atrial electroanatomical remodeling as a determinant of different outcomes between two current ablation strategies: circumferential pulmonary vein isolation vs pulmonary vein isolation. *Clin Cardiol* 2010;33:E69-74.

130. Mansour M, Ruskin J, Keane D. Efficacy and safety of segmental ostial versus circumferential extra-ostial pulmonary vein isolation for atrial fibrillation. *J Cardiovasc Electrophysiol* 2004;15:532-7.

131. CHEN M, YANG B, CHEN H et al. Randomized Comparison Between Pulmonary Vein Antral Isolation versus Complex Fractionated Electrogram Ablation for Paroxysmal Atrial Fibrillation. *Journal of Cardiovascular Electrophysiology* 2011;22:973-981.

132. DEISENHOFER I, ESTNER H, REENTS T et al. Does Electrogram Guided Substrate Ablation Add to the Success of Pulmonary Vein Isolation in Patients with Paroxysmal Atrial Fibrillation? A Prospective, Randomized Study. *Journal of Cardiovascular Electrophysiology* 2009;20:514-521.

133. Di Biase L, Elayi CS, Fahmy TS et al. Atrial fibrillation ablation strategies for paroxysmal patients: randomized comparison between different techniques. *Circ Arrhythm Electrophysiol* 2009;2:113-9.

134. Nürrich JM, Steven D, Berner I et al. Impact of biatrial defragmentation in patients with paroxysmal atrial fibrillation: results from a randomized prospective study. *Heart Rhythm* 2014;11:1536-42.

135. Verma A, Patel D, Famy T et al. Efficacy of adjuvant anterior left atrial ablation during intracardiac echocardiography-guided pulmonary vein antrum isolation for atrial fibrillation. *J Cardiovasc Electrophysiol* 2007;18:151-6.

136. Fadahunsi O, Talabi T, Olowoyeye A, Iluyomade A, Shogbesan O, Donato A. Ablation of Complex Fractionated Atrial Electrograms for Atrial Fibrillation Rhythm Control: A Systematic Review and Meta-analysis. *Can J Cardiol* 2016;32:791-802.

137. Verma A, Novak P, Macle L et al. A prospective, multicenter evaluation of ablating complex fractionated electrograms (CFEs) during atrial fibrillation (AF) identified by an automated mapping algorithm: acute effects on AF and efficacy as an adjuvant strategy. *Heart Rhythm* 2008;5:198-205.

138. Vogler J, Willems S, Sultan A et al. Pulmonary Vein Isolation Versus Defragmentation: The CHASE-AF Clinical Trial. *J Am Coll Cardiol* 2015;66:2743-2752.

139. Oral H, Chugh A, Yoshida K et al. A Randomized Assessment of the Incremental Role of Ablation of Complex Fractionated Atrial Electrograms After Antral Pulmonary Vein Isolation for Long-Lasting Persistent Atrial Fibrillation. *Journal of the American College of Cardiology* 2009;53:782-789.

140. Wong KC, Paisey JR, Sopher M et al. No Benefit of Complex Fractionated Atrial Electrogram Ablation in Addition to Circumferential Pulmonary Vein Ablation and Linear Ablation: Benefit of Complex Ablation Study. *Circulation Arrhythmia and electrophysiology* 2015;8:1316-24.

141. Elayi CS, Verma A, Di Biase L et al. Ablation for longstanding permanent atrial fibrillation: Results from a randomized study comparing three different strategies. *Heart Rhythm* 2008;5:1658-1664.

142. LIN Y-J, TAI C-T, CHANG S-L et al. Efficacy of Additional Ablation of Complex Fractionated Atrial Electrograms for Catheter Ablation of Nonparoxysmal Atrial Fibrillation. *Journal of Cardiovascular Electrophysiology* 2009;20:607-615.

143. Dixit S, Marchlinski FE, Lin D et al. Randomized ablation strategies for the treatment of persistent atrial fibrillation: RASTA study. *Circ Arrhythm Electrophysiol* 2012;5:287-94.
144. Sawhney N, Anousheh R, Chen W, Feld GK. Circumferential pulmonary vein ablation with additional linear ablation results in an increased incidence of left atrial flutter compared with segmental pulmonary vein isolation as an initial approach to ablation of paroxysmal atrial fibrillation. *Circulation Arrhythmia and electrophysiology* 2010;3:243-8.
145. Wynn GJ, Panikker S, Morgan M et al. Batrial linear ablation in sustained nonpermanent AF: Results of the substrate modification with ablation and antiarrhythmic drugs in nonpermanent atrial fibrillation (SMAN-PAF) trial. *Heart Rhythm* 2016;13:399-406.
146. Gaita F, Caponi D, Scaglione M et al. Long-term clinical results of 2 different ablation strategies in patients with paroxysmal and persistent atrial fibrillation. *Circ Arrhythm Electrophysiol* 2008;1:269-75.
147. FASSINI G, RIVA S, CHIODELLI R et al. Left Mitral Isthmus Ablation Associated with PV Isolation: Long-Term Results of a Prospective Randomized Study. *Journal of Cardiovascular Electrophysiology* 2005;16:1150-1156.
148. Willems S, Klemm H, Rostock T et al. Substrate modification combined with pulmonary vein isolation improves outcome of catheter ablation in patients with persistent atrial fibrillation: a prospective randomized comparison. *Eur Heart J* 2006;27:2871-8.
149. Wazni O, Marrouche NF, Martin DO et al. Randomized study comparing combined pulmonary vein-left atrial junction disconnection and cavotricuspid isthmus ablation versus pulmonary vein-left atrial junction disconnection alone in patients presenting with typical atrial flutter and atrial fibrillation. *Circulation* 2003;108:2479-83.
150. Lee WC, Fang HY, Chen HC et al. Additional cavotricuspid isthmus block ablation may not improve the outcome of atrial fibrillation ablation. *Pacing Clin Electrophysiol* 2019;42:1421-1428.
151. WANG Y-L, LIU X, TAN H-W et al. Evaluation of Linear Lesions in the Left and Right Atrium in Ablation of Long-standing Atrial Fibrillation. *Pacing and Clinical Electrophysiology* 2013;36:1202-1210.
152. Mohanty S, Gianni C, Trivedi C et al. Impact of rotor ablation in non-paroxysmal AF patients: Findings from the per-protocol population of the OASIS trial at long-term follow-up. *Am Heart J* 2018;205:145-148.
153. Brachmann J, Hummel JD, Wilber DJ et al. Prospective randomized comparison of rotor ablation vs conventional ablation for treatment of persistent atrial fibrillation—The REAFFIRM trial. *Heart Rhythm* 2019;16:963-965.
154. Peigh G, Wasserlauf J, Kaplan RM et al. Abstract 15877: Focal Impulse Rotor Modulation Guided Ablation versus Isolated Repeat Pulmonary Vein Isolation of Non-Paroxysmal Atrial Fibrillation After Failed Pulmonary Vein Isolation: A Case Control Study. *Circulation* 2019;140:A15877-A15877.
155. Kirzner JM, Raelson CA, Liu CF et al. Effects of focal impulse and rotor modulation-guided ablation on atrial arrhythmia termination and inducibility: Impact on outcomes after treatment of persistent atrial fibrillation. *J Cardiovasc Electrophysiol* 2019;30:2773-2781.
156. Rolf S, Kircher S, Arya A et al. Tailored Atrial Substrate Modification Based on Low-Voltage Areas in Catheter Ablation of Atrial Fibrillation. *Circulation: Arrhythmia and Electrophysiology* 2014;7:825-833.
157. Jadidi AS, Lehrmann H, Keyl C et al. Ablation of Persistent Atrial Fibrillation Targeting Low-Voltage Areas With Selective Activation Characteristics. *Circulation: Arrhythmia and Electrophysiology* 2016;9:e002962.
158. Mikhaylov E, Kanidieva A, Sviridova N et al. Outcome of anatomic ganglionated plexi ablation to treat paroxysmal atrial fibrillation: a 3-year follow-up study. *Europace* 2011;13:362-70.

159. Kim T-H, Park J, Park J-K et al. Linear ablation in addition to circumferential pulmonary vein isolation (Dallas lesion set) does not improve clinical outcome in patients with paroxysmal atrial fibrillation: a prospective randomized study. *EP Europace* 2014;17:388-395.
160. Lim TW, Koay CH, See VA et al. Single-Ring Posterior Left Atrial (Box) Isolation Results in a Different Mode of Recurrence Compared With Wide Antral Pulmonary Vein Isolation on Long-Term Follow-Up. *Circulation: Arrhythmia and Electrophysiology* 2012;5:968-977.
161. Sutter JS, Lokhnygina Y, Daubert JP et al. Safety and efficacy outcomes of left atrial posterior wall isolation compared to pulmonary vein isolation and pulmonary vein isolation with linear ablation for the treatment of persistent atrial fibrillation. *Am Heart J* 2020;220:89-96.
162. Aryana A, Baker JH, Espinosa Ginic MA et al. Posterior wall isolation using the cryoballoon in conjunction with pulmonary vein ablation is superior to pulmonary vein isolation alone in patients with persistent atrial fibrillation: A multicenter experience. *Heart Rhythm* 2018;15:1121-1129.
163. Wang XH, Liu X, Sun YM, Shi HF, Zhou L, Gu JN. Pulmonary vein isolation combined with superior vena cava isolation for atrial fibrillation ablation: a prospective randomized study. *Europace* 2008;10:600-5.
164. Da Costa A, Levallois M, Romeyer-Bouchard C, Bisch L, Gate-Martinet A, Isaaz K. Remote-controlled magnetic pulmonary vein isolation combined with superior vena cava isolation for paroxysmal atrial fibrillation: a prospective randomized study. *Arch Cardiovasc Dis* 2015;108:163-71.
165. Heeger CH, Rillig A, Geisler D et al. Left Atrial Appendage Isolation in Patients Not Responding to Pulmonary Vein Isolation. *Circulation* 2019;139:712-715.
166. Panikker S, Jarman JW, Virmani R et al. Left Atrial Appendage Electrical Isolation and Concomitant Device Occlusion to Treat Persistent Atrial Fibrillation: A First-in-Human Safety, Feasibility, and Efficacy Study. *Circulation Arrhythmia and electrophysiology* 2016;9.

Evidence Scoring system

Only observational studies (OS), propensity scored (PS) studies, randomized controlled trials (RCT), and meta-analysis (MA) of ablation strategies for PAF and non-PAF were included. OS, PS and MA were excluded if there was no PVI only control group for comparison. For the meta-analyses, only the largest and/or latest published were included.

A positive score favors technique implementation, while a negative score indicates that there are no additional benefits with the approach. AF evidence-based scores were calculated by considering the different weights of the studies, as described below.

- OS (yellow) were scored as +1/-1
- PS studies (gold) were scored as +2/-2. Additional points were given depending on the interventional arm population (+1/-1 if < 500 patients, +2/-2 if between 500-1000 patients, or +3/-3 if > 1000 patients).
- RCT (orange) were scored as +3/-3. Additional points were given depending on the interventional arm population (+1/-1 if < 100 patients, +2/-2 if between 100-200 patients, or +3/-3 if > 200 patients).
- MA (red) was scored as +2/-2 if only included OS; +3/-3 if included RCTs and OS; +4/-4 if included RCT, PS and OS; +5/-5 if only included RCT. If it included only RCTs, additional points were given depending on the interventional arm population (+1/-1 if < 500 patients, +2/-2 if between 500-1000 patients, or +3/-3 if > 1000 patients).

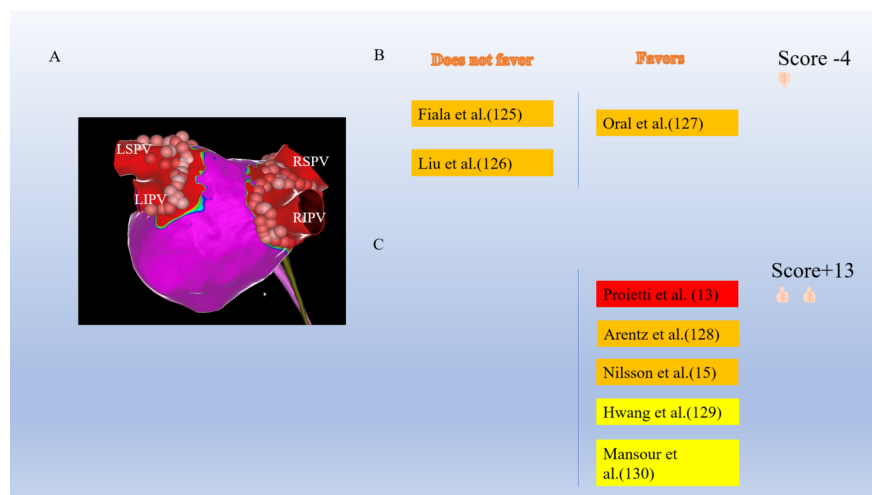


Fig. 1 A: Electroanatomical map of left atrium showing PVI. Studies comparing WACA versus ostial PVI in B: PAF (125-127)C: PAF and non-PAF(13,15,128-130)

LSPV; left superior pulmonary vein, LIPV; left inferior pulmonary vein, RSPV; right superior pulmonary vein, RIPV; right inferior pulmonary vein, WACA; wide antral catheter ablation, PVI; pulmonary vein isolation

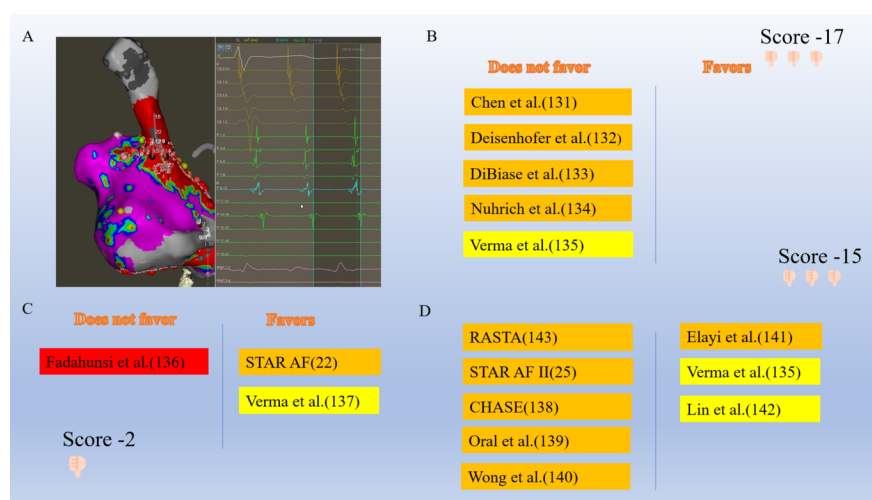


Fig. 2 A: Complex fractionated atrial electrogram (CFAE) ablation. Studies comparing CFAE with PVI in B: PAF(131-135), C: PAF and non-PAF(22,136,137), D: non-PAF only (25,135,138-143)

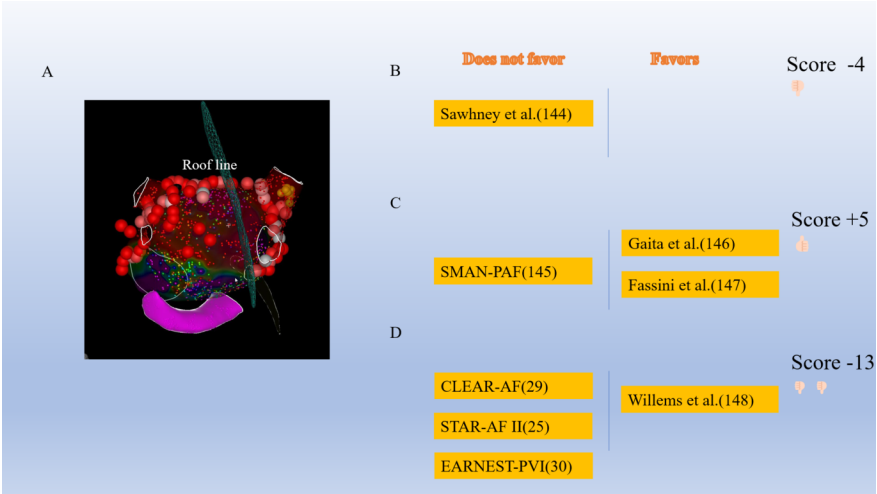


Fig. 3 A: Electroanatomical map showing roof line ablation. Studies comparing additional linear lesions with PVI in B: PAF(144), C: PAF and non-PAF(145-147), D: non-PAF only(25,29,30,148)

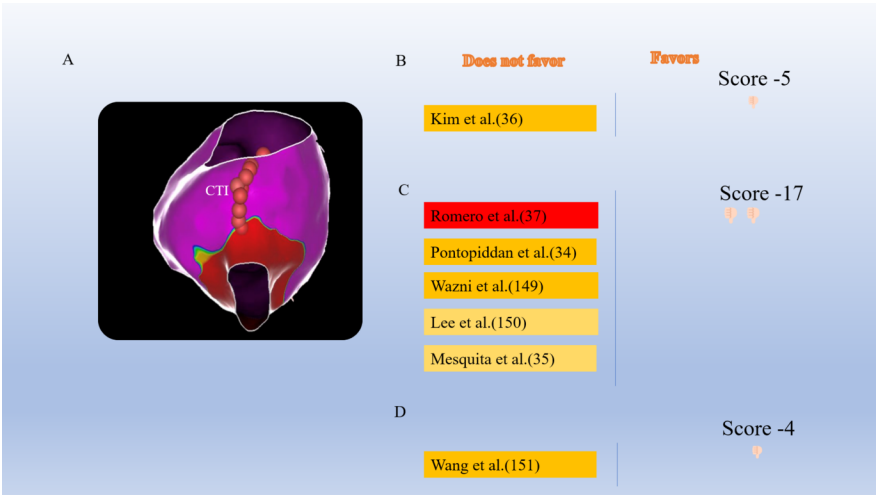


Fig. 4 A: Electroanatomical map showing cavo-tricuspid isthmus (CTI) line ablation. Studies comparing CTI ablation with PVI in B: PAF(36), C: PAF and non-PAF(34,35,37,149,150), D: non-PAF only(151)

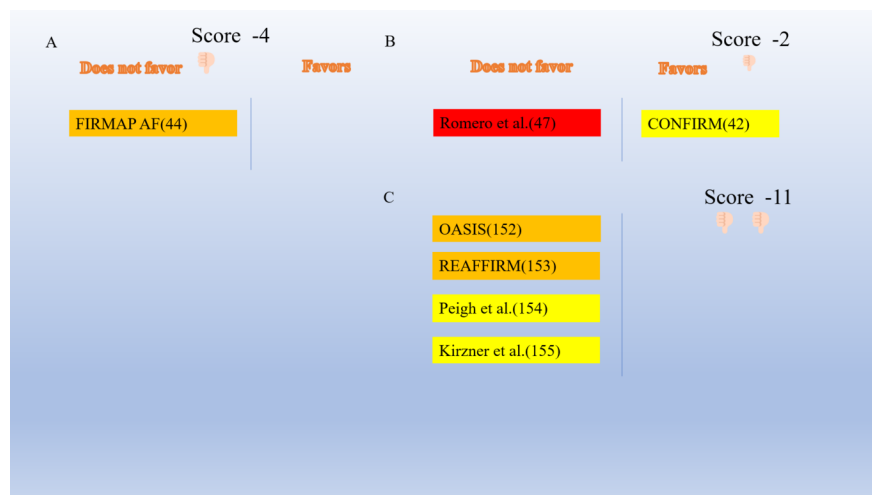


Fig. 5 Studies comparing rotor ablation with PVI in A: PAF(44), B:PAF and non-PAF(42,47), C: non-PAF only(152-155)

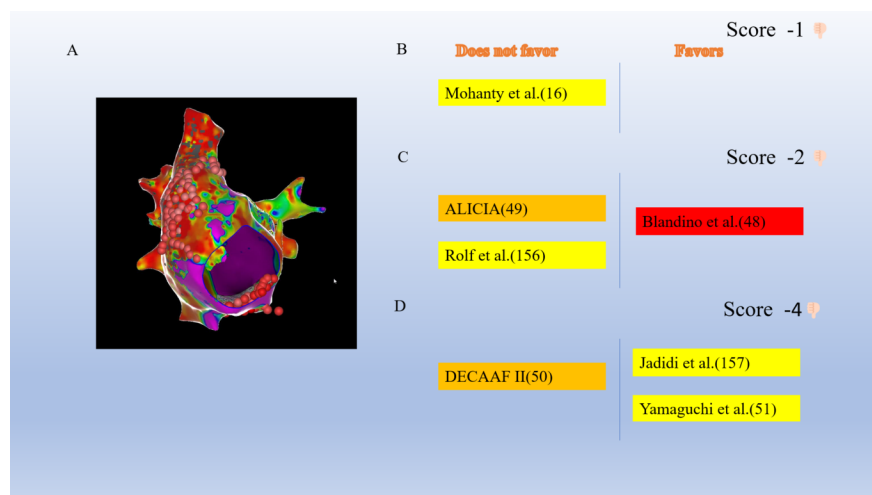


Fig. 6 A: Scar tissue ablation. Studies comparing ablation of scar tissue with PVI in B: PAF(16), C: PAF and non-PAF(48,49,156), D: non-PAF only(50,51,157)

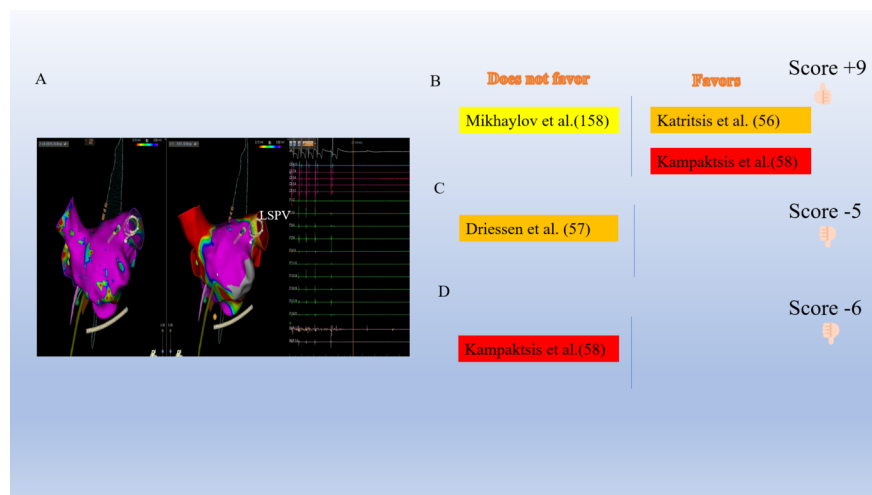


Fig. 7 A: Ganglionated plexi ablation. Studies comparing GP ablation with PVI in B: PAF(56,58,158), C: PAF and non-PAF(57), D: non-PAF only(58)

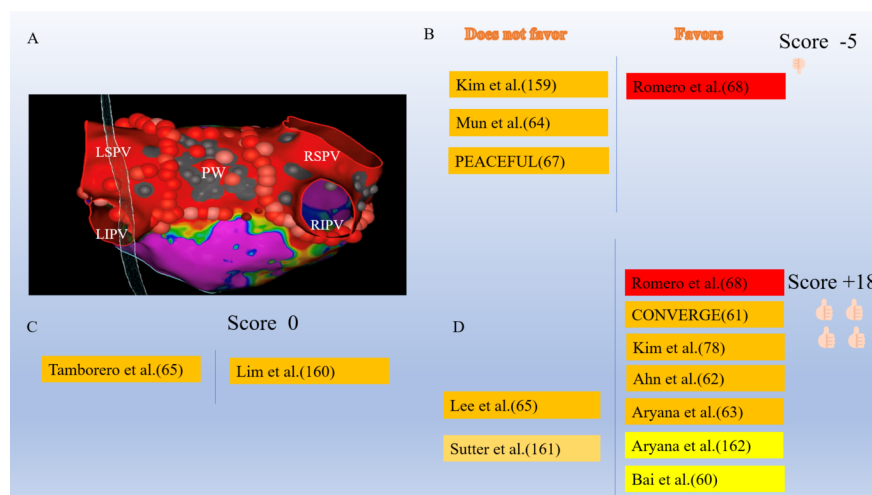


Fig. 8 A: Electroanatomical map showing posterior wall and pulmonary vein isolation. Studies comparing PWI with PVI in B: PAF(64,67,68,159) C: PAF and non-PAF(65,160), D: non-PAF only(60-63,66,68,78,161,162)

LSPV; left superior pulmonary vein, LIPV; left inferior pulmonary vein, RSPV; right superior pulmonary vein, RIPV; right inferior pulmonary vein; PW, posterior wall

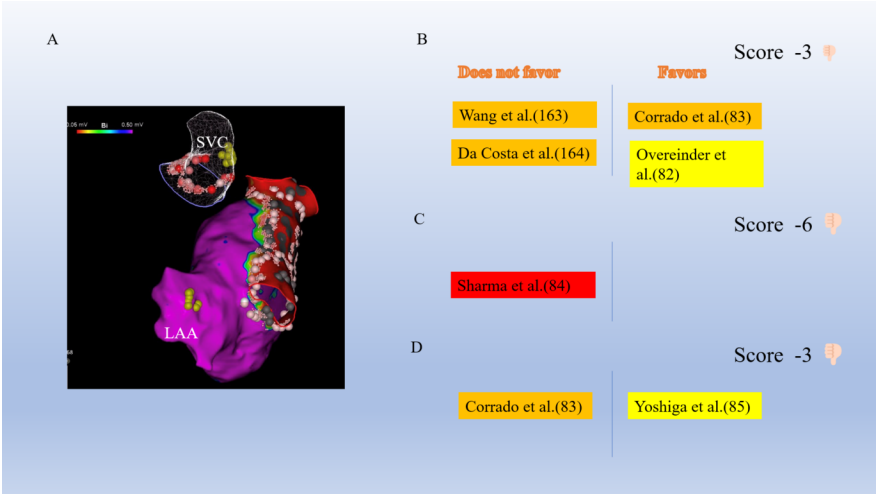


Fig. 9 A: Electroanatomical map superior vena cava isolation. Studies comparing SVCI with PVI in B: PAF(82,83,163,164), C: PAF and non-PAF(84), D: non-PAF only(83,85)
SVC; superior vena cava, LAA; left atrial appendage

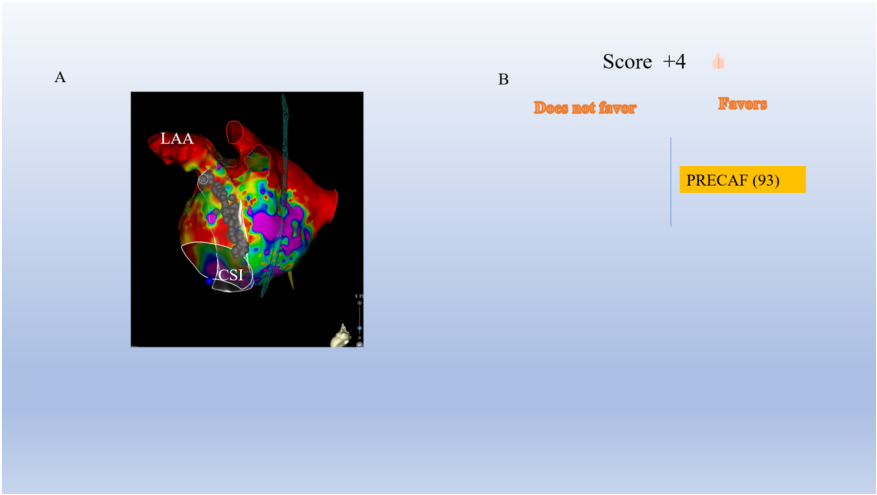


Fig. 10 A: Post ablation electroanatomical map showing coronary sinus isolation (CSI) B: Study comparing CSI with PVI and non-PV trigger ablation(93) LAA; left atrial appendage, CS; coronary sinus

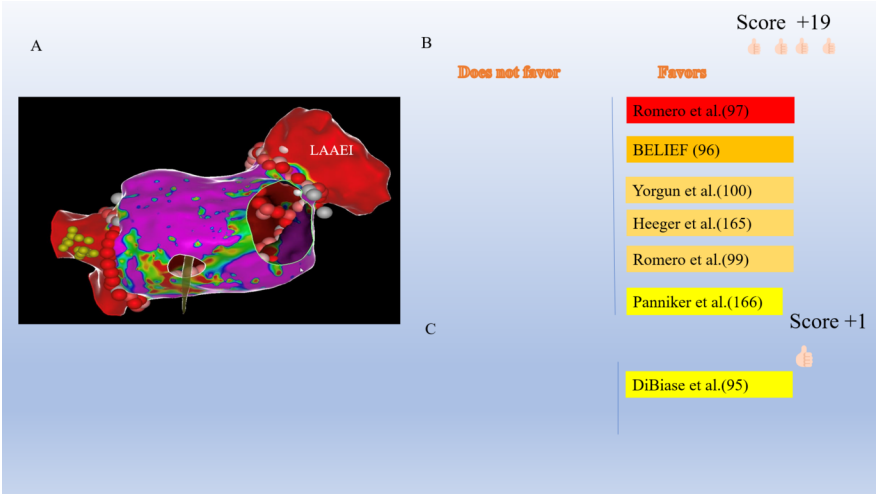


Fig.11 A: Electroanatomical map showing left atrial appendage electrical isolation. Studies comparing LAAEI with PVI in B: non-PAF(96,97,99,100,165,166), C: PAF and non -PAF(95) LAAEI; left atrial appendage electrical isolation

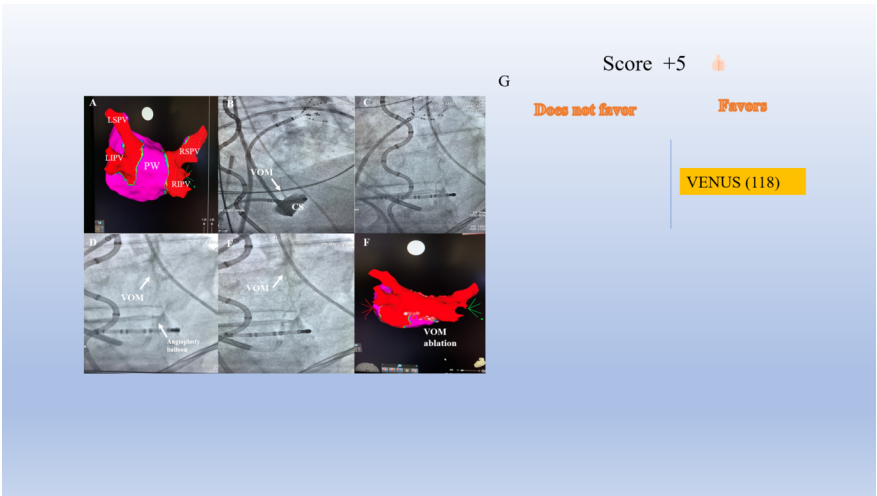


Fig.12 A: Electroanatomical map before ethanol infusion of vein of Marshall (VOM) showing isolated pulmonary veins. B: VOM originating from coronary sinus (CS) on right anterior oblique fluoroscopic view C: Wire placement D: VOM visualization E: Ethanol injection into VOM F: Electroanatomical map of left atrium post VOM ethanol infusion G: VENUS trial in favor of VOM ethanol infusion(118).