

Biologics and Airway Remodeling in Severe Asthma

Gilda Varricchi¹, Sebastian Ferri², Jack Pepys², Remo Poto¹, Giuseppe Spadaro¹, Nappi Emanuele², Giovanni Paoletti², Christian Virchow³, Enrico Heffler², and Giorgio Walter Canonica²

¹Università degli Studi di Napoli Federico II Dipartimento di Scienze Mediche Traslazionali

²Humanitas University

³Universitätsmedizin Rostock Abteilung Pneumologie und Interdisziplinäre Internistische Intensivmedizin

April 25, 2022

Abstract

Asthma is a chronic inflammatory airway disease resulting in airflow obstruction, which in part can become irreversible to conventional therapies, defining the concept of airway remodeling. The introduction of biologics in severe asthma has led in some patients to the complete normalization of previously considered irreversible airflow obstruction. This highlights the need to distinguish a “fixed” bronchial obstruction due to structural changes unresponsive to current therapies, from a “reversible” one as demonstrated by lung function normalization during biological therapies not previously obtained even with high dose systemic glucocorticoids. The mechanisms by which exposure to environmental factors initiates the inflammatory responses that trigger airway remodeling are still incompletely understood. Alarmins represent tissue-derived cytokines that initiate immunologic events leading to inflammatory airway remodeling. Biological therapies can improve airflow obstruction by addressing these airway inflammatory changes. In addition, biologics might prevent and possibly even revert “fixed” remodeling due to structural changes. Hence, it appears clinically important to separate the therapeutic effects (early and late) of biologics as a new paradigm to evaluate the effects of these drugs and future treatments on airway remodeling in severe asthma.

Introduction

Asthma is a heterogeneous chronic inflammatory disease of the respiratory system that affects approximately 10% of adults¹. A typical feature of asthma is a variable airflow limitation associated with symptoms such as dyspnoea, cough, wheezing and chest tightness². The heterogeneity of the immunologic disorder is reflected in different phenotypes that differ in etiology, pathogenic mechanisms, symptoms, and severity³. Based on airway inflammation, asthma has been subdivided into type 2-high (T2-high) and -low (T2-low), although the latter form is rare in clinical practice³⁻⁵. A similar distinction is made between eosinophilic and non-eosinophilic asthma (GINA 2021)⁶. Severe asthma is defined as asthma that is not well controlled despite the administration of high-dose drug therapy⁷. Up to 10% of asthma patients have severe asthma, with a reduced quality of life, and increased risk of exacerbations, hospitalizations, and death^{8, 9}.

In T2-high asthma, immunologic stimuli (e.g., allergens, viral and bacterial superantigens) activate primary effector cells of allergic disorders (i.e., mast cells, basophils) through the engagement of specific IgE to release a plethora of interleukins (ILs) (e.g., IL-3, IL-4, IL-5, IL-13)^{10, 11}. Eosinophils and their mediators contribute to the pathogenesis of allergic asthma and play pivotal roles in eosinophilic asthma. T2-low asthma is heterogeneous, incompletely defined and understood and presumably includes different phenotypes characterized by the involvement of mast cells, macrophages, neutrophils and/or a mixture of these immune cells^{3,5}. Bronchial epithelial cell-derived alarmins (e.g., TSLP, IL-33 and IL-25) are upstream cytokines that initiate immunologic events culminating in airway remodeling¹²⁻¹⁴. The latter is a complex process

requiring a timely expression of fibrogenic¹⁵ and angiogenic factors causing profound structural alterations of the bronchial walls and blood vessels^{16, 17}. These alterations contribute to the reduction of airway caliber and stiffening, resulting clinically in airflow limitations and respiratory symptoms¹⁸.

Airway remodeling

Airway remodeling can affect both large and small airways¹⁹ and is characterized by structural changes including goblet cell hyperplasia, subepithelial matrix protein deposition and fibrosis, overexpression of angiogenic factors, and hyperplasia/hypertrophy of airway smooth muscle (ASM) cells^{15-17, 20, 21}. Increased deposition of extracellular matrix (ECM) proteins in the reticular basement membrane (RBM), lamina propria, and submucosa is a characteristic of asthmatic airways and contributes to the airway wall thickening and airflow obstruction^{22, 23}. Collagen fibers, fibronectin and tenascin are the most abundant elements of the ECM in the asthmatic lung²⁴⁻²⁷. Aberrant accumulation of ECM proteins leads to alterations in tissue structure and function, contributing to airway remodeling in asthma²⁸⁻³⁰. ASM hypertrophy/hyperplasia (e.g., increased ASM mass) are features of asthmatic airway remodeling^{18, 31, 32, 33}. ASM cells in asthmatic individuals also produce increased amounts of collagen and fibronectin^{34, 35}. The increase in the ASM mass is responsible for bronchial obstruction³⁶, loss of function²⁰ and greater susceptibility to external triggers³⁷⁻³⁹.

Angiogenesis is fundamental to providing the blood vessels to maintain tissue homeostasis⁴⁰, whereas inflammatory angiogenesis is a critical factor in the development of a disease process⁴¹⁻⁴³. Blood vessel density and vascular area are increased in patients with asthma^{16, 17}. Another feature of asthma is goblet cell hyperplasia, mucin overproduction and mucus hypersecretion⁴⁴. Figure 1 schematically illustrates the fundamental characteristics of the normal bronchial airway and the main features of airway remodeling in asthma.

A plethora of cytokines [transforming growth factor β (TGF- β), platelet-derived growth factor (PDGF), fibroblast growth factor (FGF), epidermal growth factor (EGF)], vascular endothelial growth factors (VEGFs) and chemokines (e.g., CXCL2, CXCL3, IL-8/CXCL8) contribute directly and indirectly to airway remodeling in asthma⁴⁵⁻⁴⁷. TGF- β , produced by macrophages and eosinophils, is a main mediator responsible for airway remodeling by inducing epithelial-mesenchymal transition (EMT)⁴⁸.

IL-4 activates ASM cells, causing an increase in actin and collagen synthesis as well as TGF- β release by the bronchial epithelium^{37, 49}. IL-5, on the other hand promotes subepithelial and peri-bronchial fibrosis through the recruitment and activation of eosinophils, a major source of TGF- β ^{50, 51}. IL-13 induces the release of TGF- β which increases goblet cell hyperplasia and thus mucus hypersecretion^{37, 52-54}.

Human eosinophil granules are armed with cytotoxic major basic protein (MBP), eosinophil peroxidase (EPX), eosinophil cationic protein (ECP), eosinophil derived neurotoxin (EDN), and galactin-10 (also known as Charcot-Leyden protein)⁵⁵. ECP and MBP induce the release of preformed (histamine and tryptase) and *de novo* synthesized mediators (prostaglandin D₂: PGD₂) from human mast cells⁵⁶. Activated human eosinophils secrete LTC₄ and a wide array of type 2 cytokines (i.e., IL-5, IL-4, IL-13) and TGF- β ^{45, 57}. Altogether, current data indicate that eosinophils play a globally pathogenic role in airway remodeling.

Macrophages are the predominant immune cells in human lung parenchyma⁵⁸ and are involved in immune responses as well as tissue remodeling⁵⁹. Human lung macrophages (HLMs) contribute to airway remodeling through the release of TGF- β , matrix metalloproteinases (MMPs), angiogenic (VEGF-A, ANGPT2) and lymphangiogenic factors (i.e., VEGF-C)^{60, 61}. Human lung mast cells (HLMCs) are important lung-resident immune cells involved in asthmatic airway remodeling⁶². IgE- and non-IgE-mediated activation of HLMCs induces the release of several pro-fibrotic cytokines (e.g., IL-13 and TNF- α), as well as inflammatory mediators (e.g., PGD₂ and tryptase)⁶³. Tryptase induces fibroblast, endothelial and epithelial cell proliferation, further fueling airway remodeling in asthmatic individuals⁶⁴. Neutrophils have also been shown to produce MMP-9^{65, 66}, angiogenic factors⁴⁰ and neutrophil extracellular traps (NETs)⁶⁷ and can be associated with severe asthma⁶⁷.

The airway epithelium is a key component of the innate immune system and the initiator of airway remodeling in asthma¹⁴. A plethora of environmental insults (e.g., allergens, cytokines, microbial proteins, smoke

extracts, chemical and physical insults) damage and/or activate epithelial cells to release several cytokines, including TSLP^{13, 68}, IL-33^{14, 69}, IL-25/IL-17E¹², TGF- β and granulocyte-macrophage colony-stimulating factor (GM-CSF), which can recruit dendritic cells (DCs), mast cells and other immune cells⁷⁰.

Thymic stromal lymphopoietin (TSLP), constitutively expressed by human bronchial epithelial cells⁷¹⁻⁷⁴, can be rapidly released as a result of cell injury in response to a variety of inflammatory stimuli^{71, 75-79}. TSLP is also released by DCs⁸⁰, mast cells⁸¹, HLMs⁶⁰, and fibroblasts^{82, 83}. There are two isoforms of TSLP: the short (sf) and the long (lf) isoforms. The latter is expressed at a low or undetectable level at steady state, but its expression increases during inflammation^{60, 84}. For instance, house dust mites induce lfTSLP but not sfTSLP in human bronchial epithelial cells⁸⁵. TSLP immunostaining is increased in the airway epithelium in asthmatic patients⁷⁴ and its concentrations are increased in the broncho-alveolar lavage (BAL) fluid of asthmatics⁷³. Moreover, bronchial allergen challenge of asthmatics increases the expression of TSLP⁺ cells in the epithelium and submucosa⁷². TSLP is overexpressed in the airways of severe asthma patients⁷³ and exerts its effects by binding to a high-affinity heterodimeric receptor complex composed of TSLPR and IL-7R α ¹³.

TSLP plays a role in airway remodeling⁸⁶ by promoting the differentiation of Th2 cells and innate lymphoid cells (ILCs)¹³ and the induction of epithelial-mesenchymal transition (EMT) in airway epithelial cells⁸⁷. Human lung fibroblasts are also a significant source of TSLP^{83, 88}. Through an autocrine mechanism, TSLP can activate human lung fibroblasts⁸⁹ to release type I collagen⁹⁰ and promote the proliferation of ASM cells⁹¹. TSLP has also been shown to cause goblet cell hyperplasia and mucus production⁹²⁻⁹⁴. TSLP activates human eosinophils¹³, mast cells^{81, 95} and HLMs⁶⁰. The multiple activating properties of TSLP on a plethora of immune and structural cells indicate that this cytokine plays a role in T2-high and T2-low asthma.

IL-33, an IL-1 superfamily alarmin released by airway epithelial cells and endothelial cells⁹⁶, activates the ST2 receptor on several cells of the innate and the adaptive immunity⁹⁶. Epithelial cell-derived IL-33 induces type 2 cytokines (i.e., IL-5 and IL-13) in human mast cells⁹⁷, collagen and fibronectin release from airway fibroblasts^{98, 99}. Collectively, IL-33 and IL-33/ST2 signaling pathways might be involved in both airway inflammation and asthma remodeling through the activation of several immune and structural cells.

IL-25, also known as IL-17E, is a unique cytokine of the IL-17 family produced by airway epithelial cells¹². Airborne allergens, ATP, and viral infections upregulate IL-25 and its receptor IL-17RB in airway epithelial cells and submucosa^{100, 101}. IL-25 modulates EMT of alveolar epithelial cells and local tissue remodeling¹⁰² and upregulates cytokine expression in lung fibroblasts¹⁰³. IL-25 drives lung fibrosis in several mouse models^{102, 104, 105}.

Finally, IgE itself could play a role in airway remodeling by stimulating the production of interleukins¹⁰⁶. Several investigators have reported that human monomeric IgE, in the absence of cross-linking, can induce the release of cytokines (e.g., IL-4) and chemokines (e.g., CXCL8) from mast cells^{107, 108}. Moreover, Roth *et al.* have shown that *in vitro* incubation of serum containing IgE obtained from allergic asthmatics caused ASM proliferation and marked production of type I collagen¹⁰⁹.

A recent study in a mouse model of asthma demonstrated dynamic changes in the respiratory microbiota at different stages of the disease. In particular, *Staphylococcus* and *Cupriavidus* were more abundant during airway remodeling¹¹⁰. Additional studies are urgently needed to investigate whether the dysbiosis of airway microbiota could also play a role in the progression from allergic inflammation to airway remodeling in humans.

Airway remodeling can sometimes cause irreversible airflow limitation with consequent poor symptom control and lack of response to treatment^{20, 111, 112}.

Targeting airway remodeling

Experimental and human studies have demonstrated that glucocorticoids and certain anti-inflammatory drugs can reduce inflammation and morbidity in mild to moderate asthma. However, evidences of beneficial

effects of glucocorticoids on airway remodeling have not been demonstrated, with several reports showing contradictory results^{17, 113, 114}. The introduction of several biological immunotherapies (e.g., anti-IgE, anti-IL-5/IL-5R α , anti-IL-4R α , anti-TSLP)^{2, 115} has favored the development of a personalized medicine approach for the treatment of patients with severe asthma¹¹⁶⁻¹¹⁹. There is some evidence that these biologics can improve not only clinical symptoms but also certain features of airway remodeling and functional decline of FEV₁. Therefore, it will be important to evaluate the effects of biological immunotherapies in randomized clinical trials (RCTs) and real-life settings^{120, 121}.

Omalizumab

Omalizumab is a humanized IgG1/ κ monoclonal antibody (mAb) that binds to the Fc fragment of IgE¹²². This mAb inhibits binding of IgE to the high-affinity IgE (Fc ϵ RI) receptor on human mast cells and basophils^{123, 124}. Several studies have documented the efficacy of omalizumab in improving allergic asthma and reducing symptoms and exacerbations¹²⁵⁻¹²⁷ also in children and pregnant women¹²⁸⁻¹³⁰. Although omalizumab did not cause FEV₁ improvement in RCTs^{131, 132}, there is some evidence that this mAb can improve FEV₁ in real-life settings^{133, 134} and can reduce the thickness of the basement membrane^{135, 136} and fibronectin deposits in asthmatic airways¹³⁷ in addition to preventing exacerbation-induced inflammatory alterations in the airways. IgE-containing serum from asthmatic patients stimulated *in vitro* mesenchymal cell proliferation and accumulation of collagen and fibronectin. Both proliferation and matrix deposition were prevented by preincubation of the cells with omalizumab¹⁰⁹.

Mepolizumab

Mepolizumab is an IgG1- κ anti-IL-5 mAb approved as add-on treatment for severe eosinophilic asthma (SEA)^{138, 139}. IL-5 is the most important growth, differentiation, and activation factor of human eosinophils¹⁴⁰. This cytokine acts on eosinophils by binding to the specific IL-5 receptor (IL-5R), which consists of an IL-5 receptor α (IL-5R α) subunit and the common receptor β subunit (β c)¹⁴¹. IL-5, together with IL-3 and GM-CSF, is crucial for the maturation of human eosinophils in the bone marrow^{141, 142}. IL-5 is mainly produced by type-2 ILC2s, Th2 cells, mast cells, invariant NKT cells, and eosinophils themselves¹⁴⁰. Human eosinophils can also be activated by IL-33⁹⁶ and TSLP¹³.

The efficacy and safety of mepolizumab have been demonstrated in several RCTs¹⁴³⁻¹⁴⁶. The DREAM study, conducted with mepolizumab at 3 different doses administered intravenously (*i.v.*), showed the clinical efficacy but there were no statistically significant changes in FEV₁, although there was an improvement, compared to baseline, in FEV₁ in the mepolizumab group *versus* placebo¹⁴³. In the MENSA study, the FEV₁ increase was rapid, starting from the first administration, and persisted over time¹⁴⁶. Two additional studies showed a rapid and long-lasting improvement in pre-bronchodilator FEV₁ in the mepolizumab group compared to placebo^{147, 148}. There is some evidence that mepolizumab can also improve FEV₁ in real-life settings¹⁴⁹⁻¹⁵¹.

Interestingly, some patients first enrolled in the COSMOS study and subsequently in the long-term COSMEX study, with a suspension of more than 12 weeks of mepolizumab between the two, reported a transient worsening of their symptoms and FEV₁, which rapidly improved upon reintroduction of mepolizumab¹⁴⁵. A clinical trial (NCT03797404) is evaluating the effects on airway remodeling during mepolizumab treatment.

In a pioneering study, Flood-Page and collaborators examined the bronchial biopsies of mild atopic asthmatic patients obtained before and after treatment with three mepolizumab infusions⁵⁷. They demonstrated that the thickness and density of tenascin in the RBM, the airway TGF- β 1⁺ eosinophils and the BAL concentrations of TGF- β 1 were increased in mild asthmatic patients compared to normal subjects. As expected, mepolizumab reduced bronchial eosinophil numbers but also TGF- β 1⁺ eosinophils, thickness and tenascin immunoreactivity and the concentration of TGF- β 1 in BAL fluid⁵⁷.

Reslizumab

Reslizumab is a humanized IgG4- κ anti-IL-5 mAb developed by drafting technology from a rat mAb with high affinity against human IL-5¹⁵². Reslizumab binds to a small region corresponding to amino acids 89-92

of IL-5, which are critical for binding to IL-5R α ¹⁵³. Reslizumab administration results in clinical improvement in asthma and an increase in FEV₁ in patients with eosinophilic counts > 400 cells/ μ L compared to placebo¹⁵³⁻¹⁵⁸. Apparently contrasting results have been reported on the effects of reslizumab on the improvement of FEV₁ compared to placebo. Although several studies reported that reslizumab significantly improved FEV₁ compared to placebo^{154, 157}, other investigators found that reslizumab had no improvement in FEV₁ compared to those receiving placebo¹⁵⁴. A real-life study recently confirmed the efficacy of reslizumab treatment in reducing the number of exacerbations and increasing FEV₁ 6 months after the beginning of treatment¹⁵⁹.

Benralizumab

Benralizumab is a humanized, afucosylated IgG1- κ mAb that targets the α subunit of the IL-5 receptor (IL-5R α) and it binds with high affinity to the main Fc receptor for IgG expressed by natural killer (NK) cells, macrophages and neutrophils, which results in eosinophil apoptosis *via* antibody-dependent cell-mediated cytotoxicity¹⁶⁰. Several studies have demonstrated that benralizumab administration leads to subjective and functional clinical improvement in patients with SEA. RCTs, reported an improvement in FEV₁ at 12 weeks from the beginning of treatment¹⁶¹⁻¹⁶³. A post-hoc analysis conducted on SIROCCO and CALIMA data further documented that benralizumab promoted functional improvement even in patients with fixed obstruction, an alteration found in approximately 16% of patients with severe asthma¹⁶⁴. A recent study extended the previous results by showing that benralizumab caused a rapid (4 weeks) improvement in FEV₁, which increased after 12 weeks and persisted throughout the period (24 weeks) of observation¹⁶³.

Cachi and collaborators evaluated the effects of benralizumab on airway remodeling examining biopsies from patients with SEA¹⁶⁵. Benralizumab reduced the number of eosinophils in the bronchial lamina propria and ASM mass compared to placebo. In the benralizumab group, there were no significant changes in the number of myofibroblasts compared to the control group. The effects of benralizumab on ASM mass were attributed to an indirect effect mediated by the depletion of local TGF- β 1⁺ eosinophils in the bronchial lamina propria.

Pelaia and collaborators emphasized the clinical efficacy of benralizumab in terms of lung function in real life after the first administration of this mAb¹⁶⁶. Padilla-Galo *et al.* reported an improvement in FEV₁ after three months of treatment with benralizumab, which lasted up to six months¹⁶⁷. Similar results were obtained in a retrospective study¹⁶⁸. The authors ascribed the rapid improvement of lung function to the early effects of the mAb on peripheral blood and bronchial eosinophils. Although these observations were obtained in small cohorts of patients, they emphasize that the improvement caused by benralizumab on lung function observed in real life is more evident compared to certain RCTs^{92, 161, 162}. Finally, clinical trials (NCT04365205, NCT03953300) are evaluating the effects of benralizumab on airway remodeling.

Dupilumab

The Th2-like cytokines IL-4 and IL-13 and the heterodimeric IL-4 receptor (IL-4R) complexes that they activate play a key pathogenic role in asthma¹⁶⁹. Dupilumab is a human IgG4 mAb that targets the IL-4 receptor α chain (IL-4R α), common to both IL-4R complexes: type 1 (IL-4R α / γ c; IL-4 specific) and type 2 (IL-4R α /IL-13R α 1; IL-4 and IL-13 specific)¹⁷⁰.

In several RCTs, dupilumab reduced the annualized rate of asthma exacerbations in patients with moderate-to-severe uncontrolled asthma compared to placebo¹⁷¹⁻¹⁷³. Dupilumab in patients with severe asthma caused rapid (2 weeks) and long-lasting improvement in FEV₁ *versus* placebo^{172, 173}. Furthermore, the trend curves of FEV₁ post bronchodilation showed a loss of function in the placebo group and no decrease in FEV₁ over time in the dupilumab group. The latter findings suggest that dupilumab might exert a positive effect on structural airway remodeling. Moreover, in a mouse model of asthma, dual IL-4/IL-13 blockade with dupilumab prevented eosinophil infiltration into lung tissue without affecting circulating eosinophils¹⁷⁴. A real-life retrospective study demonstrated that 4 weeks of treatment were necessary to achieve a significant improvement in FEV₁ compared to baseline¹⁷⁵.

It should be noted that blood eosinophilia was reported in 4 to 25% of patients in the dupilumab group

compared to 0.6% in the placebo group^{173, 176}. This paradoxical effect has also been reported in patients treated with dupilumab for moderate-to-severe atopic dermatitis¹⁷⁷.

The VESTIGE study (NCT04400318), evaluating dupilumab effects on lung function and structural airway changes using functional respiratory imaging (FRI), is ongoing.

Additionally, indirect evidence of a combined anti-inflammatory effect as well as on tissue and structural cells can be derived from the observation that all of the above mentioned anti-Th2 cytokine or receptor antibodies have been shown to reduce nasal polyposis in patients with chronic rhinosinusitis¹⁷⁸⁻¹⁸¹.

Tezepelumab

Tezepelumab is a human mAb, which binds with high affinity to TSLP, an epithelial cell-derived cytokine implicated in the pathogenesis of different phenotypes of asthma¹³. TSLP, a pleiotropic cytokine overexpressed in the airway epithelium of asthmatics⁷⁴, exerts its effects by binding to a high-affinity heterodimeric receptor complex composed of TSLPR and IL-7R α ¹³. TSLP concentrations are increased in BAL fluid of asthmatics⁷³ and bronchial allergen challenge increases TSLP expression in the asthmatic epithelium and submucosa. Importantly, serum concentrations of TSLP are increased during asthma exacerbations¹⁸². Finally, TSLP induces the release of angiogenic and lymphangiogenic factors from HLMS⁶⁰. TSLP can promote airway remodeling *via* the activation of human lung fibroblasts⁸⁹.

The FDA has recently approved tezepelumab for the treatment of severe asthma with no phenotype or biomarker limitations. Tezepelumab is the first of a new class of biologics that antagonize an alarmin (e.g., TSLP), which plays a pivotal role in the pathogenesis of asthma^{13, 68}. The phase II PATHWAY study showed that three different doses (70 mg, 210 mg, or 280 mg s.c. every 4 weeks) of tezepelumab reduced the number of annual exacerbation rates regardless of blood eosinophil count, with a significant increase in prebronchodilator FEV₁ at 52 weeks from the start of treatment compared to the placebo group¹⁸³. These results were extended in the phase III NAVIGATOR study in which tezepelumab (210 mg s.c. every 4 weeks) reduced asthma exacerbations at week 52 and significantly improved FEV₁ regardless of peripheral blood eosinophils in adolescent and adult patients with severe uncontrolled asthma¹⁸⁴ although there was a trend toward a better improvement with higher eosinophil counts in subgroup analysis.

Studies conducted in different animal models using TSLP antibodies have demonstrated that TSLP blockade reduces airway inflammation, TGF- β 1 levels, hyperreactivity and airway remodeling¹⁸⁵⁻¹⁸⁸. The phase II CASCADE study evaluated the effects of tezepelumab on airway remodeling by performing bronchoscopic biopsies in moderate-to-severe asthma patients¹⁸⁹. Tezepelumab caused a greater reduction from baseline to the end of treatment in airway submucosal eosinophils compared to placebo. There were no other significant changes either at the level of other immune cells (neutrophils, mast cells, and T cells) and at the structural level (e.g., RBM thickness, epithelial integrity). Interestingly, tezepelumab administration was associated with lower hyperresponsiveness to mannitol inhalation compared to placebo. The latter finding was confirmed in an independent study¹⁹⁰. These preliminary results on the effects of tezepelumab on airway remodeling are of translational interest for several reasons. There is overwhelming evidence that fibroblasts are a source of TSLP^{82, 83} and there is evidence that a functional TSLP signaling axis plays a role in fibrotic lung disease⁸³. Figure 2 schematically illustrates the mechanisms of action of different biologics and their immunological and cellular targets in the context of airway remodeling.

Future perspectives

Astegolimab

Astegolimab is an IgG2 mAb that blocks IL-33 signaling by targeting ST2, the IL-33 receptor⁹⁶. The phase 2b ZENYATTA study¹⁹¹ evaluated the safety and efficacy of astegolimab in patients with severe asthma. Astegolimab was safe, well tolerated, and effective in reducing the annualized asthma exacerbations at week 54. Astegolimab did not show a significant benefit compared to placebo in the absolute change in FEV₁ at week 54.

Itepekimab

Itepekimab is a human IgG4 anti-IL-33 mAb. A phase 2 trial compared the safety and efficacy of itepekimab (300 mg s.c. every 2 weeks), dupilumab (300 mg. s.c. every 2 weeks), itepekimab plus dupilumab, or placebo in patients with moderate-to-severe asthma¹⁹². The primary endpoint, loss of asthma control, was similar in the itepekimab (22%), combination (27%) and dupilumab (19%) groups and lower than in the placebo (41%) group. Pre-bronchodilator FEV₁ increased with itepekimab and dupilumab monotherapies but not with combination therapy. Ipetekimab improved asthma control and quality of life compared to placebo and reduced peripheral blood eosinophils. The latter results are consistent with a role for IL-33 in the pathogenesis of asthma exacerbations and airflow limitations in asthma. Further investigations are needed to investigate whether blockade of the IL-33/ST2 axis can modify airway remodeling in patients with asthma.

Imaging of airway remodeling

The direct assessment of human airway remodeling can be performed *in vivo* on bronchial biopsies in asthmatic patients^{57, 189, 193}. Bronchial biopsies identify useful information on bronchial and pulmonary alterations, such as thickening of the bronchial tissue, infiltration and density of inflammatory cells, aberrant accumulation of elements of ECM, and ASM hyperplasia and hypertrophy¹⁵. However, this procedure has several limitations that should be pointed out. First, it is not part of the routine clinical evaluation of asthmatic patients. Second, it does not easily facilitate serial biopsies in the same patient. Third, the results can be significantly influenced by the operator and the techniques used to assess tissue remodeling.

During the last decade, high-resolution computed tomography (HRCT) and nuclear magnetic resonance (NMR) are gaining a place as non-invasive techniques to examine different aspects of airway remodeling in asthma. Hoshino found increased airway wall thickening in asthmatics assessed by HRTC¹⁹⁴. Endobronchial ultrasound (EBUS) was higher in asthma patients than healthy controls¹⁹⁵. Hartley *et al.* found that the proximal airway wall area was increased in asthmatics compared to controls¹⁹⁶. The loss of the peripheral pulmonary vasculature, also termed pruning, was associated with asthma severity¹⁹⁷. Recently, Eddy and co-workers demonstrated that the total number of CT-visible airways was correlated to asthma severity¹⁹⁸.

Preliminary results derive from imaging studies that have evaluated the effects of biological therapies on airway remodeling using HRCT. Hoshino *et al.* reported that 16-week of treatment with omalizumab reduced the airway wall thickness and the number of sputum eosinophils¹³⁶. In another study, 48-week treatment with omalizumab reduced the airway wall area corrected for body surface, but no changes in percentage wall area, without changes in the luminal area¹⁹⁹. In two studies conducted by Haldar *et al.*^{200, 201} on airway remodeling by HRCT, it was found that the biological treatment determined a greater variation in pre/post treatment luminal area when compared to the placebo group. A recent study evaluated the impact of one-year mepolizumab therapy on airway remodeling through EBUS and HRTC. Improved airway remodeling (e.g., reduction in bronchial wall thickness) was better noticeable in invasive EBUS than in non-invasive HRCT²⁰². In the phase 2 CASCADE study, tezepelumab increased the CT scan-determined lumen area across airway generations¹⁸⁹.

Hyperpolarized helium-3 MRI of the lung has demonstrated regional heterogeneity of lobar ventilation in asthma²⁰³, which is correlated with asthma severity²⁰⁴. MRI ventilation defects (VDP) are correlated to sputum eosinophilia in severe asthma²⁰⁵ and are a predictor of exacerbation²⁰⁶. Collectively, studies with CT and MRI in asthma have shown some structural and functional changes in airways and pulmonary vasculature associated with more severe disease but are unable to differentiate between reversible and potentially irreversible changes.

Finally, fractional exhaled nitric oxide (FeNO) has been proposed to assess airway structure variations in asthma patients, especially in the distal airway. FeNO was associated with bronchial wall thickening in the third to the sixth generation of bronchial trees²⁰⁷.

Conclusions and perspectives

Immunotherapy with mAbs targeting IgE, several cytokines or their receptors has revolutionized the treatment landscape for patients with severe asthma. mAbs that block IgE (omalizumab), the IL-5/IL-5R α axis (mepolizumab, reslizumab, benralizumab), IL-4R α (dupilumab), or TSLP (tezepelumab) can produce durable responses in the majority of patients with severe asthma.

Airway remodeling is a cardinal feature of bronchial asthma and is responsible for structural alterations of the airways and lung parenchyma determining airway hyperresponsiveness and the development of fixed airflow obstruction¹⁵. Damaged epithelial barrier^{208, 209}, subepithelial matrix proteins and collagen deposition^{22,23, 27}, infiltration and activation of inflammatory cells^{57, 66,193}, goblet cell hyperplasia⁴⁴, overexpression of inflammatory angiogenesis^{16,17} and hyperplasia and hypertrophy of ASM cells^{18, 31} are major features of airway remodeling in asthma^{111, 210}.

At present, we have incomplete knowledge on the short- and long-term effects of biological therapies on airway remodeling in asthma. However, biological therapies targeting IgE, IL-5/IL-5R α , IL-4R α , TSLP and IL-33/ST2 can improve not only clinical symptoms but also certain features (e.g., FEV₁, FeNO) of airway remodeling in asthma^{173, 183,211-214}. These findings allow us to speculate that biologics could promote the resolution of allergic inflammation. Late phases of airway remodeling are associated with infiltration/activation of both pro-fibrotic immune cells (e.g., mast cells, eosinophils and macrophages) and structural cells (e.g., fibroblasts, myofibroblasts, ASM cells and endothelial cells). Biologics may have late effects on immune and structural cells in addition to early effects on airway inflammation. The effects of each biologic on specific features of airway remodeling are summarized in Table 1.

Biologics are presently used for the treatment of patients with severe asthma who are likely to have a prolonged history of persistent and/or repetitive immunological insults. Repetitive or prolonged injury can lead to a pathological state of fibrosis associated with reduced lung function. Experimental studies indicate that there is a limited-time window in which stopping inflammation avoids fibrosis. Beyond this time-window, tissue remodeling inevitably occurs even if inflammation is resolved. In this circuit, macrophages, the most abundant immune cells in the human lung, can transition between different states, including pro-inflammatory, anti-inflammatory, and pro-fibrotic states. Although there are no clinical and experimental data, we would like to hypothesize that perhaps early treatment of mild/moderate asthma with biologics might represent an innovative strategy to limit the irreversible airway remodeling of severe asthma.

There are several limitations in studying *in vivo* the effects of biological therapies on airway tissue remodeling in asthmatic patients. Bronchial asthma is a highly heterogeneous disorder and different forms of airway remodeling could likely underlie several asthma pheno-/endotypes³. The quantitative identification of immune cells in the airway epithelium and submucosa should also take in consideration the functional heterogeneity of eosinophils²¹⁵, macrophages^{60,193, 216}, mast cells^{41, 217-220}, neutrophils^{221, 222}, and basophils^{40, 223}. Potential airway remodeling biomarkers (e.g., galectin 3 and YKL40) are under investigation. Blood detection of these molecules, compared to invasive methods, could be useful in the future to evaluate bronchial remodeling²²⁴.

In conclusion, a deeper understanding of the immunological mechanisms of the formation of different forms of airway tissue remodeling in various asthma phenotypes is needed. The use of single-cell transcriptomics will be of paramount importance to chart the cellular landscape and specific signaling networks of upper and lower airways in healthy and asthmatic subjects¹⁹³. The results emerging from these studies could help in the generation of new reliable diagnostic biomarkers and targeted therapeutic approaches to improve asthma treatment.

Figure Legends

Figure 1 Schematic representation of normal airway (left side) and asthmatic airway remodeling (right side). In healthy subjects, ciliated epithelial cells function as both a physical barrier and an immunological organ that has evolved to defend living organisms against pathogens and physical insults, as well to maintain tissue homeostasis. Fibroblasts and macrophages contribute to tissue homeostasis in the submucosa. In severe asthma, several triggers (i.e., allergens, cytokines, cigarette smoke, microbial products, and physical insults)

damage bronchial epithelial cells that rapidly release several alarmins (i.e., TSLP, IL-33, IL-25/IL-17E) that are constitutively expressed. These alarmin cytokines are first reactor and rapidly initiate innate and adaptive immune responses in asthma. Asthma is associated with chronic inflammation and remodeling of the immune and stromal compartments of the airway wall^{208, 209}. Analysis of the immune and stromal cell populations in the bronchial biopsies of asthmatic patients¹⁹³ revealed structural changes including mucus cell hyperplasia with a marked increase in goblet cell numbers, which are rare in healthy airways. Subepithelial matrix protein (collagen, fibronectin, tenascin) deposition and fibrosis^{22, 23, 27, 29-31, 44, 57}, increased blood vessel density and overexpression of angiogenic factors^{16, 17}, and hyperplasia and hypertrophy of airway smooth muscle (ASM) cells are features of airway remodeling in asthma. The goblet cell transcriptional phenotype is altered in asthma, with upregulation of proinflammatory and remodeling genes¹⁹³. Mast cell numbers expressing high levels of tryptase genes and prostaglandin D synthase are increased in asthma. These are intraepithelial cells and tend to accumulate in asthmatic airway epithelium²²⁵ and increase with disease severity²²⁶. Luminal and tissue macrophages are increased in asthma and contribute to airway remodeling by releasing a plethora of inflammatory and angiogenic factors^{58, 60}. Eosinophilia and neutrophil numbers are increased in different asthma phenotypes^{57, 65, 66, 165, 189}. Pathogenic effector CD4⁺ T cells are enriched in asthmatic airways¹⁹³. Airway remodeling is also characterized by complex interactions between inflammatory and structural cells²⁰⁹ via direct physical interactions and secreted proteins and small molecules. A wealth of growth factor signaling pathways including FGF, EGFR, TGF, PDGF, and VEGFs participate in the cell-cell interactions between structural and immune cells.

Figure 2 Here the mAbs effective in severe asthma are listed and their known immunological mechanisms are summarized. The targets of approved add-on biologic treatments of severe asthma include IgE (omalizumab), IL-5 (mepolizumab and reslizumab), IL-5 receptor (benralizumab), IL-4/IL-13 receptor complex (dupilumab) and anti-TSLP (Tezepelumab).

Abbreviations:

AHR, airway hyperresponsiveness; ANGPT, angiopoietin; ASM, airway smooth muscle; BAL, bronchoalveolar lavage; β c, common receptor β subunit; COPD, chronic obstructive pulmonary disease; DC, dendritic cell; EBUS, endobronchial ultrasound; ECM, extracellular matrix; ECP, eosinophil cationic protein; EDN, eosinophil derived neurotoxin; EGF, epidermal growth factor; EMT, epithelial-mesenchymal transition; EPX, eosinophil peroxidase; Fc ϵ RI, high affinity IgE; FeNO, fractional exhaled nitric oxide; FDA, food and drug administration; FGF, fibroblast growth factor; GINA, global initiative for asthma; GM-CSF, granulocyte-macrophage colony-stimulating factor; HLM, human lung macrophage; HLMC, human lung mast cell; HRCT, high-resolution computed tomography; IL, interleukins; IL-5R α , IL-5 receptor α ; ILC, innate lymphoid cell; i.v., intravenously; lftTSLP, long form TSLP; mAb, monoclonal antibody; MBP, major basic protein; MMP, matrix metalloproteinase; NET, neutrophils extracellular trap; NHR, nuclear magnetic resonance; NK cell, natural killer cell; NKT cell, natural killer T cell; PDGF, platelet-derived growth factor; PGD₂, prostaglandin D₂; RCTs, randomized clinical trials; sTSLP, short form TSLP; TGF- β , transforming growth factor β ; TSLP, thymic stromal lymphopoietin; T2-high, type 2-high; T2-low, type 2-low; VDP, ventilation defect; VEGF, vascular endothelial growth factors.

Author Contributions

G.V., G.W.C., E.H. and J.C.W. drafted the manuscript; S.F., J.P., R.P., G.S., E.N. and G.P. edited the manuscript. All authors have read and agreed to the published version of the manuscript.

Funding

This work was supported in part by grants from the CISI-Lab Project (University of Naples Federico II), TIMING Project and Campania Bioscience (Regione Campania).

Acknowledgments

We would like to thank Dr. Gjada Criscuolo for critical reading of the manuscript.

Conflicts of Interest

- E.H. received grants and personal fees from: AstraZeneca, Sanofi, Regeneron, Novartis, GSK, Circassia, Nestlè Purina, Stallergenes-Greer outside the submitted work.
- G.V., S.F., J.P., R.P., G.S., have not potential conflicts of interest to declare.
- JCV is a full time employee of the University of Rostock as a full time professor and chair of the departments of Pneumology and intensive care medicine and has lectured for and received honoraria from: AstraZeneca, Avontec, Bayer, Bencard, Bionorica, Boehringer-Ingelheim, Chiesi, Essex/Schering-Plough, GSK, Janssen-Cilag, Leti, MEDA, Merck, MSD, Mundipharma, Novartis, Nycomed/Altana, Pfizer, Revotar, Sandoz-Hexal, Stallergens, TEVA, UCB/Schwarz-Pharma, Zydus/Cadila has participated in advisory boards for Avontec, Boehringer-Ingelheim, Chiesi, Essex/Schering-Plough, GSK, Janssen-Cilag, MEDA, MSD, Mundipharma, Novartis, Regeneron, Revotar, Roche, Sanofi-Aventis, Sandoz-Hexal, TEVA, UCB/Schwarz-Pharma

and has received research grants from the Deutsche Forschungsgesellschaft, Land Mecklenburg-Vorpommern, GSK, MSD

GWC honoraria for lectures, presentations, speakers bureaus AstraZeneca GSK-Novartis-Sanofi-Stallergenes Greer-Hal Allergy-Menarini-Chiesi-Mylan-Valeas-Faes.

References

1. Barnes PJ. Targeting cytokines to treat asthma and chronic obstructive pulmonary disease. *Nat Rev Immunol* 2018;18:454-466.
2. GINA. 2021.
3. Wenzel SE. Severe Adult Asthmas: Integrating Clinical Features, Biology, and Therapeutics to Improve Outcomes. *Am J Respir Crit Care Med* 2021;203:809-821.
4. McGregor MC, Krings JG, Nair P, Castro M. Role of Biologics in Asthma. *Am J Respir Crit Care Med* 2019;199:433-445.
5. Nair P, Surette MG, Virchow JC. Neutrophilic asthma: misconception or misnomer? *Lancet Respir Med* 2021;9:441-443.
6. Heaney LG, Perez de Llano L, Al-Ahmad M, et al. Eosinophilic and Noneosinophilic Asthma: An Expert Consensus Framework to Characterize Phenotypes in a Global Real-Life Severe Asthma Cohort. *Chest* 2021;160:814-830.
7. Suehs CM, Menzies-Gow A, Price D, et al. Expert Consensus on the Tapering of Oral Corticosteroids for the Treatment of Asthma. A Delphi Study. *Am J Respir Crit Care Med* 2021;203:871-881.
8. Settipane RA, Kreindler JL, Chung Y, Tkacz J. Evaluating direct costs and productivity losses of patients with asthma receiving GINA 4/5 therapy in the United States. *Ann Allergy Asthma Immunol* 2019;123:564-572 e563.
9. Chung KF, Wenzel SE, Brozek JL, et al. International ERS/ATS guidelines on definition, evaluation and treatment of severe asthma. *Eur Respir J* 2014;43:343-373.
10. Bartemes KR, Kita H. Dynamic role of epithelium-derived cytokines in asthma. *Clin Immunol* 2012;143:222-235.
11. Fahy JV. Type 2 inflammation in asthma—present in most, absent in many. *Nat Rev Immunol* 2015;15:57-65.
12. Borowczyk J, Shutova M, Brembilla NC, Boehncke WH. IL-25 (IL-17E) in epithelial immunology and pathophysiology. *J Allergy Clin Immunol* 2021;148:40-52.

13. Varricchi G, Pecoraro A, Marone G, Criscuolo G, Spadaro G, Genovese A. Thymic Stromal Lymphopoietin Isoforms, Inflammatory Disorders, and Cancer. *Front Immunol* 2018;9:1595.
14. Johansson K, McSorley HJ. Interleukin-33 in the developing lung-Roles in asthma and infection. *Pediatr Allergy Immunol* 2019;30:503-510.
15. Liu G, Philp AM, Corte T, et al. Therapeutic targets in lung tissue remodelling and fibrosis. *Pharmacol Ther* 2021;225:107839.
16. Hoshino M, Takahashi M, Aoike N. Expression of vascular endothelial growth factor, basic fibroblast growth factor, and angiogenin immunoreactivity in asthmatic airways and its relationship to angiogenesis. *J Allergy Clin Immunol* 2001;107:295-301.
17. Chetta A, Zanini A, Foresi A, et al. Vascular component of airway remodeling in asthma is reduced by high dose of fluticasone. *Am J Respir Crit Care Med* 2003;167:751-757.
18. Yick CY, Ferreira DS, Annoni R, et al. Extracellular matrix in airway smooth muscle is associated with dynamics of airway function in asthma. *Allergy* 2012;67:552-559.
19. Elliot JG, Jones RL, Abramson MJ, et al. Distribution of airway smooth muscle remodelling in asthma: relation to airway inflammation. *Respirology* 2015;20:66-72.
20. Pascual RM, Peters SP. Airway remodeling contributes to the progressive loss of lung function in asthma: an overview. *J Allergy Clin Immunol* 2005;116:477-486; quiz 487.
21. Bergeron C, Boulet LP. Structural changes in airway diseases: characteristics, mechanisms, consequences, and pharmacologic modulation. *Chest* 2006;129:1068-1087.
22. Hough KP, Curtiss ML, Blain TJ, et al. Airway Remodeling in Asthma. *Front Med (Lausanne)* 2020;7:191.
23. Bourdin A, Neveu D, Vachier I, Paganin F, Godard P, Chanez P. Specificity of basement membrane thickening in severe asthma. *J Allergy Clin Immunol* 2007;119:1367-1374.
24. Dolhnikoff M, da Silva LF, de Araujo BB, et al. The outer wall of small airways is a major site of remodeling in fatal asthma. *J Allergy Clin Immunol* 2009;123:1090-1097, 1097 e1091.
25. Chakir J, Shannon J, Molet S, et al. Airway remodeling-associated mediators in moderate to severe asthma: effect of steroids on TGF-beta, IL-11, IL-17, and type I and type III collagen expression. *J Allergy Clin Immunol* 2003;111:1293-1298.
26. Slats AM, Janssen K, van Schadewijk A, et al. Expression of smooth muscle and extracellular matrix proteins in relation to airway function in asthma. *J Allergy Clin Immunol* 2008;121:1196-1202.
27. Liu G, Cooley MA, Nair PM, et al. Airway remodelling and inflammation in asthma are dependent on the extracellular matrix protein fibulin-1c. *J Pathol* 2017;243:510-523.
28. Roche WR, Beasley R, Williams JH, Holgate ST. Subepithelial fibrosis in the bronchi of asthmatics. *Lancet* 1989;1:520-524.
29. Mostaco-Guidolin LB, Osei ET, Ullah J, et al. Defective Fibrillar Collagen Organization by Fibroblasts Contributes to Airway Remodeling in Asthma. *Am J Respir Crit Care Med* 2019;200:431-443.
30. Ito JT, Lourenco JD, Righetti RF, Tiberio I, Prado CM, Lopes F. Extracellular Matrix Component Remodeling in Respiratory Diseases: What Has Been Found in Clinical and Experimental Studies? *Cells* 2019;8.
31. Howarth PH, Knox AJ, Amrani Y, Tliba O, Panettieri RA, Jr., Johnson M. Synthetic responses in airway smooth muscle. *J Allergy Clin Immunol* 2004;114:S32-50.

32. Prakash YS. Emerging concepts in smooth muscle contributions to airway structure and function: implications for health and disease. *Am J Physiol Lung Cell Mol Physiol* 2016;311:L1113-L1140.
33. Yap HM, Israf DA, Harith HH, Tham CL, Sulaiman MR. Crosstalk Between Signaling Pathways Involved in the Regulation of Airway Smooth Muscle Cell Hyperplasia. *Front Pharmacol* 2019;10:1148.
34. Cheng W, Yan K, Xie LY, et al. MiR-143-3p controls TGF-beta1-induced cell proliferation and extracellular matrix production in airway smooth muscle via negative regulation of the nuclear factor of activated T cells 1. *Mol Immunol* 2016;78:133-139.
35. Harkness LM, Weckmann M, Kopp M, Becker T, Ashton AW, Burgess JK. Tumstatin regulates the angiogenic and inflammatory potential of airway smooth muscle extracellular matrix. *J Cell Mol Med* 2017;21:3288-3297.
36. Holgate ST. Pathogenesis of asthma. *Clin Exp Allergy* 2008;38:872-897.
37. Doucet C, Brouty-Boye D, Pottin-Clemenceau C, Jasmin C, Canonica GW, Azzarone B. IL-4 and IL-13 specifically increase adhesion molecule and inflammatory cytokine expression in human lung fibroblasts. *Int Immunol* 1998;10:1421-1433.
38. Cazes E, Giron-Michel J, Baouz S, et al. Novel anti-inflammatory effects of the inhaled corticosteroid fluticasone propionate during lung myofibroblastic differentiation. *J Immunol* 2001;167:5329-5337.
39. Winkler T, Frey U. Airway remodeling: Shifting the trigger point for exacerbations in asthma. *J Allergy Clin Immunol* 2021;148:710-712.
40. Loffredo S, Borriello F, Iannone R, et al. Group V Secreted Phospholipase A2 Induces the Release of Proangiogenic and Antiangiogenic Factors by Human Neutrophils. *Front Immunol* 2017;8:443.
41. Cristinziano L, Poto R, Criscuolo G, et al. IL-33 and Superantigenic Activation of Human Lung Mast Cells Induce the Release of Angiogenic and Lymphangiogenic Factors. *Cells* 2021;10.
42. Sammarco G, Varricchi G, Ferraro V, et al. Mast Cells, Angiogenesis and Lymphangiogenesis in Human Gastric Cancer. *Int J Mol Sci* 2019;20.
43. Varricchi G, Loffredo S, Bencivenga L, et al. Angiopoietins, Vascular Endothelial Growth Factors and Secretory Phospholipase A2 in Ischemic and Non-Ischemic Heart Failure. *J Clin Med* 2020;9.
44. Hauber HP, Foley SC, Hamid Q. Mucin overproduction in chronic inflammatory lung disease. *Can Respir J* 2006;13:327-335.
45. Halwani R, Al-Muhsen S, Al-Jahdali H, Hamid Q. Role of transforming growth factor-beta in airway remodeling in asthma. *Am J Respir Cell Mol Biol* 2011;44:127-133.
46. Kardas G, Daszynska-Kardas A, Marynowski M, Brzakalska O, Kuna P, Panek M. Role of Platelet-Derived Growth Factor (PDGF) in Asthma as an Immunoregulatory Factor Mediating Airway Remodeling and Possible Pharmacological Target. *Front Pharmacol* 2020;11:47.
47. Batra V, Musani AI, Hastie AT, et al. Bronchoalveolar lavage fluid concentrations of transforming growth factor (TGF)-beta1, TGF-beta2, interleukin (IL)-4 and IL-13 after segmental allergen challenge and their effects on alpha-smooth muscle actin and collagen III synthesis by primary human lung fibroblasts. *Clin Exp Allergy* 2004;34:437-444.
48. Hackett TL. Epithelial-mesenchymal transition in the pathophysiology of airway remodelling in asthma. *Curr Opin Allergy Clin Immunol* 2012;12:53-59.
49. Wen FQ, Liu XD, Terasaki Y, et al. Interferon-gamma reduces interleukin-4- and interleukin-13-augmented transforming growth factor-beta2 production in human bronchial epithelial cells by targeting Smads. *Chest* 2003;123:372S-373S.

50. Dolgachev V, Berlin AA, Lukacs NW. Eosinophil activation of fibroblasts from chronic allergen-induced disease utilizes stem cell factor for phenotypic changes. *Am J Pathol* 2008;172:68-76.
51. Tanaka H, Komai M, Nagao K, et al. Role of interleukin-5 and eosinophils in allergen-induced airway remodeling in mice. *Am J Respir Cell Mol Biol* 2004;31:62-68.
52. Booth BW, Sandifer T, Martin EL, Martin LD. IL-13-induced proliferation of airway epithelial cells: mediation by intracellular growth factor mobilization and ADAM17. *Respir Res* 2007;8:51.
53. Malavia NK, Mih JD, Raub CB, Dinh BT, George SC. IL-13 induces a bronchial epithelial phenotype that is profibrotic. *Respir Res* 2008;9:27.
54. Marone G, Granata F, Pucino V, et al. The Intriguing Role of Interleukin 13 in the Pathophysiology of Asthma. *Front Pharmacol* 2019;10:1387.
55. Varricchi G, Bagnasco D, Borriello F, Heffler E, Canonica GW. Interleukin-5 pathway inhibition in the treatment of eosinophilic respiratory disorders: evidence and unmet needs. *Curr Opin Allergy Clin Immunol* 2016;16:186-200.
56. Patella V, de Crescenzo G, Marino I, et al. Eosinophil granule proteins activate human heart mast cells. *J Immunol* 1996;157:1219-1225.
57. Flood-Page P, Menzies-Gow A, Phipps S, et al. Anti-IL-5 treatment reduces deposition of ECM proteins in the bronchial subepithelial basement membrane of mild atopic asthmatics. *J Clin Invest* 2003;112:1029-1036.
58. Braile M, Cristinziano L, Marcella S, et al. LPS-mediated neutrophil VEGF-A release is modulated by cannabinoid receptor activation. *J Leukoc Biol* 2021;109:621-631.
59. Balhara J, Gounni AS. The alveolar macrophages in asthma: a double-edged sword. *Mucosal Immunol* 2012;5:605-609.
60. Braile M, Fiorelli A, Sorriento D, et al. Human Lung-Resident Macrophages Express and Are Targets of Thymic Stromal Lymphopoietin in the Tumor Microenvironment. *Cells* 2021;10.
61. Staiano RI, Loffredo S, Borriello F, et al. Human lung-resident macrophages express CB1 and CB2 receptors whose activation inhibits the release of angiogenic and lymphangiogenic factors. *J Leukoc Biol* 2016;99:531-540.
62. Varricchi G, Rossi FW, Galdiero MR, et al. Physiological Roles of Mast Cells: Collegium Internationale Allergologicum Update 2019. *Int Arch Allergy Immunol* 2019;179:247-261.
63. Marcella S, Petraroli A, Braile M, et al. Vascular endothelial growth factors and angiopoietins as new players in mastocytosis. *Clin Exp Med* 2021;21:415-427.
64. Compton SJ, Cairns JA, Holgate ST, Walls AF. The role of mast cell tryptase in regulating endothelial cell proliferation, cytokine release, and adhesion molecule expression: tryptase induces expression of mRNA for IL-1 beta and IL-8 and stimulates the selective release of IL-8 from human umbilical vein endothelial cells. *J Immunol* 1998;161:1939-1946.
65. Ardi VC, Kupriyanova TA, Deryugina EI, Quigley JP. Human neutrophils uniquely release TIMP-free MMP-9 to provide a potent catalytic stimulator of angiogenesis. *Proc Natl Acad Sci U S A* 2007;104:20262-20267.
66. Ventura I, Vega A, Chacon P, et al. Neutrophils from allergic asthmatic patients produce and release metalloproteinase-9 upon direct exposure to allergens. *Allergy* 2014;69:898-905.
67. Varricchi G, Modestino L, Poto R, et al. Neutrophil extracellular traps and neutrophil-derived mediators as possible biomarkers in bronchial asthma. *Clin Exp Med* 2021.

68. Marone G, Spadaro G, Braile M, et al. Tezepelumab: a novel biological therapy for the treatment of severe uncontrolled asthma. *Expert Opin Investig Drugs* 2019;28:931-940.
69. Molofsky AB, Savage AK, Locksley RM. Interleukin-33 in Tissue Homeostasis, Injury, and Inflammation. *Immunity* 2015;42:1005-1019.
70. Grainge C, Dennison P, Lau L, Davies D, Howarth P. Asthmatic and normal respiratory epithelial cells respond differently to mechanical apical stress. *Am J Respir Crit Care Med* 2014;190:477-480.
71. Allakhverdi Z, Comeau MR, Jessup HK, et al. Thymic stromal lymphopoietin is released by human epithelial cells in response to microbes, trauma, or inflammation and potently activates mast cells. *J Exp Med* 2007;204:253-258.
72. Wang W, Li Y, Lv Z, et al. Bronchial Allergen Challenge of Patients with Atopic Asthma Triggers an Alarmin (IL-33, TSLP, and IL-25) Response in the Airways Epithelium and Submucosa. *J Immunol* 2018;201:2221-2231.
73. Li Y, Wang W, Lv Z, et al. Elevated Expression of IL-33 and TSLP in the Airways of Human Asthmatics In Vivo: A Potential Biomarker of Severe Refractory Disease. *J Immunol* 2018;200:2253-2262.
74. Shikotra A, Choy DF, Ohri CM, et al. Increased expression of immunoreactive thymic stromal lymphopoietin in patients with severe asthma. *J Allergy Clin Immunol* 2012;129:104-111 e101-109.
75. Smelter DF, Sathish V, Thompson MA, Pabelick CM, Vassallo R, Prakash YS. Thymic stromal lymphopoietin in cigarette smoke-exposed human airway smooth muscle. *J Immunol* 2010;185:3035-3040.
76. Nakamura Y, Miyata M, Ohba T, et al. Cigarette smoke extract induces thymic stromal lymphopoietin expression, leading to T(H)2-type immune responses and airway inflammation. *J Allergy Clin Immunol* 2008;122:1208-1214.
77. Kouzaki H, O'Grady SM, Lawrence CB, Kita H. Proteases induce production of thymic stromal lymphopoietin by airway epithelial cells through protease-activated receptor-2. *J Immunol* 2009;183:1427-1434.
78. Lee HC, Headley MB, Loo YM, et al. Thymic stromal lymphopoietin is induced by respiratory syncytial virus-infected airway epithelial cells and promotes a type 2 response to infection. *J Allergy Clin Immunol* 2012;130:1187-1196 e1185.
79. Kato A, Favoreto S, Jr., Avila PC, Schleimer RP. TLR3- and Th2 cytokine-dependent production of thymic stromal lymphopoietin in human airway epithelial cells. *J Immunol* 2007;179:1080-1087.
80. Lai JF, Thompson LJ, Ziegler SF. TSLP drives acute TH2-cell differentiation in lungs. *J Allergy Clin Immunol* 2020;146:1406-1418 e1407.
81. Kaur D, Doe C, Woodman L, et al. Mast cell-airway smooth muscle crosstalk: the role of thymic stromal lymphopoietin. *Chest* 2012;142:76-85.
82. Kang JH, Yang HW, Park JH, et al. Lipopolysaccharide regulates thymic stromal lymphopoietin expression via TLR4/MAPK/Akt/NF-kappaB-signaling pathways in nasal fibroblasts: differential inhibitory effects of macrolide and corticosteroid. *Int Forum Allergy Rhinol* 2021;11:144-152.
83. Datta A, Alexander R, Sulikowski MG, et al. Evidence for a functional thymic stromal lymphopoietin signaling axis in fibrotic lung disease. *J Immunol* 2013;191:4867-4879.
84. Tsilingiri K, Fornasa G, Rescigno M. Thymic Stromal Lymphopoietin: To Cut a Long Story Short. *Cell Mol Gastroenterol Hepatol* 2017;3:174-182.
85. Dong H, Hu Y, Liu L, et al. Distinct roles of short and long thymic stromal lymphopoietin isoforms in house dust mite-induced asthmatic airway epithelial barrier disruption. *Sci Rep* 2016;6:39559.

86. Wu J, Dong F, Wang RA, et al. Central role of cellular senescence in TSLP-induced airway remodeling in asthma. *PLoS One* 2013;8:e77795.
87. Cai LM, Zhou YQ, Yang LF, et al. Thymic stromal lymphopoietin induced early stage of epithelial-mesenchymal transition in human bronchial epithelial cells through upregulation of transforming growth factor beta 1. *Exp Lung Res* 2019;45:221-235.
88. Brunetto E, De Monte L, Balzano G, et al. The IL-1/IL-1 receptor axis and tumor cell released inflammasome adaptor ASC are key regulators of TSLP secretion by cancer associated fibroblasts in pancreatic cancer. *J Immunother Cancer* 2019;7:45.
89. Cao L, Liu F, Liu Y, et al. TSLP promotes asthmatic airway remodeling via p38-STAT3 signaling pathway in human lung fibroblast. *Exp Lung Res* 2018;44:288-301.
90. Jin A, Tang X, Zhai W, et al. TSLP-induced collagen type-I synthesis through STAT3 and PRMT1 is sensitive to calcitriol in human lung fibroblasts. *Biochim Biophys Acta Mol Cell Res* 2021;1868:119083.
91. Redhu NS, Shan L, Movassagh H, Gounni AS. Thymic stromal lymphopoietin induces migration in human airway smooth muscle cells. *Sci Rep* 2013;3:2301.
92. FitzGerald JM, Bleecker ER, Nair P, et al. Benralizumab, an anti-interleukin-5 receptor alpha monoclonal antibody, as add-on treatment for patients with severe, uncontrolled, eosinophilic asthma (CALIMA): a randomised, double-blind, placebo-controlled phase 3 trial. *Lancet* 2016;388:2128-2141.
93. Niimi A, Matsumoto H, Takemura M, Ueda T, Nakano Y, Mishima M. Clinical assessment of airway remodeling in asthma: utility of computed tomography. *Clin Rev Allergy Immunol* 2004;27:45-58.
94. Awadh N, Muller NL, Park CS, Abboud RT, FitzGerald JM. Airway wall thickness in patients with near fatal asthma and control groups: assessment with high resolution computed tomographic scanning. *Thorax* 1998;53:248-253.
95. Nagarkar DR, Poposki JA, Comeau MR, et al. Airway epithelial cells activate TH2 cytokine production in mast cells through IL-1 and thymic stromal lymphopoietin. *J Allergy Clin Immunol* 2012;130:225-232 e224.
96. Afferni C, Buccione C, Andreone S, et al. The Pleiotropic Immunomodulatory Functions of IL-33 and Its Implications in Tumor Immunity. *Front Immunol* 2018;9:2601.
97. Altman MC, Lai Y, Nolin JD, et al. Airway epithelium-shifted mast cell infiltration regulates asthmatic inflammation via IL-33 signaling. *J Clin Invest* 2019;129:4979-4991.
98. Guo Z, Wu J, Zhao J, et al. IL-33 promotes airway remodeling and is a marker of asthma disease severity. *J Asthma* 2014;51:863-869.
99. Saglani S, Lui S, Ullmann N, et al. IL-33 promotes airway remodeling in pediatric patients with severe steroid-resistant asthma. *J Allergy Clin Immunol* 2013;132:676-685 e613.
100. Yi L, Cheng D, Zhang K, et al. Intelectin contributes to allergen-induced IL-25, IL-33, and TSLP expression and type 2 response in asthma and atopic dermatitis. *Mucosal Immunol* 2017;10:1491-1503.
101. Beale J, Jayaraman A, Jackson DJ, et al. Rhinovirus-induced IL-25 in asthma exacerbation drives type 2 immunity and allergic pulmonary inflammation. *Sci Transl Med* 2014;6:256ra134.
102. Xu X, Luo S, Li B, Dai H, Zhang J. IL-25 contributes to lung fibrosis by directly acting on alveolar epithelial cells and fibroblasts. *Exp Biol Med (Maywood)* 2019;244:770-780.
103. Letuve S, Lajoie-Kadoch S, Audusseau S, et al. IL-17E upregulates the expression of proinflammatory cytokines in lung fibroblasts. *J Allergy Clin Immunol* 2006;117:590-596.

104. Hams E, Armstrong ME, Barlow JL, et al. IL-25 and type 2 innate lymphoid cells induce pulmonary fibrosis. *Proc Natl Acad Sci U S A* 2014;111:367-372.
105. Yao XJ, Huang KW, Li Y, et al. Direct comparison of the dynamics of IL-25- and 'allergen'-induced airways inflammation, remodelling and hypersensitivity in a murine asthma model. *Clin Exp Allergy* 2014;44:765-777.
106. Samitas K, Delimpoura V, Zervas E, Gaga M. Anti-IgE treatment, airway inflammation and remodelling in severe allergic asthma: current knowledge and future perspectives. *Eur Respir Rev* 2015;24:594-601.
107. Pandey V, Mihara S, Fensome-Green A, Bolsover S, Cockcroft S. Monomeric IgE stimulates NFAT translocation into the nucleus, a rise in cytosol Ca²⁺, degranulation, and membrane ruffling in the cultured rat basophilic leukemia-2H3 mast cell line. *J Immunol* 2004;172:4048-4058.
108. Matsuda K, Piliponsky AM, Iikura M, et al. Monomeric IgE enhances human mast cell chemokine production: IL-4 augments and dexamethasone suppresses the response. *J Allergy Clin Immunol* 2005;116:1357-1363.
109. Roth M, Zhao F, Zhong J, Lardinois D, Tamm M. Serum IgE Induced Airway Smooth Muscle Cell Remodeling Is Independent of Allergens and Is Prevented by Omalizumab. *PLoS One* 2015;10:e0136549.
110. Zheng J, Wu Q, Zou Y, Wang M, He L, Guo S. Respiratory Microbiota Profiles Associated With the Progression From Airway Inflammation to Remodeling in Mice With OVA-Induced Asthma. *Front Microbiol* 2021;12:723152.
111. Boulet LP. Airway remodeling in asthma: update on mechanisms and therapeutic approaches. *Curr Opin Pulm Med* 2018;24:56-62.
112. James AL, Wenzel S. Clinical relevance of airway remodelling in airway diseases. *Eur Respir J* 2007;30:134-155.
113. Riccioni G, Di Ilio C, D'Orazio N. Review: Pharmacological treatment of airway remodeling: inhaled corticosteroids or antileukotrienes? *Ann Clin Lab Sci* 2004;34:138-142.
114. Ward C, Reid DW, Orsida BE, et al. Inter-relationships between airway inflammation, reticular basement membrane thickening and bronchial hyper-reactivity to methacholine in asthma; a systematic bronchoalveolar lavage and airway biopsy analysis. *Clin Exp Allergy* 2005;35:1565-1571.
115. Agache I, Beltran J, Akdis C, et al. Efficacy and safety of treatment with biologicals (benralizumab, dupilumab, mepolizumab, omalizumab and reslizumab) for severe eosinophilic asthma. A systematic review for the EAACI Guidelines - recommendations on the use of biologicals in severe asthma. *Allergy* 2020;75:1023-1042.
116. Varricchi G, Marone G, Spadaro G, Russo M, Granata F, Genovese A. Novel Biological Therapies in Severe Asthma: Targeting the Right Trait. *Curr Med Chem* 2019;26:2801-2822.
117. Ferrando M, Bagnasco D, Varricchi G, et al. Personalized Medicine in Allergy. *Allergy Asthma Immunol Res* 2017;9:15-24.
118. Canonica GW, Ferrando M, Baiardini I, et al. Asthma: personalized and precision medicine. *Curr Opin Allergy Clin Immunol* 2018;18:51-58.
119. Brusselle GG, Koppelman GH. Biologic Therapies for Severe Asthma. *N Engl J Med* 2022;386:157-171.
120. Roche N, Anzueto A, Bosnic Anticevich S, et al. The importance of real-life research in respiratory medicine: manifesto of the Respiratory Effectiveness Group: Endorsed by the International Primary Care Respiratory Group and the World Allergy Organization. *Eur Respir J* 2019;54.
121. Little RJ, Lewis RJ. Estimands, Estimators, and Estimates. *JAMA* 2021;326:967-968.

122. Schulman ES. Development of a monoclonal anti-immunoglobulin E antibody (omalizumab) for the treatment of allergic respiratory disorders. *Am J Respir Crit Care Med* 2001;164:S6-11.
123. Kawakami T, Blank U. From IgE to Omalizumab. *J Immunol* 2016;197:4187-4192.
124. MacGlashan DW, Jr., Savage JH, Wood RA, Saini SS. Suppression of the basophil response to allergen during treatment with omalizumab is dependent on 2 competing factors. *J Allergy Clin Immunol* 2012;130:1130-1135 e1135.
125. Alhossan A, Lee CS, MacDonald K, Abraham I. "Real-life" Effectiveness Studies of Omalizumab in Adult Patients with Severe Allergic Asthma: Meta-analysis. *J Allergy Clin Immunol Pract* 2017;5:1362-1370 e1362.
126. Esquivel A, Busse WW, Calatroni A, et al. Effects of Omalizumab on Rhinovirus Infections, Illnesses, and Exacerbations of Asthma. *Am J Respir Crit Care Med* 2017;196:985-992.
127. Pelaia C, Calabrese C, Terracciano R, de Blasio F, Vatrella A, Pelaia G. Omalizumab, the first available antibody for biological treatment of severe asthma: more than a decade of real-life effectiveness. *Ther Adv Respir Dis* 2018;12:1753466618810192.
128. Adachi M, Kozawa M, Yoshisue H, et al. Real-world safety and efficacy of omalizumab in patients with severe allergic asthma: A long-term post-marketing study in Japan. *Respir Med* 2018;141:56-63.
129. Corren J, Kavati A, Ortiz B, et al. Efficacy and safety of omalizumab in children and adolescents with moderate-to-severe asthma: A systematic literature review. *Allergy Asthma Proc* 2017;38:250-263.
130. Namazy J, Cabana MD, Scheuerle AE, et al. The Xolair Pregnancy Registry (EXPECT): the safety of omalizumab use during pregnancy. *J Allergy Clin Immunol* 2015;135:407-412.
131. Hanania NA, Alpan O, Hamilos DL, et al. Omalizumab in severe allergic asthma inadequately controlled with standard therapy: a randomized trial. *Ann Intern Med* 2011;154:573-582.
132. Normansell R, Walker S, Milan SJ, Walters EH, Nair P. Omalizumab for asthma in adults and children. *Cochrane Database Syst Rev* 2014;CD003559.
133. Hew M, Gillman A, Sutherland M, et al. Real-life effectiveness of omalizumab in severe allergic asthma above the recommended dosing range criteria. *Clin Exp Allergy* 2016;46:1407-1415.
134. Casale TB, Luskin AT, Busse W, et al. Omalizumab Effectiveness by Biomarker Status in Patients with Asthma: Evidence From PROSPERO, A Prospective Real-World Study. *J Allergy Clin Immunol Pract* 2019;7:156-164 e151.
135. Riccio AM, Dal Negro RW, Micheletto C, et al. Omalizumab modulates bronchial reticular basement membrane thickness and eosinophil infiltration in severe persistent allergic asthma patients. *Int J Immunopathol Pharmacol* 2012;25:475-484.
136. Hoshino M, Ohtawa J. Effects of adding omalizumab, an anti-immunoglobulin E antibody, on airway wall thickening in asthma. *Respiration* 2012;83:520-528.
137. Zastrzezynska W, Przybyszowski M, Bazan-Socha S, et al. Omalizumab may decrease the thickness of the reticular basement membrane and fibronectin deposit in the bronchial mucosa of severe allergic asthmatics. *J Asthma* 2020;57:468-477.
138. FDA.GOV. 2019.
139. Varricchi G, Bagnasco D, Ferrando M, Puggioni F, Passalacqua G, Canonica GW. Mepolizumab in the management of severe eosinophilic asthma in adults: current evidence and practical experience. *Ther Adv Respir Dis* 2017;11:40-45.

140. Varricchi G, Galdiero MR, Loffredo S, et al. Eosinophils: The unsung heroes in cancer? *Oncoimmunology* 2018;7:e1393134.
141. Broughton SE, Nero TL, Dhagat U, et al. The betac receptor family - Structural insights and their functional implications. *Cytokine* 2015;74:247-258.
142. Varricchi G, Poto R, Marone G, Schroeder JT. IL-3 in the development and function of basophils. *Semin Immunol* 2021;54:101510.
143. Pavord ID, Korn S, Howarth P, et al. Mepolizumab for severe eosinophilic asthma (DREAM): a multicentre, double-blind, placebo-controlled trial. *Lancet* 2012;380:651-659.
144. Lugogo N, Domingo C, Chanez P, et al. Long-term Efficacy and Safety of Mepolizumab in Patients With Severe Eosinophilic Asthma: A Multi-center, Open-label, Phase IIIb Study. *Clin Ther* 2016;38:2058-2070 e2051.
145. Khurana S, Brusselle GG, Bel EH, et al. Long-term Safety and Clinical Benefit of Mepolizumab in Patients With the Most Severe Eosinophilic Asthma: The COSMEX Study. *Clin Ther* 2019;41:2041-2056 e2045.
146. Ortega H, Liu MC, Pavord ID. Mepolizumab treatment in patients with severe eosinophilic asthma. *N Engl J Med* 2015;372:1777.
147. Chupp GL, Bradford ES, Albers FC, et al. Efficacy of mepolizumab add-on therapy on health-related quality of life and markers of asthma control in severe eosinophilic asthma (MUSCA): a randomised, double-blind, placebo-controlled, parallel-group, multicentre, phase 3b trial. *Lancet Respir Med* 2017;5:390-400.
148. Bel EH, Wenzel SE, Thompson PJ, et al. Oral glucocorticoid-sparing effect of mepolizumab in eosinophilic asthma. *N Engl J Med* 2014;371:1189-1197.
149. Sposato B, Camiciottoli G, Bacci E, et al. Mepolizumab effectiveness on small airway obstruction, corticosteroid sparing and maintenance therapy step-down in real life. *Pulm Pharmacol Ther* 2020;61:101899.
150. Pelaia C, Crimi C, Pelaia G, et al. Real-life evaluation of mepolizumab efficacy in patients with severe eosinophilic asthma, according to atopic trait and allergic phenotype. *Clin Exp Allergy* 2020;50:780-788.
151. Bagnasco D, Caminati M, Menzella F, et al. One year of mepolizumab. Efficacy and safety in real-life in Italy. *Pulm Pharmacol Ther* 2019;58:101836.
152. Zhang J, Kuvelkar R, Murgolo NJ, et al. Mapping and characterization of the epitope(s) of Sch 55700, a humanized mAb, that inhibits human IL-5. *Int Immunol* 1999;11:1935-1944.
153. Varricchi G, Senna G, Loffredo S, Bagnasco D, Ferrando M, Canonica GW. Reslizumab and Eosinophilic Asthma: One Step Closer to Precision Medicine? *Front Immunol* 2017;8:242.
154. Bjermer L, Lemiere C, Maspero J, Weiss S, Zangrilli J, Germinaro M. Reslizumab for Inadequately Controlled Asthma With Elevated Blood Eosinophil Levels: A Randomized Phase 3 Study. *Chest* 2016;150:789-798.
155. Castro M, Mathur S, Hargreave F, et al. Reslizumab for poorly controlled, eosinophilic asthma: a randomized, placebo-controlled study. *Am J Respir Crit Care Med* 2011;184:1125-1132.
156. Corren J, Weinstein S, Janka L, Zangrilli J, Garin M. Phase 3 Study of Reslizumab in Patients With Poorly Controlled Asthma: Effects Across a Broad Range of Eosinophil Counts. *Chest* 2016;150:799-810.
157. Castro M, Zangrilli J, Wechsler ME, et al. Reslizumab for inadequately controlled asthma with elevated blood eosinophil counts: results from two multicentre, parallel, double-blind, randomised, placebo-controlled, phase 3 trials. *Lancet Respir Med* 2015;3:355-366.

158. Bernstein JA, Virchow JC, Murphy K, et al. Effect of fixed-dose subcutaneous reslizumab on asthma exacerbations in patients with severe uncontrolled asthma and corticosteroid sparing in patients with oral corticosteroid-dependent asthma: results from two phase 3, randomised, double-blind, placebo-controlled trials. *Lancet Respir Med* 2020;8:461-474.
159. Wechsler ME, Peters SP, Hill TD, et al. Clinical Outcomes and Health-Care Resource Use Associated With Reslizumab Treatment in Adults With Severe Eosinophilic Asthma in Real-World Practice. *Chest* 2021;159:1734-1746.
160. Ghazi A, Trikha A, Calhoun WJ. Benralizumab—a humanized mAb to IL-5Ralpha with enhanced antibody-dependent cell-mediated cytotoxicity—a novel approach for the treatment of asthma. *Expert Opin Biol Ther* 2012;12:113-118.
161. Bleecker ER, FitzGerald JM, Chanez P, et al. Efficacy and safety of benralizumab for patients with severe asthma uncontrolled with high-dosage inhaled corticosteroids and long-acting beta2-agonists (SIROCCO): a randomised, multicentre, placebo-controlled phase 3 trial. *Lancet* 2016;388:2115-2127.
162. Ferguson GT, FitzGerald JM, Bleecker ER, et al. Benralizumab for patients with mild to moderate, persistent asthma (BISE): a randomised, double-blind, placebo-controlled, phase 3 trial. *Lancet Respir Med* 2017;5:568-576.
163. Harrison TW, Chanez P, Menzella F, et al. Onset of effect and impact on health-related quality of life, exacerbation rate, lung function, and nasal polyposis symptoms for patients with severe eosinophilic asthma treated with benralizumab (ANDHI): a randomised, controlled, phase 3b trial. *Lancet Respir Med* 2021;9:260-274.
164. Chipps BE, Hirsch I, Trudo F, Alacqua M, Zangrilli JG. Benralizumab efficacy for patients with fixed airflow obstruction and severe, uncontrolled eosinophilic asthma. *Ann Allergy Asthma Immunol* 2020;124:79-86.
165. Chachi L, Diver S, Kaul H, et al. Computational modelling prediction and clinical validation of impact of benralizumab on airway smooth muscle mass in asthma. *Eur Respir J* 2019;54.
166. Pelaia C, Busceti MT, Vatrella A, et al. Real-life rapidity of benralizumab effects in patients with severe allergic eosinophilic asthma: Assessment of blood eosinophils, symptom control, lung function and oral corticosteroid intake after the first drug dose. *Pulm Pharmacol Ther* 2019;58:101830.
167. Padilla-Galo A, Levy-Abitbol R, Oliveira C, et al. Real-life experience with benralizumab during 6 months. *BMC Pulm Med* 2020;20:184.
168. Menzella F, Ruggiero P, Galeone C, Scelfo C, Bagnasco D, Facciolo N. Significant improvement in lung function and asthma control after benralizumab treatment for severe refractory eosinophilic asthma. *Pulm Pharmacol Ther* 2020;64:101966.
169. Keegan AD, Zamorano J, Keselman A, Heller NM. IL-4 and IL-13 Receptor Signaling From 4PS to Insulin Receptor Substrate 2: There and Back Again, a Historical View. *Front Immunol* 2018;9:1037.
170. Harb H, Chatila TA. Mechanisms of Dupilumab. *Clin Exp Allergy* 2020;50:5-14.
171. Wenzel S, Ford L, Pearlman D, et al. Dupilumab in persistent asthma with elevated eosinophil levels. *N Engl J Med* 2013;368:2455-2466.
172. Wenzel S, Castro M, Corren J, et al. Dupilumab efficacy and safety in adults with uncontrolled persistent asthma despite use of medium-to-high-dose inhaled corticosteroids plus a long-acting beta2 agonist: a randomised double-blind placebo-controlled pivotal phase 2b dose-ranging trial. *Lancet* 2016;388:31-44.
173. Castro M, Corren J, Pavord ID, et al. Dupilumab Efficacy and Safety in Moderate-to-Severe Uncontrolled Asthma. *N Engl J Med* 2018;378:2486-2496.

174. Le Floch A, Allinne J, Nagashima K, et al. Dual blockade of IL-4 and IL-13 with dupilumab, an IL-4/IL-13 antibody, is required to broadly inhibit type 2 inflammation. *Allergy* 2020;75:1188-1204.
175. Renner A, Marth K, Patocka K, Idzko M, Pohl W. Dupilumab rapidly improves asthma control in predominantly anti-IL5/IL5R pretreated Austrian real-life severe asthmatics. *Immun Inflamm Dis* 2021;9:624-627.
176. Eger K, Pet L, Weersink EJM, Bel EH. Complications of switching from anti-IL-5 or anti-IL-5R to dupilumab in corticosteroid-dependent severe asthma. *J Allergy Clin Immunol Pract* 2021;9:2913-2915.
177. Marcant P, Balaye P, Merhi R, et al. Dupilumab-associated hypereosinophilia in patients treated for moderate-to-severe atopic dermatitis. *J Eur Acad Dermatol Venereol* 2021;35:e394-e396.
178. Bachert C, Han JK, Desrosiers M, et al. Efficacy and safety of dupilumab in patients with severe chronic rhinosinusitis with nasal polyps (LIBERTY NP SINUS-24 and LIBERTY NP SINUS-52): results from two multicentre, randomised, double-blind, placebo-controlled, parallel-group phase 3 trials. *Lancet* 2019;394:1638-1650.
179. Pedersen E, Sondergaard B, Poulsen EF. [Don't want to lose nursing hours on account of new education]. *Sygeplejersken* 1988;88:17.
180. Han JK, Bachert C, Fokkens W, et al. Mepolizumab for chronic rhinosinusitis with nasal polyps (SYNAPSE): a randomised, double-blind, placebo-controlled, phase 3 trial. *Lancet Respir Med* 2021;9:1141-1153.
181. Canonica GW, Harrison TW, Chanez P, et al. Benralizumab improves symptoms of patients with severe, eosinophilic asthma with a diagnosis of nasal polyposis. *Allergy* 2022;77:150-161.
182. Ko HK, Cheng SL, Lin CH, et al. Blood tryptase and thymic stromal lymphopoietin levels predict the risk of exacerbation in severe asthma. *Sci Rep* 2021;11:8425.
183. Corren J, Parnes JR, Wang L, et al. Tezepelumab in Adults with Uncontrolled Asthma. *N Engl J Med* 2017;377:936-946.
184. Menzies-Gow A, Corren J, Bourdin A, et al. Tezepelumab in Adults and Adolescents with Severe, Uncontrolled Asthma. *N Engl J Med* 2021;384:1800-1809.
185. An G, Wang W, Zhang X, et al. Combined blockade of IL-25, IL-33 and TSLP mediates amplified inhibition of airway inflammation and remodelling in a murine model of asthma. *Respirology* 2020;25:603-612.
186. Chen ZG, Zhang TT, Li HT, et al. Neutralization of TSLP inhibits airway remodeling in a murine model of allergic asthma induced by chronic exposure to house dust mite. *PLoS One* 2013;8:e51268.
187. Lin SC, Chou HC, Chen CM, Chiang BL. Anti-thymic stromal lymphopoietin antibody suppresses airway remodeling in asthma through reduction of MMP and CTGF. *Pediatr Res* 2019;86:181-187.
188. Cheng Z, Wang X, Dai LL, et al. Thymic Stromal Lymphopoietin Signaling Pathway Inhibition Attenuates Airway Inflammation and Remodeling in Rats with Asthma. *Cell Physiol Biochem* 2018;47:1482-1496.
189. Diver S, Khalfaoui L, Emson C, et al. Effect of tezepelumab on airway inflammatory cells, remodelling, and hyperresponsiveness in patients with moderate-to-severe uncontrolled asthma (CASCADE): a double-blind, randomised, placebo-controlled, phase 2 trial. *Lancet Respir Med* 2021;9:1299-1312.
190. Sverrild A, Hansen S, Hvidtfeldt M, et al. The effect of tezepelumab on airway hyperresponsiveness to mannitol in asthma (UPSTREAM). *Eur Respir J* 2021.
191. Kelsen SG, Agache IO, Soong W, et al. Astegolimab (anti-ST2) efficacy and safety in adults with severe asthma: A randomized clinical trial. *J Allergy Clin Immunol* 2021;148:790-798.

192. Wechsler ME, Ruddy MK, Pavord ID, et al. Efficacy and Safety of Itepekimab in Patients with Moderate-to-Severe Asthma. *N Engl J Med* 2021;385:1656-1668.
193. Vieira Braga FA, Kar G, Berg M, et al. A cellular census of human lungs identifies novel cell states in health and in asthma. *Nat Med* 2019;25:1153-1163.
194. Hoshino M, Ohtawa J, Akitsu K. Effect of treatment with inhaled corticosteroid on serum periostin levels in asthma. *Respirology* 2016;21:297-303.
195. Gorska K, Korczynski P, Mierzejewski M, et al. Comparison of endobronchial ultrasound and high resolution computed tomography as tools for airway wall imaging in asthma and chronic obstructive pulmonary disease. *Respir Med* 2016;117:131-138.
196. Hartley RA, Barker BL, Newby C, et al. Relationship between lung function and quantitative computed tomographic parameters of airway remodeling, air trapping, and emphysema in patients with asthma and chronic obstructive pulmonary disease: A single-center study. *J Allergy Clin Immunol* 2016;137:1413-1422 e1412.
197. Ash SY, Rahaghi FN, Come CE, et al. Pruning of the Pulmonary Vasculature in Asthma. The Severe Asthma Research Program (SARP) Cohort. *Am J Respir Crit Care Med* 2018;198:39-50.
198. Eddy RL, Svenningsen S, Kirby M, et al. Is Computed Tomography Airway Count Related to Asthma Severity and Airway Structure and Function? *Am J Respir Crit Care Med* 2020;201:923-933.
199. Tajiri T, Niimi A, Matsumoto H, et al. Comprehensive efficacy of omalizumab for severe refractory asthma: a time-series observational study. *Ann Allergy Asthma Immunol* 2014;113:470-475 e472.
200. Haldar P, Brightling CE, Singapuri A, et al. Outcomes after cessation of mepolizumab therapy in severe eosinophilic asthma: a 12-month follow-up analysis. *J Allergy Clin Immunol* 2014;133:921-923.
201. Haldar P, Brightling C, Hargadon B. Mepolizumab and exacerbations of refractory eosinophilic asthma. *N Engl J Med* 2011;364:588.
202. Przybyszowski M, Gross-Sondej I, Zarychta J, et al. Late Breaking Abstract - The impact of treatment with mepolizumab on airway remodeling in patients with severe eosinophilic asthma. *European Respiratory Journal* 2021;58.
203. Zha W, Kruger SJ, Cadman RV, et al. Regional Heterogeneity of Lobar Ventilation in Asthma Using Hyperpolarized Helium-3 MRI. *Acad Radiol* 2018;25:169-178.
204. Mummy DG, Kruger SJ, Zha W, et al. Ventilation defect percent in helium-3 magnetic resonance imaging as a biomarker of severe outcomes in asthma. *J Allergy Clin Immunol* 2018;141:1140-1141 e1144.
205. Svenningsen S, Eddy RL, Lim HF, Cox PG, Nair P, Parraga G. Sputum Eosinophilia and Magnetic Resonance Imaging Ventilation Heterogeneity in Severe Asthma. *Am J Respir Crit Care Med* 2018;197:876-884.
206. Mummy DG, Carey KJ, Evans MD, et al. Ventilation defects on hyperpolarized helium-3 MRI in asthma are predictive of 2-year exacerbation frequency. *J Allergy Clin Immunol* 2020;146:831-839 e836.
207. Nishimoto K, Karayama M, Inui N, et al. Relationship between fraction of exhaled nitric oxide and airway morphology assessed by three-dimensional CT analysis in asthma. *Sci Rep* 2017;7:10187.
208. Laitinen LA, Laitinen A, Haahtela T. Airway mucosal inflammation even in patients with newly diagnosed asthma. *Am Rev Respir Dis* 1993;147:697-704.
209. Holgate ST, Wenzel S, Postma DS, Weiss ST, Renz H, Sly PD. Asthma. *Nat Rev Dis Primers* 2015;1:15025.

210. Fehrenbach H, Wagner C, Wegmann M. Airway remodeling in asthma: what really matters. *Cell Tissue Res* 2017;367:551-569.
211. Paganin F, Mangiapan G, Proust A, et al. Lung function parameters in omalizumab responder patients: An interesting tool? *Allergy* 2017;72:1953-1961.
212. Caminati M, Cegolon L, Vianello A, et al. Mepolizumab for severe eosinophilic asthma: a real-world snapshot on clinical markers and timing of response. *Expert Rev Respir Med* 2019;13:1205-1212.
213. Busse WW, Bleecker ER, FitzGerald JM, et al. Long-term safety and efficacy of benralizumab in patients with severe, uncontrolled asthma: 1-year results from the BORA phase 3 extension trial. *Lancet Respir Med* 2019;7:46-59.
214. Corren J, Castro M, O'Riordan T, et al. Dupilumab Efficacy in Patients with Uncontrolled, Moderate-to-Severe Allergic Asthma. *J Allergy Clin Immunol Pract* 2020;8:516-526.
215. Mesnil C, Raulier S, Paulissen G, et al. Lung-resident eosinophils represent a distinct regulatory eosinophil subset. *J Clin Invest* 2016;126:3279-3295.
216. Balestrieri B, Granata F, Loffredo S, et al. Phenotypic and Functional Heterogeneity of Low-Density and High-Density Human Lung Macrophages. *Biomedicine* 2021;9.
217. Varricchi G, de Paulis A, Marone G, Galli SJ. Future Needs in Mast Cell Biology. *Int J Mol Sci* 2019;20.
218. Varricchi G, Marone G, Kovanen PT. Cardiac Mast Cells: Underappreciated Immune Cells in Cardiovascular Homeostasis and Disease. *Trends Immunol* 2020;41:734-746.
219. Varricchi G, Pecoraro A, Loffredo S, et al. Heterogeneity of Human Mast Cells With Respect to MRGPRX2 Receptor Expression and Function. *Front Cell Neurosci* 2019;13:299.
220. Varricchi G, Loffredo S, Borriello F, et al. Superantigenic Activation of Human Cardiac Mast Cells. *Int J Mol Sci* 2019;20.
221. Cristinziano L, Modestino L, Antonelli A, et al. Neutrophil extracellular traps in cancer. *Semin Cancer Biol* 2021.
222. Burn GL, Foti A, Marsman G, Patel DF, Zychlinsky A. The Neutrophil. *Immunity* 2021;54:1377-1391.
223. Vivanco Gonzalez N, Oliveria JP, Tebaykin D, et al. Mass Cytometry Phenotyping of Human Granulocytes Reveals Novel Basophil Functional Heterogeneity. *iScience* 2020;23:101724.
224. Zhang J, Dong L. Status and prospects: personalized treatment and biomarker for airway remodeling in asthma. *J Thorac Dis* 2020;12:6090-6101.
225. Dougherty RH, Sidhu SS, Raman K, et al. Accumulation of intraepithelial mast cells with a unique protease phenotype in T(H)2-high asthma. *J Allergy Clin Immunol* 2010;125:1046-1053 e1048.
226. Balzar S, Fajt ML, Comhair SA, et al. Mast cell phenotype, location, and activation in severe asthma. Data from the Severe Asthma Research Program. *Am J Respir Crit Care Med* 2011;183:299-309.

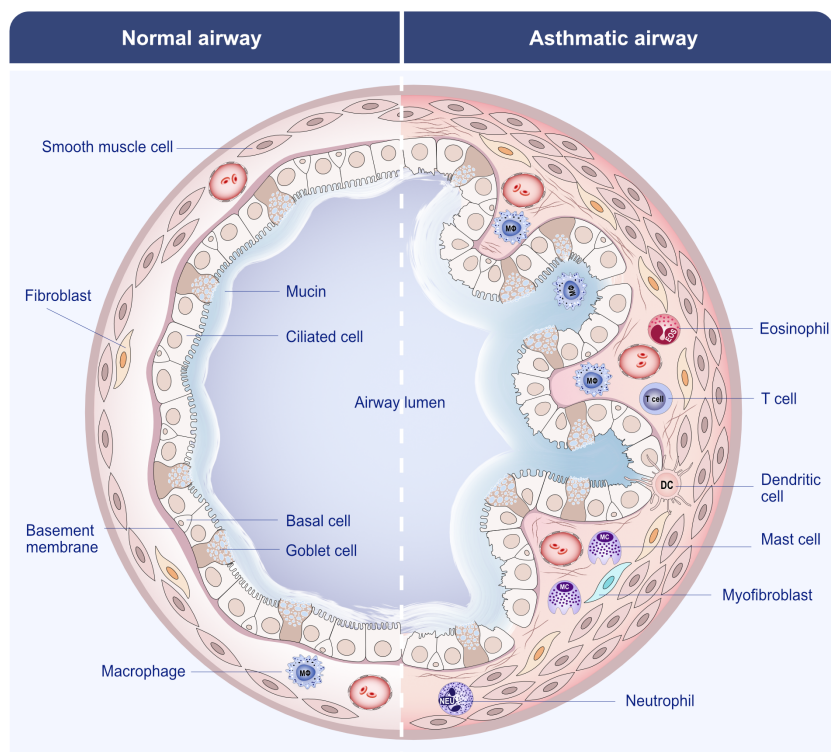


Figure 1_Varricchi et al.

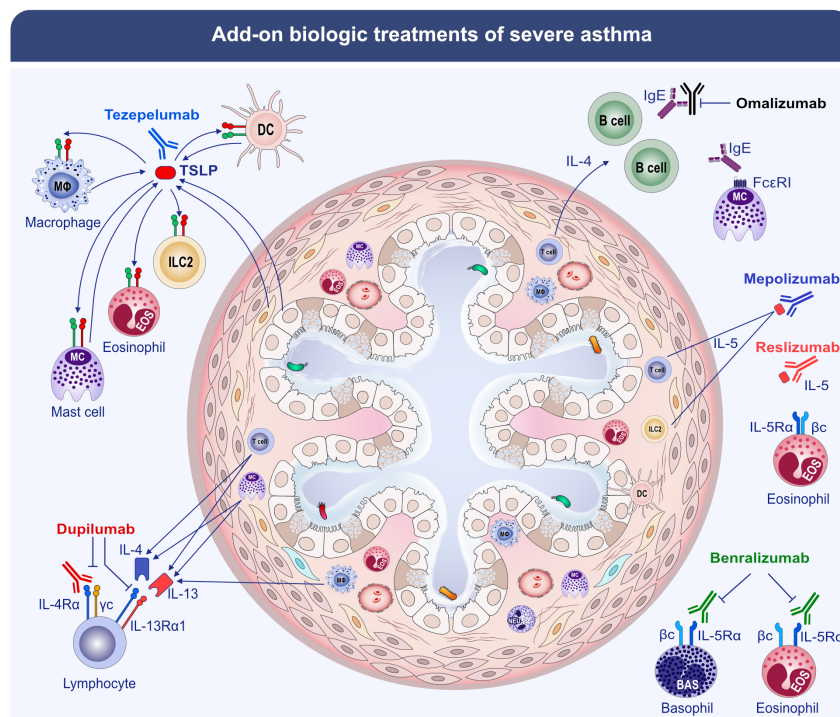


Figure 2_Varricchi et al.

Hosted file

Table 1_.docx available at <https://authorea.com/users/478366/articles/566649-biologics-and-airway-remodeling-in-severe-asthma>