

# Transient left phrenic nerve paralysis after ethanol infusion into the vein of Marshall

Wataru Sasaki<sup>1</sup>, Yosuke Nakatani<sup>1</sup>, Yutaka Take<sup>1</sup>, Shohei Kishi<sup>1</sup>, and Shigeto Naito<sup>1</sup>

<sup>1</sup>Gunma Kenritsu Shinzo Kekkan Center

April 11, 2022

## Abstract

An 80-year-old man underwent catheter ablation for atrial tachycardia (AT), which developed after catheter ablation for atrial fibrillation. The AT was diagnosed as dual-loop tachycardia, which included peri-mitral and roof-dependent ATs. An ethanol infusion into the vein of Marshall resulted in left phrenic nerve paralysis. During the procedure, the phrenic nerve paralysis was completely relieved.

## Transient left phrenic nerve paralysis after ethanol infusion into the vein of Marshall

Wataru Sasaki, MD; Yosuke Nakatani, MD; Yutaka Take, MD; Shohei Kishi, MD; and Shigeto Naito, MD.

Division of Cardiology, Gunma Prefectural Cardiovascular Center, Gunma, Japan

Funding: None

*Disclosures:* None

Address for correspondence: Dr. Yosuke Nakatani, Division of Cardiology, Gunma Prefectural Cardiovascular Center, 3-12 Kameizumi-machi Kou, Maebashi, Gunma 371-0004, Japan. Telephone: +81-27-269-7455; Fax: +81-27-269-1492; E-mail: yosuke3gbst@gmail.com

## ABSTRACT

An 80-year-old man underwent catheter ablation for atrial tachycardia (AT), which developed after catheter ablation for atrial fibrillation. The AT was diagnosed as dual-loop tachycardia, which included peri-mitral and roof-dependent ATs. An ethanol infusion into the vein of Marshall resulted in left phrenic nerve paralysis. During the procedure, the phrenic nerve paralysis was completely relieved.

## KEYWORDS

Atrial tachycardia; the vein of Marshall; phrenic nerve paralysis; catheter ablation.

## INTRODUCTION

Ethanol infusion into the vein of Marshall (Et-VOM) is a promising approach for treating atrial fibrillation (AF) and atrial tachycardia (AT). Although this approach is highly feasible, several complications have been reported.<sup>1</sup> Here, we present a rare complication of Et-VOM-induced left phrenic nerve paralysis.

## CASE PRESENTATION

An 80-year-old man was referred to our facility for catheter ablation of an atrial tachycardia (AT) that developed after atrial fibrillation (AF) ablation. The previous procedure consisted of pulmonary vein isolation and cavotricuspid isthmus ablation. An AT with a tachycardia cycle length of 230 ms was detected on a

baseline surface electrocardiogram (Fig. 1A). A decapolar catheter was positioned in the coronary sinus. The CARTO 3 system (Biosense-Webster, Inc., Diamond Bar CA) was used for electroanatomical mapping. Contact mapping was performed using a 20-pole high-density mapping catheter (PENTARAY; Biosense-Webster, Inc). The activation map suggested a dual-loop tachycardia mechanism; one circuit is a peri-mitral AT with a counterclockwise direction, and another is a roof-dependent AT around the left pulmonary veins (Fig. 1B and 1C). Since the lateral mitral isthmus was the common isthmus of the two circuits, we performed Et-VOM to create a block line on the lateral mitral isthmus. After occluding the vein of Marshall with an over-the-wire balloon catheter, 10 ml of 98% ethanol was injected in three divided doses. We did not observe the leakage of ethanol into the coronary sinus. During Et-VOM, the tachycardia cycle length was increased to 290 ms. After Et-VOM, the local staining was observed around the vein of Marshall (Fig. 2A). In the voltage map, an extensive endocardial scar was visible on the left atrial ridge and lateral mitral isthmus (Fig. 2B and 2C). Although the diaphragmatic motion was normal at baseline (Fig. 3A and 3B, and Supplementary Movie 1), the left phrenic nerve paralysis (PNP) was recognized after Et-VOM (Fig. 3C and 3D, and Supplementary Movie 2). A review of the fluoroscopic image revealed that the motion of the left diaphragm weakened immediately after the initial injection of ethanol. Seven minutes after the last ethanol injection, the left PNP gradually started to relieve. Adjunctive radiofrequency application to the lateral mitral isthmus terminated the AT, and the block line was finally created. At the end of the procedure, the left PNP was completely relieved, and no symptoms were observed after the procedure.

## DISCUSSION

Et-VOM may cause several complications, such as cardiac tamponade, stroke, anaphylactic shock, atrioventricular block, and left atrial appendage isolation.<sup>1</sup> The left phrenic nerve injury, however, has not been reported as a complication of Et-VOM. Catheter ablation can injure the left phrenic nerve for its proximity to several heart structures. The left phrenic nerve is at risk of injury during radiofrequency application to a left posterolateral accessory pathway,<sup>2</sup> and the left PNP is one of the critical complications during cryoballoon ablation of the left superior pulmonary vein.<sup>3</sup>

The left phrenic nerve runs dorsally to the left brachiocephalic vein and anterolateral to the aortic arch and pulmonary trunk.<sup>4</sup> After that, it descends toward the cardiac apex following three courses: (1) along a course related to the anterior surface of the heart (anterior course), (2) pass leftward along a course related to the apex of the left atrial appendage and obtuse margin of the left ventricle (lateral course), or (3) pass posteriorly to the inferior surface of the left ventricle (inferior course). In particular, the inferior course shows the shortest distance to the left superior pulmonary vein.<sup>4</sup> Scarring caused by Et-VOM was observed on the left lateral ridge anterior to the left superior pulmonary vein in this case (Fig. 2B). This finding presumes that Et-VOM directly injured the left phrenic nerve with an inferior course. Since the vein of Marshall is an epicardial structure, ethanol exuding from it may damage pericardial structures. The tissue staining around the vein of Marshall (Fig. 2A) after Et-VOM supports this hypothesis. However, epicardium insulation of the left phrenic nerve may have kept the left PNP transient.

To our best of knowledge, this is the first case report of the Et-VOM-related left PNP. Fortunately, the left PNP was transient in this case; however, the persistent left PNP might be caused in patients with a shorter distance between the left PNP and the vein of Marshall. We should know the risk of the left PNP and keep a close observation of the diaphragmatic movement during Et-VOM.

## REFERENCE

1. Kamakura T, Derval N, Duchateau J, Denis A, Nakashima T, Takagi T, Ramirez FD, André C, Krisai P, Nakatani Y, Tixier R, Chauvel R, Cheniti G, Kusano K, Cochet H, Sacher F, Hocini M, Jaïs P, Haïssaguerre M, Pambrun T. Vein of Marshall Ethanol Infusion: Feasibility, Pitfalls, and Complications in Over 700 Patients. *Circ Arrhythm Electrophysiol*. 2021 Aug;14(8):e010001. doi: 10.1161/CIRCEP.121.010001. Epub 2021 Jul 19. PMID: 34280029; PMCID: PMC8376276.
2. Rumbak MJ, Chokshi SK, Abel N, Abel W, Kittusamy PK, McCormack J, Patel MM, Fontanet H. Left phrenic nerve paresis complicating catheter radiofrequency ablation for Wolff-Parkinson-White syndrome.

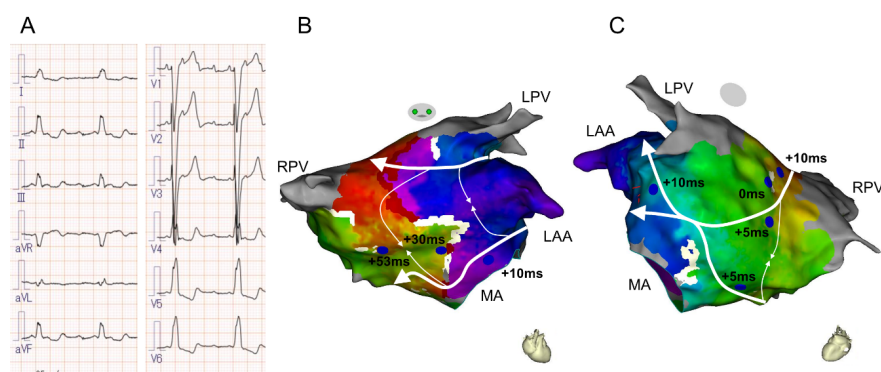
Am Heart J. 1996 Dec;132(6):1281-5. doi: 10.1016/s0002-8703(96)90477-9. PMID: 8969585.

3. Andrié RP, Schrickel JW, Nickenig G, Lickfett L. Left phrenic nerve injury during cryoballoon ablation of the left superior pulmonary vein. *Pacing Clin Electrophysiol*. 2012 Nov;35(11):e334-6. doi: 10.1111/j.1540-8159.2012.03470.x. Epub 2012 Jul 30. PMID: 22845556.

4. Sánchez-Quintana D, Ho SY, Climent V, Murillo M, Cabrera JA. Anatomic evaluation of the left phrenic nerve relevant to epicardial and endocardial catheter ablation: implications for phrenic nerve injury. *Heart Rhythm*. 2009 Jun;6(6):764-8. doi: 10.1016/j.hrthm.2009.02.029. Epub 2009 Feb 24. PMID: 19427272.

## FIGURES

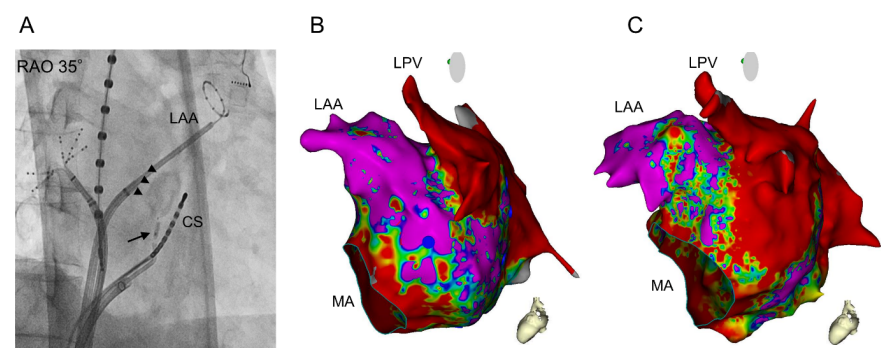
Figure 1



**Figure 1. Surface electrocardiogram and activation map of atrial tachycardia (AT)**

(A). Surface electrocardiogram of the AT. AT wave showed positive deflection in inferior leads and V1. AT cycle length was 230 ms. (B, C) The activation (white arrows) suggested a dual-loop tachycardia with a circuit on the mitral annulus (MA) and another around the left pulmonary veins (LPVs). Note that the lateral mitral isthmus was a common isthmus. The blue tags and numbers on the map show entrainment-pacing sites and the post-pacing interval minus the tachycardia cycle length. LAA, left atrial appendage; RPV, right pulmonary vein.

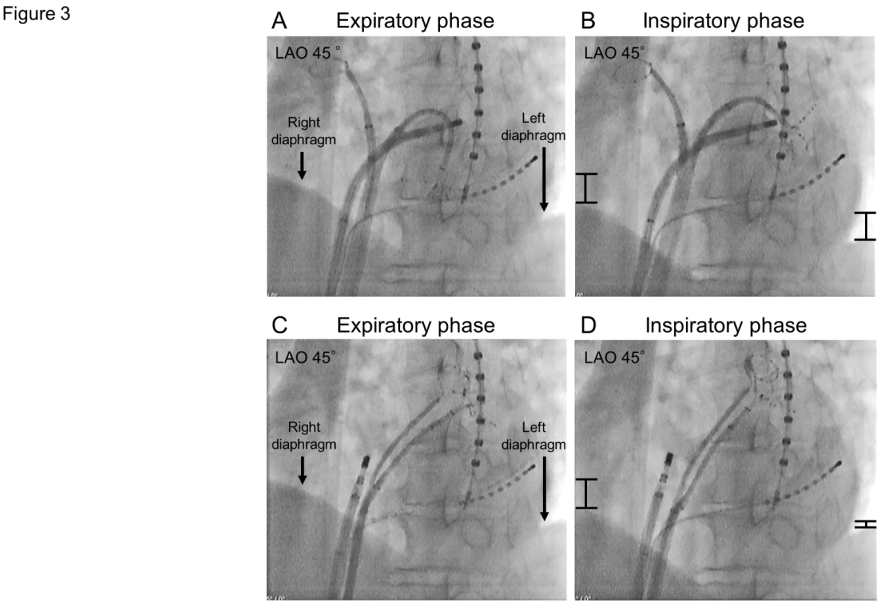
Figure 2



**Figure 2. The impact of ethanol infusion into the vein of Marshall (Et-VOM)**

(A) A fluoroscopic image in the right anterior oblique (RAO) 35° view after Et-VOM. A circular catheter was positioned in the left atrial appendage (LAA). The vein of Marshall was occluded with an over-the-wire

balloon catheter (arrow). Local tissue staining was observed around the vein of Marshall (arrowheads). (B) Bipolar voltage map in the left lateral view before Et-VOM. (C) Bipolar voltage map after Et-VOM. An extensive scar appeared on the left atrial ridge and lateral mitral isthmus. Note that the impact of Et-VOM extended to the basal left atrial appendage (LAA). CS, coronary sinus. Other abbreviations are as in Fig. 1.



**Figure 3. The diaphragmatic motion before and after ethanol infusion into the vein of Marshall.**

(A, B) Fluoroscopic images in the left anterior oblique (LAO) 45° view before Et-VOM. Compared to the expiratory phase (A), both the right and left diaphragms sufficiently moved downward in the inspiratory phase (B). Bars indicate the motion of diaphragms. (C, D) After Et-VOM. Although diaphragmatic even-  
tration was not observed in the expiratory phase (C), the movement of the left diaphragm with inspiration weakened after Et-VOM (D).