

Transmigration of Copper IUCD leading to Abdominal Abscess: A Case Report

Ramesh Lamichhane¹, Swati Kumari², and Anuska Khadka³

¹Jalalabad Ragib Rabeya Medical College

²Vatsalya Health Care

³Lumbini Medical College

March 31, 2022

Abstract

Far migrated IUCD is an uncommon condition that has different manifestations depending upon its location. We present the case of a 22-year-old primipara who had a spontaneous abortion after IUCD placement and suffered chronic right lower abdominal pain thereafter. Diagnostic laparoscopy revealed Cu-IUCD in the right iliac fossa.

INTRODUCTION

Copper intrauterine contraceptive device (IUCD) is one of the pillars of contraception in a developing country like Bangladesh, as it is both cheap and reliable.¹ It is generally safe and widely accepted, but rarely it may be associated with life-threatening complications like uterine perforation and migration.² The incidence of uterine perforation varies and is around 13/1000 insertions.³ Also, the reported incidence of the transmigration of the IUCD from the uterus to the neighbouring organs is 1-3/1000 IUCD insertions.⁴ The perforation has a high tendency to occur on insertion, as the IUCD can become embedded in the uterus and later be forced through the walls by uterine contractions. In a few instances, IUCD has been reported in abdominal viscera, most commonly in the sigmoid colon.⁵ There is a high chance of chronic inflammation surrounding the misplaced IUCD, which produces chronic abdominal pain and complications, and the complications could persist for years, even after the removal of an IUCD because of the dense adhesions that develop in response to the inflammation.⁶ Cases of misplaced IUCD need to be reported because of their unusual presentations and occasional catastrophic complications. These isolated rare incidences of mishaps may impact the acceptance of family planning services in developing countries. Hence, here we present a case of a 22-year-old female with right lower abdominal pain, due to an abscess in the parietal wall caused by the far-migrated copper intrauterine contraceptive device.

CASE REPORT

A 22-year-old para 1, regularly menstruating female presented to the emergency of Jalalabad Ragib Rabeya Medical College, Bangladesh on June 15, 2021, with acute right lower abdominal pain, fever, and leukocytosis for 3 days. With the suspicion of acute appendicitis, diagnostic laparoscopy was done, however, a dislocated Cu IUCD leading to an abdominal abscess was discovered. The lady had initially not given the history of Copper IUCD insertion as she believed it had not been placed properly. But on further questioning post-operatively it was discovered that she had a copper intrauterine contraceptive device (IUCD) inserted 2 years ago after the delivery of her first child. Post insertion of the device, the patient did not follow up with a gynaecologist. She could not palpate the strings of the device and assumed that insertion of the device was not done properly. She didn't go to follow up due to personal reasons even after failing to palpate the string of IUCD. Moreover, the patient conceived 1 month after the insertion of the device, further confirming her

belief that the device wasn't actually placed inside her as it should have been. The patient started having spontaneous vaginal bleeding at 8 weeks of gestation which led to spontaneous abortion. After the expulsion of the product of conception, she went to a local health clinic and ultrasound showed complete expulsion of the product of conception. At the clinic she did not give a history of the insertion of Copper IUCD and the ultrasound scan at that time showed an empty uterine cavity with a small blood clot at the cervix and bilateral ovaries were normal looking. There was no mention of Cu IUCD in the scan. After a few weeks of abortion, she started having nonspecific dull abdominal pain for which she got treated conservatively with analgesics in the local health clinic.

On June 15, 2021, the patient presented to the emergency of our hospital with acute right lower abdominal pain for 3 days as aforementioned. At the time of examination, her temperature was 101 degrees Fahrenheit, BP- 110/50 mm of Hg, RR- 15 breath/min, Pulse- 98/min. Abdominal examination revealed tenderness in the right iliac fossa, guarding, rigidity, and rebound tenderness. Ultrasonography of the abdomen revealed mixed echoic lesion measuring about 3.5× 1.5 cm and minimal collection in the right iliac fossa region (Figure 1). Blood investigations revealed leukocytosis with 88% neutrophilia. Other blood investigations and biochemistry were within normal limits. With the provisional diagnosis of acute appendicitis, laparoscopy was planned. Laparoscopy revealed a normal appendix but found an abscess approximately 4 x 3 cm in the parietal wall of the abdomen near the right iliac fossa due to a copper IUCD. The right fallopian tube was found adherent with the abscess cavity. Adhesiolysis was done and the abscess was drained (Figure 2). The device was removed from the peritoneal cavity, and shown to the patient after she recovered from surgery (Figure 3). The drain tube was kept in situ post-operatively. The postoperative recovery was uneventful and the patient was discharged on the 4th postoperative day with oral antibiotics.

DISCUSSION

Transmigration of IUCD, a rare catastrophic complication of IUCD insertion, usually occurs at the time of insertion, as might have happened with our case since the lady was not able to feel the strings the next day.⁷ Moreover, the incorrect positioning of the IUCD is the result of faulty technique and insertion by insufficiently trained staff.⁸

Copper-containing devices can cause massive inflammation and recurrent pregnancy losses following uterine perforation and peritoneal reaction.⁸ Similarly, the miscarriage seen in this patient could have been a result of a damaged, perforated uterus unable to sustain the pregnancy. The complete extrusion of a malpositioned IUCD through myometrium is facilitated by the uterine contractions and the pressure difference between the higher pressure uterus and the lower pressure peritoneal cavity. Contractions of the abdominal organs i.e. urinary bladder, intestine as well as the movement of the peritoneal fluid may further facilitate the migration of the IUCD in the peritoneal cavity which can explain how the IUCD in our patient ended up in the anterior parietal abdominal wall.⁹ The transmigration of the malpositioned IUCD could have started when the uterus was contracting violently to expel the miscarriage and further progressed due to bowel peristalsis and changes in patient position.

Ultrasound is the optimal modality in case of non-visualization of the IUCD thread, as it is both cost-effective and can accurately identify the misplaced device. A plain radiograph of the abdomen may also be done to detect the device. Also, to see the exact distance of the IUCD from the uterine cavity, uterine sound can also be used during radiographic examination.¹⁰ In our case, although ultrasound was done, the IUCD was not clearly visualized. If the initial post-miscarriage ultrasound had visualized the device, further complications like adhesions and abscess formation could have been prevented.

According to WHO, removal of the misplaced or malpositioned IUCD is mandated because of the risk of injury to the adjoining organs and medico legal issues, even if the patient is asymptomatic. Laparoscopy is the preferred modality for the removal of misplaced IUCDs, but laparotomy is rarely required in very complicated cases.¹¹ A misplaced IUCD device can often mimic appendicitis if it is found embedded in the appendix, causing an abscess formation in the right iliac fossa. Features such as fever, leukocytosis, vomiting, and features such as right iliac fossa tenderness may further cause diagnostic confusion.⁸ A similar thing

happened with our patient in which the laparoscopy was done with the provisional diagnosis of appendicitis, but IUCD was found accidentally.

CONCLUSION

We reported a case of a perforated uterus post IUCD insertion that led to the transmigration of IUCD, leading to an abdominal abscess. Such complications, though rare, may impact the overall uptake of contraception in developing countries. Hence, to reduce the failure rates and perforation of the uterus, the health staff should be adequately trained. Also, more surveillance is warranted post-IUCD insertion, and patients should be called regularly for follow-up from the clinic. Adequate counselling regarding the device placement and danger signs should also be explained. Misplaced IUCD should be considered when a patient is presenting with miscarriage and the history of IUCD placement should be asked for such patients even when the patients don't mention it themselves. Good counselling, proper follow-up, and timely diagnosis could have prevented the potentially fatal complication of foreign body reaction and abscess formation seen in our patient.

ACKNOWLEDGEMENTS

We would like to acknowledge Department of Surgery especially Dr Shaiek Aziz Chowdhury sir and Dr. Rubence Islam for providing the visual pictures taken in the operation theatre.

CONFLICT OF INTEREST: None.

AUTHOR CONTRIBUTION:

Ramesh Lamichhane(RL) and Swati kumari(SK) were involved in the concept of study and study design. RL, SK, and Anuska khadka(AK) were involved in the review of previous literature and the preparation of the draft of the manuscript. All authors individually did the final proofreading of the manuscript before submission.

ETHICAL APPROVAL

As case reports are exempt from ethical approval in our institution, our article which describes a case report does not require additional permissions from the Ethics committee.

CONSENT

Full written informed consent was obtained from the patient for publication of her case, clinical images, and radiographic images. A copy of written consent can be made available to the editor in chief of this journal upon request.

REFERENCES

1. Chi IC. An evaluation of the levonorgestrel-releasing IUD: its advantages and disadvantages when compared to the copper-releasing IUDs. *Contraception*. 1991 Dec;44(6):573–88.
2. Goldman JA, Peleg D, Feldberg D, Dicker D, Samuel N. IUD appendicitis. *Eur J Obstet Gynecol Reprod Biol*. 1983 Jul;15(3):181–3.
3. Singhal SR, Marwah DS, Paul A, Singhal SK. Missed Intra Uterine Device: A Rare Indication for Appendicectomy - Case Report with Review of Literature. *East and Central African Journal of Surgery*. 2010;15(2):156–8.
4. Sankareswari1 R, Indira2, K3 G, S4 V. MISPLACED AND MIGRATED IUCD: A CASE REPORT. *Journal of Evolution of Medical and Dental Sciences* 2014. 2014 Jun 21;3(25):7031–5.
5. Carson SA, Gatlin A, Mazur M. Appendiceal perforation by Copper-7 intrauterine contraceptive device. *Am J Obstet Gynecol*. 1981 Nov 1;141(5):586–7.
6. McLaughlin DI, Bevins W, Karas BK, Sonnenberg L. IUD appendicitis during pregnancy. *West J Med*. 1988 Nov;149(5):601–2.
7. Nigam, Ratna Biswas, Archana Mishra. Misplaced intrauterine contraceptive device: an enigma. *OAJC*. 2010 Dec;2011:2:1–3.

8. Johri V. Misplaced Intrauterine Contraceptive Devices: Common Errors; Uncommon Complications. JCDR. 2013;7(5):905–7.
9. Dr. Krupa.B.M, Dr. Manjula, Dr. Asha Swarup, "Case Report: Misplaced Copper - T Device", International Journal of Science and Research (IJSR), Volume 4 Issue 6, June 2015, 2229 - 2230
10. Raj AD, Singh MK, Soma MM. Misplaced IUCD: a case report. Int J Reprod Contracept Obstet Gynecol. 2018 Jun 27;7(7):2979.
11. Markovitch O, Klein Z, Gidoni Y, Holzinger M, Beyth Y. Extrauterine mislocated IUD: is surgical removal mandatory? Contraception. 2002 Aug;66(2):105–8.

FIGURES

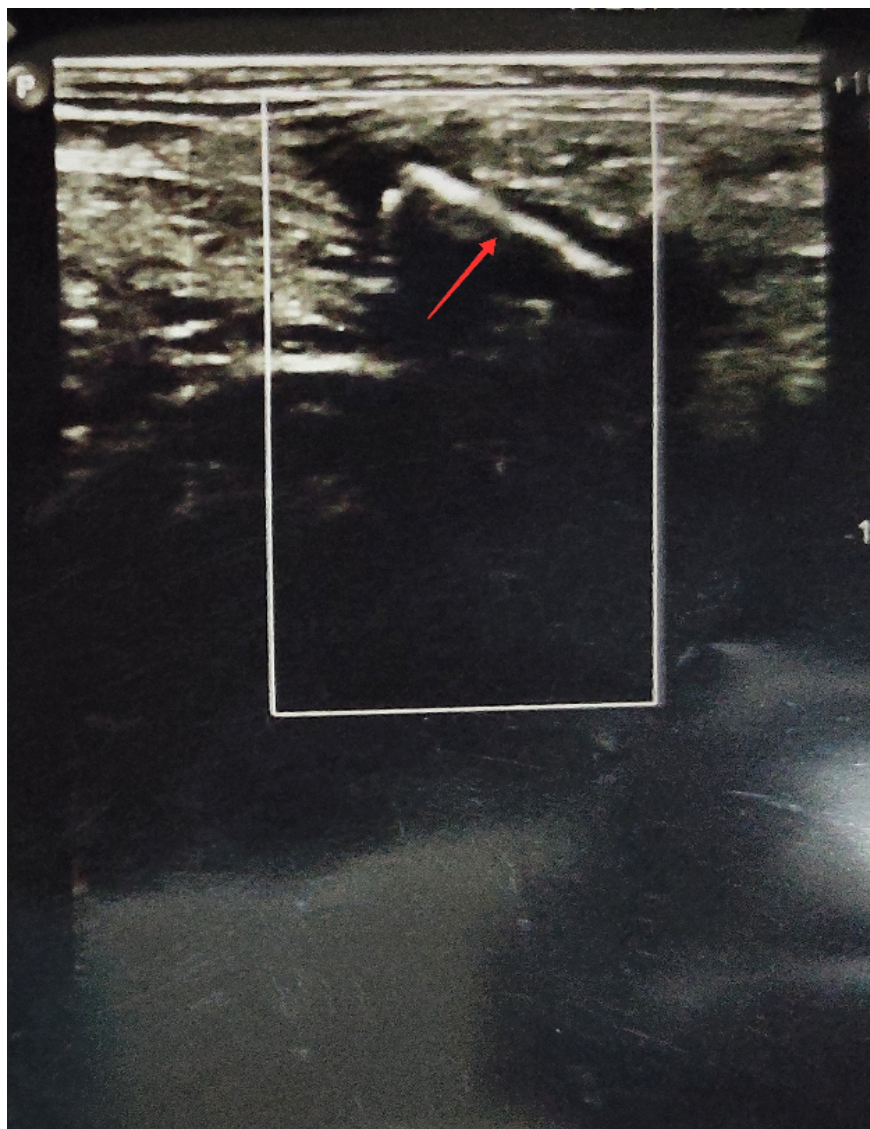

Figure 1: Ultrasonography of Abdomen showing mixed echoic lesion in Right iliac fossa.

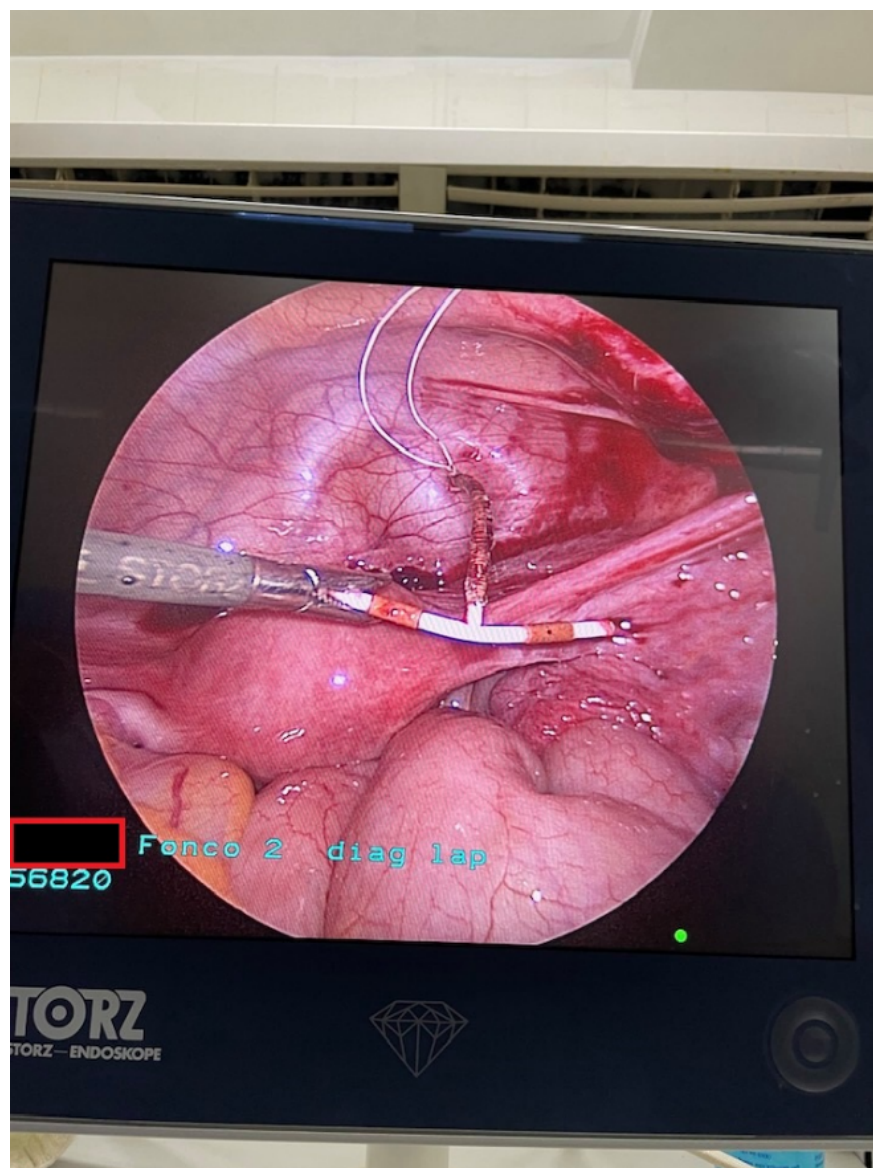


Figure 2: Diagnostic laparoscopy showing copper IUCD in the peritoneal cavity after adhesiolysis.

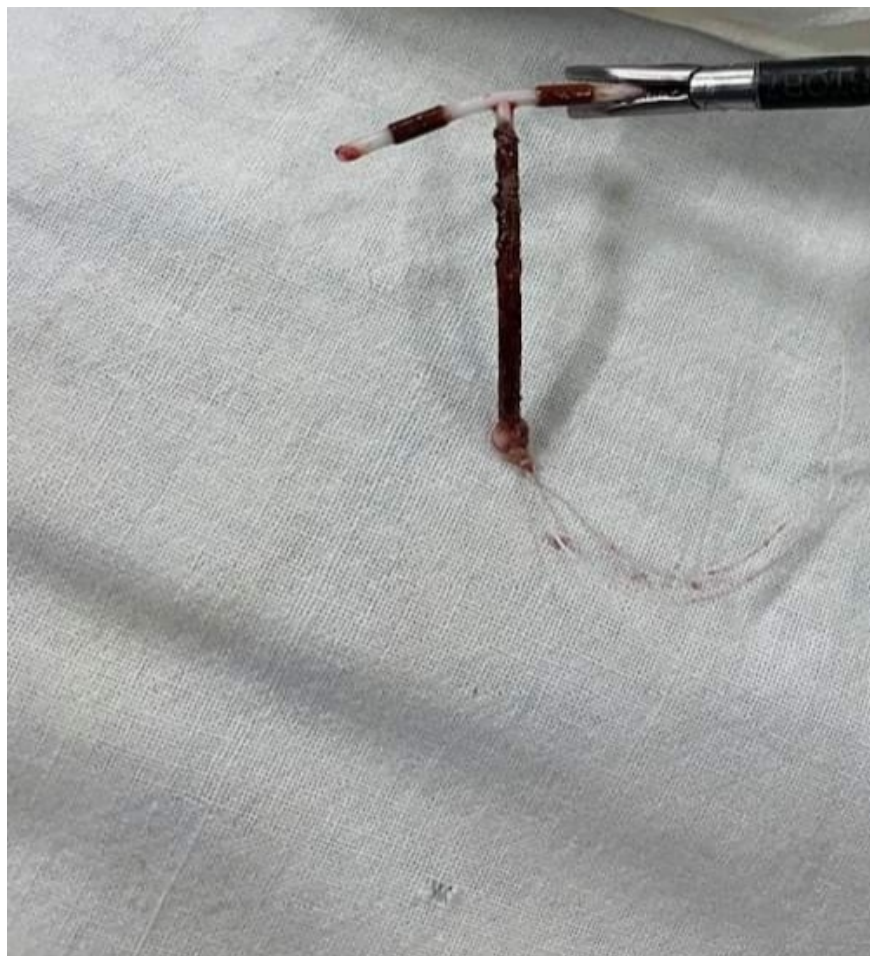

Figure 3: Copper IUCD after laparoscopic removal.

