

A Malignant Hepatoblastoma Mimicking a Benign Mesenchymal Hamartoma: Lessons Learned

Anuradha Singh¹, Kaitlyn Wong², Blayne Sayed², Paul Nathan¹, Furqan Shaikh³, Bo-Yee Ngan¹, and Andrea Doria⁴

¹The Hospital for Sick Children

²The Hospital for Sick Children Division of General and Thoracic Surgery

³The Hospital for Sick Children Department of Paediatrics

⁴Hospital for Sick Children

March 31, 2022

Abstract

Differentiating hepatoblastomas (HB) from other congenital benign hepatic tumours prior to surgical management decisions is key. We, herein, present an unusual case of an antenatally diagnosed liver lesion assessed in the neonatal period. Because of its predominantly cystic ultrasound/MRI appearance and borderline alpha-fetoprotein serum levels, the diagnosis of mesenchymal hamartoma was favoured and protocol-based tumor resection was performed. Due to the intra-operative diagnosis of fetal subtype HB with positive resection margins the child had to undergo a second laparotomy. This report raises awareness to an unusual appearance of HB and discusses non-invasive imaging clues to consider atypical appearances of HB pre-operatively as they can have profound implications in patient management.

TITLE PAGE

Title of the manuscript

A Malignant Hepatoblastoma Mimicking a Benign Mesenchymal Hamartoma: Lessons Learned

AUTHORS:

Anuradha Singh¹

Kaitlyn Wong²

Blayne A. Sayed²

Paul Nathan³

Furqan Shaikh³

Bo-Yee Ngan⁴

Andrea S. Doria¹

Complete affiliations of all authors

¹ Department of Diagnostic Imaging, Research Institute, The Hospital for Sick Children, and Department of Medical Imaging, University of Toronto, Toronto, ON, Canada

² Division of General & Thoracic Surgery, The Hospital for Sick Children, University of Toronto, Toronto, ON, Canada

³ Division of Hematology & Oncology, The Hospital for Sick Children, Toronto, ON, Canada

⁴ Department of Laboratory Medicine & Pathobiology, Anatomic Pathology, The Hospital for Sick Children, University of Toronto, Toronto, ON, Canada

Name, address, phone, fax and email contact for the corresponding author

Andrea S. Doria, The Hospital for Sick Children, 555 University Avenue, Toronto, ON M5G 1X8

Phone: 416-813-6079, **Fax:** 416-813-7591, **Email:** andrea.doria@sickkids.ca

Word Count for:

a) Abstract: 110 b) Main Text (excludes title page, abstract, Conflicts of Interest, Acknowledgments, References, Tables, Figures, and Legends); 1,667

Number of Tables, Figures, and Supporting Information files

8 images in total in two sets (Figures 1 and 2)

Short running title (not to exceed 50 characters);

Unusual cystic appearance of hepatoblastoma

Three to six keywords to index the content:

Cystic hepatoblastoma, mesenchymal hamartoma, alpha-fetoprotein

(AFP), neonate, perinatal, magnetic resonance imaging.

An abbreviations key in a table.

Abbreviation	Full term/phrase
HB	Hepatoblastoma
MH	Mesenchymal hamartoma
MR	Magnetic Resonance
AFP	Alfa-fetoprotein
CH	Congenital Hemangioma
WI	Weighted-Imaging
DWI	Diffusion-weighted imaging
IVC	Inferior vena cava

Papers that have been previously published as meeting abstracts should include a footnote on the title page indicating the name of the presentation, meeting name and date, and publication site of the abstract:

Not applicable.

Conflicts of interest

The authors of this manuscript declare no relationships with any companies whose products or services may be related to the subject matter of the article.

Declarations

The authors of this manuscript declare no relationships with any companies whose products or services may be related to the subject matter of the article.

Dr. Doria is the Principal Investigator of the following grants: Baxalta-Shire (Research Grant), Novo Nordisk (Research Grant), Terry Fox Foundation (Research Grant), PSI Foundation (Research Grant), Society of

Pediatric Radiology (Research Grant), Garron Family Cancer Centre (Research Grant).

Hosted file

Hepatoblastoma Case Report Clean_Feb23 2022.docx available at <https://authorea.com/users/471747/articles/563075-a-malignant-hepatoblastoma-mimicking-a-benign-mesenchymal-hamartoma-lessons-learned>

Fig. 1

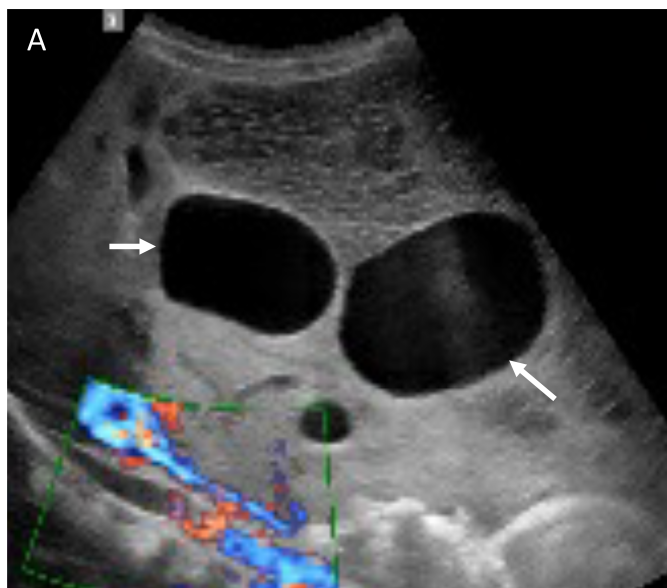


Fig. 1

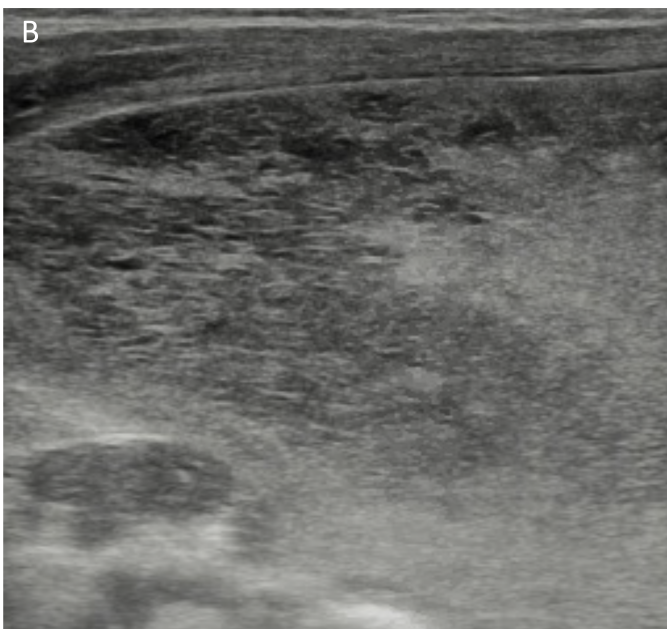


Fig. 1

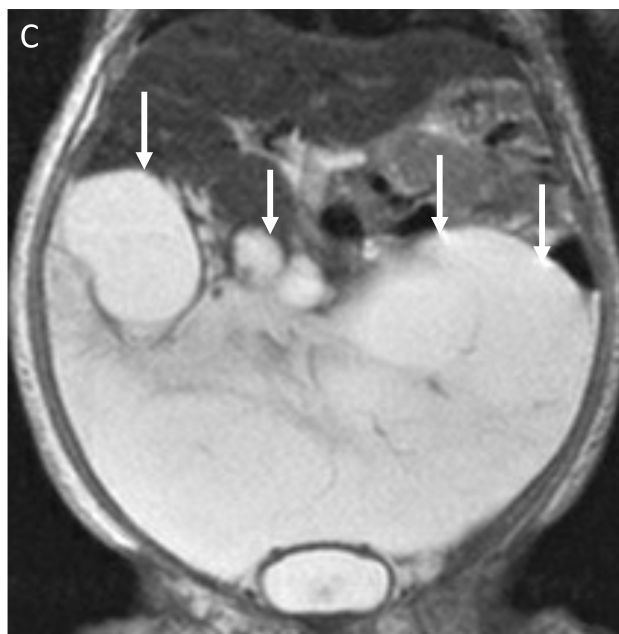


Fig. 1

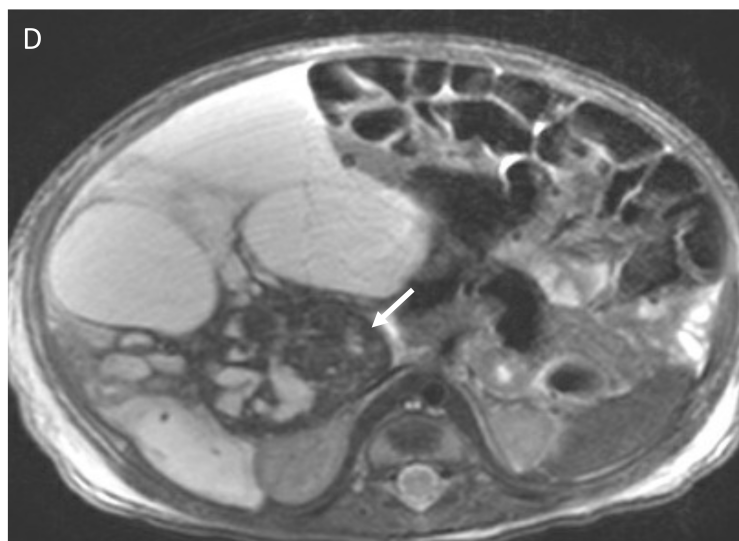


Fig. 1

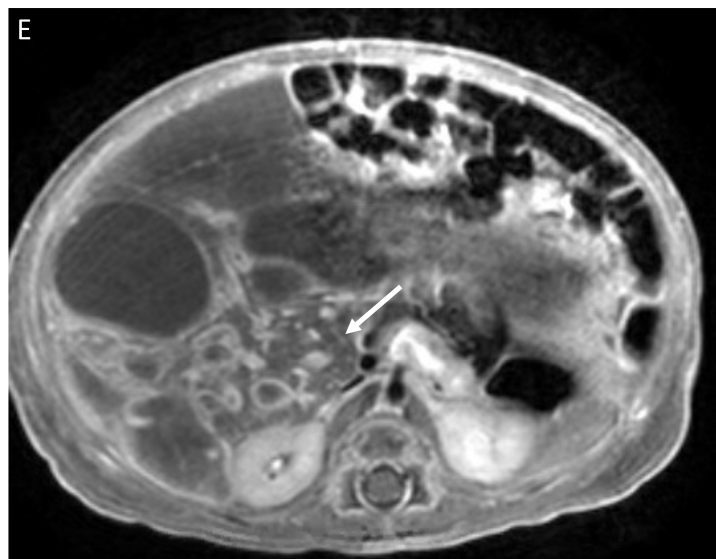


Fig. 2

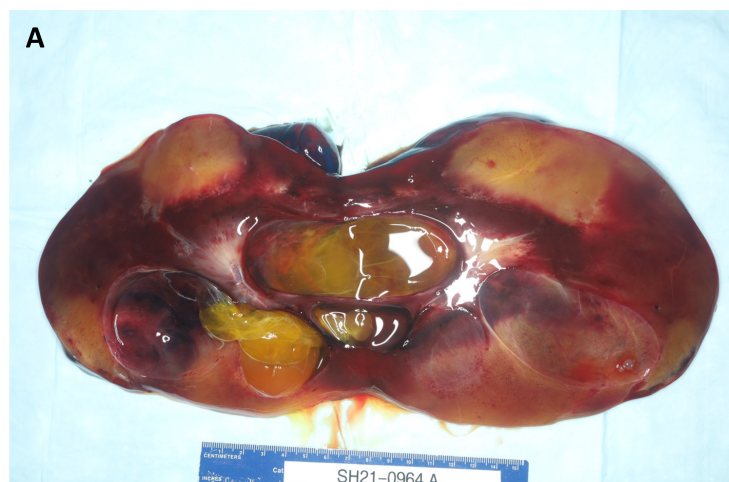

Fig. 2

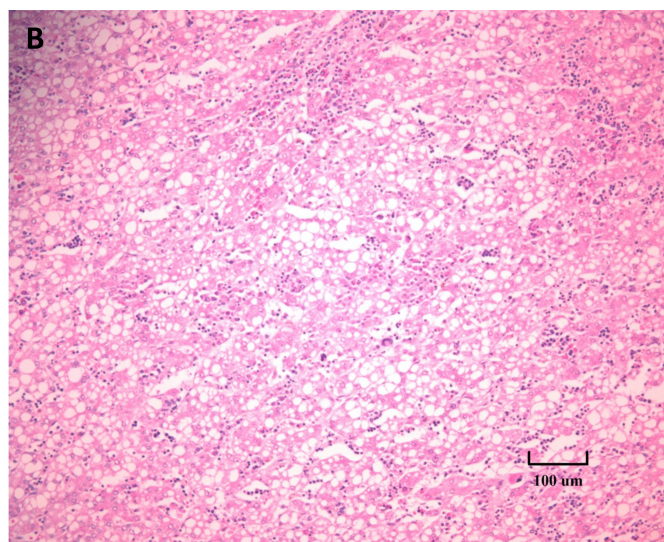


Fig. 2

