Individualized Stratified Treatment for Epstein-Barr Virus-associated Hemophagocytic Lymphohistiocytosis : A Case Report and Review of Literature.

Qiming Lu[1]

[1]Guangzhou University of Chinese Medicine

March 30, 2022

Abstract

In this case, we report a patient with Epstein-Barr virus-associated hemophagocytic lymphohistiocytosis, mainly manifesting as fever, no liver function damage or HLH related gene mutation. After treated with cortisol and intravenous immunoglobulin, the fever got controlled and most aboratory examinations returned to normal. It suggests that we should attach importance to individualized stratified treatment in clinical practice, avoid overtreatment, and reduce the toxic and side effects of drugs.

Introduction

Hemgocytic lymphphohistiocytosis(HLH), also known as hemophagocytic syndrome(HPS), first described in 1939 by pediatricians Scott and Robb-Smith, is a life-threatening disease characterized by uncontrolled hyperinflammation on the basis of various inheritedor acquired immune defects.[1] It has been suggested that the pathogenesis of this syndrome is uncontrolled T-cell activation, which causes oversecretion of Th1 cytokines such as IFN-g, IL-2, IL-6, IL-10 and heme-oxygenase-1 further activating T cells and monocytes/macrophages.[2-4] HLH may be familial or secondary to infections, malignancies, metabolic disorders. Infectious causes are mostly viral and Epstein-Barr virus(EBV) is the mostly frequently seen etiologic agent.[5] As the syndrome progresses rapidly and is often fatal, timely treatment with cortisol, cyclosporin and etoposide is recommended.

Case Summary

We report a case of a 12-year-old boy with EBV-HLH, whose parents strongly rejected cyclosporin A because of the toxic and side effects when we making the treatment plan and we finally gave the child antiviral therapy, corticosteroid and intravenous immunoglobulin(IVIG). After our treatment, the children's temperature dropped gradually and a number of indicators of laboratory examination gradually became normal after discharge. The children were followed up for 1 month later, and all indicators had been returned to normal, except triglyceride (triglyceride has been reduced to 2.86mmol/L).

Conclusion

This case suggests that secondary HLH should be treated by stratification.

Key words

Epstein-Barr Virus, Hemgocytic Lymphphohistiocytosis, Case Report

Case description

General information

The patient is 160 cm tall and weighs 49 kg.

Chief complaints

A 12-year-old male presented with fever for 4 days.

History of present illness

The child developed fever 4 days before the present admission and the heat peak reached 40.2. He was diagnosed as upper airway infection in a community hospital and given oral ibuprofen and oseltamivir. One day after the first consultation, the patient came to our hospital for further examination and treatment with ongoing fever. Laboratory results included a white blood cell(WBC) count of 1.50×10^9/L, neutrophils(NEU) country of 0.06×10^9/L, platelet(PLT) count of 60×10^9/L , and hemoglobin(HGB) level of 125g/L, indicating a decreased WBC, NEU, PLT count. Later the patient was admitted to our hospital.

Previous history

He had no glucose-6-phosphate dehydrogenase deficiency, no chronic disease, no infectious diseases.

Personal and family history

He had no new sexual contacts, recent travel, sick contacts, illicit drug use, no history of alcohol intake or smoking, nor any family history of other illnesses.

Physical examination

The vital signs included a blood pressure of 110/70mmHg, pulse rate of 128 beats/min, respiration of 22 times/min, maximum temperature of 40.2, and percutaneous oxygen saturation of 99% in room air. One soft lymph node with smooth surface and moderate mobility could be touched on the right neck, range at 10mmx15mm; other superficial lymph nodes were not enlarged. The liver was palpable 2cm below the right costal margin, with sharp edges; the spleen was palpable 2cm below the left costal margin, with blunt edges and no tenderness.

Laboratory examination

A full blood count indicated leukopenia agranulocytosis and thrombocytopenia with WBC count of $0.88\text{x}10^9$/L, NEU count of $0.06\text{x}10^9$/L and PLT count of $40\text{x}10^9$/L. The EBV DNA quantitative titer reached at $1.11\text{x}10^6$/L and EBVCA-IGM detetion was positive. The level of ferritin increased steadly and peaked at 3,406.49 ng/mL, triglyceride at 7.10mmol/L, NK cell activity at 2.8%, and SIL-2R /sCD25 at 3461U/mL. Bone marrow cytology showed active myelodysplastic with increased eosinophil ratio, decreased erythroid ratio, and decreased plateletforming megakaryocytes radio, as shown in figure 1 and figure 2. HLH - related mutations were not detected in the analysis of hemophagocytic syndrome mutations

Other laboratory examinations such as alanine aminotransferase, aspartate aminotransferase , total bilirubin, serum albumin, and prothrombin time etc were in normal level.

Imaging examination

Abdominal ultrasonography showed that the upper and lower diameter of the left lobe of the liver was 82mm, the anterior and posterior diameter was 60mm, the maximum oblique diameter of the right lobe of the liver was 122mm, the main portal vein diameter was about 9mm, and the liver was relatively large. The spleen was 123mm long, 38mm thick, 5mm wide, and enlarged.

Diagnosis

1. Hemgocytic Lymphphohistiocytosis 2. Epstein-Barr Virus Infection

Treatment

After symptomatic therapies were administered, the patient was prescribed antiviral therapy with acyclovir for 12 days. According to HLH-2004 protocol, the diagnosis of HLH was valid and it was secondary HLH.

We made a therapy scheme including corticosteroid and cyclosporin A. When we informing the parents of the children the necessity and toxic and side effects of this treatment, they strongly refused to perform chemotherapy with cyclosporin A to their kid, and finally the patient was treated with corticosteroid only. Besides he was also treated with IVIG.

Results and follow-up

After our therapies, the children's temperature dropped gradually, and laboratory tests showed an increase of the count of WBC, NEU, and PLT, and a decrease of the level of ferritin and triglyceride. On hospital day 14, the patient's condition improved and discharged with continue oral dexamethasone dosage of 7.5mg every day. After 23 days, we made a follow-up on telephone and realized the dosage of oral dexamethasone was reduced to 2.5mg. The patient also revealed us that all aboratory examinations returned to normal except triglyceride (triglyceride has been reduced to 2.86mmol/L).

Discussion

This is a case with a good outcome. Because the patient's families refused chemotherapy, we gave corticosteroid and intravenous immunoglobulin to the kid of EVB-HLH. After treatment, the condition of the children gradually improved. In this case, intravenous IVIG was given to the children and achieved good results. It has been reported that immunoglobulin therapy should be considered as a treatment option for HLH.[6] HLH is a syndrome of highly activated inflammation in the body, and IVIG can effectively suppress inflammatory cytokine storm. In this case, all indicators improved significantly after administering IVIG, suggesting that IVIG has a positive effect on the treatment of secondary HLH. In conventional EBV-HLH treatment scheme, it suggests that HLH patient should be treated with cyclosporin A and etoposide and some people notes that initial treatment using a protocol without etoposide were independent prognostic factors indicating resistant disease.[7] Another suggests that early immune therapy can regulate the activation of T cells, thus reduce unnecessary chemotherapy[8] and we found a report about two patients with EBV-HLH who experienced spontaneous resolution of their disease prior to the initiation of therapy, suggesting there may be a subgroup of patients with EBV-HLH who do well with conservative management and can avoid potentially toxic therapies.[9]Thus, we believes that the treatment of patients with EBV-HLH should be individualized, and further stratified treatment should be carried out for patients without HLH related gene mutation in the genetic test.

We suggest that corticosteroid and IVIG should be given to patients with secondary HLH who are mainly manifesting as fever, have no liver function damage and have no HLH related gene mutation, observe the symptoms of the children, check their body temperature, and timely review relevant indicators after treatment. After that, we can observe the symptoms of children, check their temperature, and timely review relevant indicators after treatment, and then further evaluate whether chemotherapy is needed.

Conclusion

This is a medical case of EBV-HLH without traditional treatment regimen but with good curative effect, suggesting that stratified treatment should be further adopted for secondary HLH to improve the curative effect and reduce the drug toxic and side effects.

Conflict of Interest Statement

We declare that we have no financial and personal relationships with other people or organizations that can inappropriately influence our work, there is no professional or other personal interest of any nature or kind in any product, service and/or company that could be construed as influencing the position presented in, or the review of, the manuscript entitled.

Acknowledgements

At the point of finishing this paper, I'd like to express my sincere thanks to all those who have lent me hands in the course of my writing this paper. I'd like to take this opportunity to show my sincere gratitude to my supervisor, Ms. Hu, who has given me so much useful advices on my writing.

Data availability Statement

The data used to support the findings of this study are available from the corresponding author upon request.

References

1. Janka GE. Familial and Acquired Hemophagocytic Lymphohistiocytosis. In: Caskey CT, Austin CP, Hoxie JA, eds. *Annual Review of Medicine, Vol 63.* Vol 63.2012:233-246.

2. Meeths M, Horne A, Sabel M, Bryceson YT, Henter J-I. Incidence and Clinical Presentation of Primary Hemophagocytic Lymphohistiocytosis in Sweden. *Pediatric Blood & Cancer.* 2015;62(2):346-352.

3. Osugi Y, Hara J, Tagawa S, et al. Cytokine production regulating Th1 and Th2 cytokines in hemophagocytic lymphohistiocytosis. *Blood.*1997;89(11):4100-4103.

4. Wada T, Muraoka M, Yokoyama T, Toma T, Kanegane H, Yachie A. Cytokine profiles in children with primary Epstein-Barr virus infection.*Pediatric Blood & Cancer.* 2013;60(7):E46-E48.

5. Devecioglu O, Anak S, Atay D, et al. Pediatric Acute Lymphoblastic Leukemia Complicated by Secondary Hemophagocytic Lymphohistiocytosis.*Pediatric Blood & Cancer.* 2009;53(3):491-492.

6. Dumancas CY, Reyes HAG, Cosico J, Savadkar A, Lah S. Streptococcus Pneumoniae-Related Hemophagocytic Lymphohistiocytosis Treated with Intravenous Immunoglobulin (IVIG) and Steroids. *American Journal of Case Reports.* 2018;19:25-28.

7. Xu X-J, Wang H-S, Ju X-L, et al. Clinical presentation and outcome of pediatric patients with hemophagocytic lymphohistiocytosis in China: A retrospective multicenter study. *Pediatric Blood & Cancer.*2017;64(4).

8. Shiraishi A, Ohga S, Doi T, et al. Treatment choice of immunotherapy or further chemotherapy for Epstein-Barr virus-associated hemophagocytic lymphohistiocytosis. *Pediatric Blood & Cancer.*2012;59(2):265-270.

9. Belyea B, Hinson A, Moran C, Hwang E, Heath J, Barfield R. Spontaneous Resolution of Epstein-Barr Virus-Associated Hemophagocytic Lymphohistiocytosis. *Pediatric Blood & Cancer.*2010;55(4):754-756.

Legends

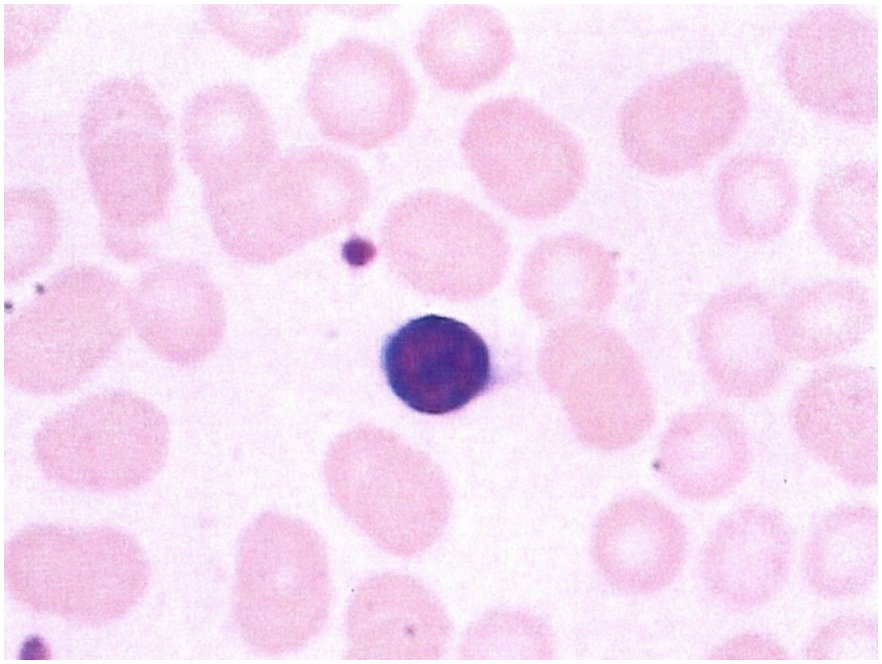

Figure 1 Active myelodysplastic in bone marrow with increased eosinophil ratio, decreased erythroid ratio, and decreased plateletforming megakaryocytes radio.

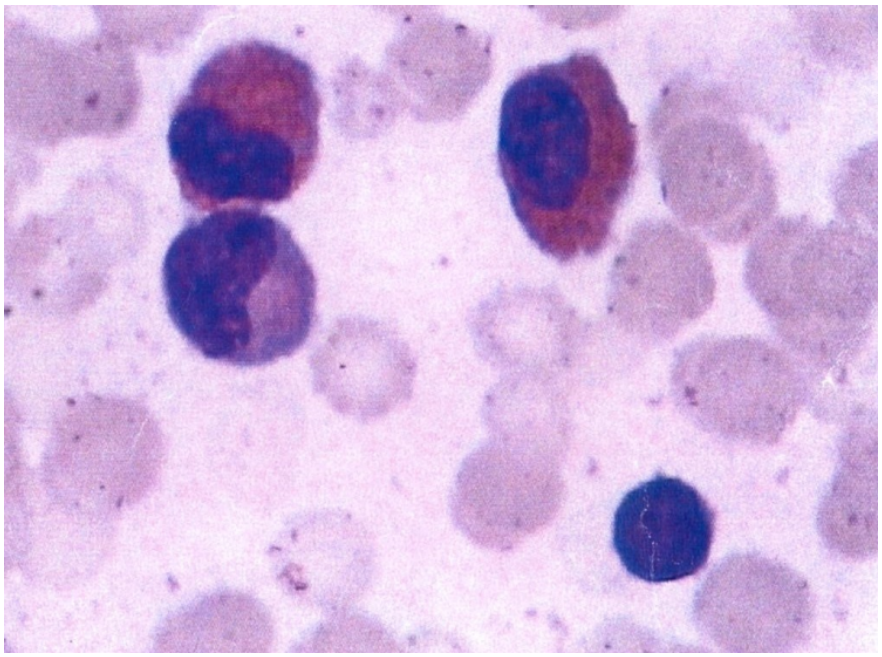

Figure 2 Active myelodysplastic in bone marrow with increased eosinophil ratio, decreased erythroid ratio, and decreased plateletforming megakaryocytes radio.