Posted on Authorea 22 Nov 2021 — The copyright holder is the author/funder. All rights reserved. No reuse without permission. — https://doi.org/10.22541/au.163757117.76864751/v1 — This a preprint and has not been peer reviewed. Data may be preliminary.

An unusual complication after augmentation genioplasty: odontogenic infection requiring implant removal

Tania Hassanzadeh[1] and Arnold Lee[1]

[1]Tufts Medical Center

November 22, 2021

Abstract

Augmentation genioplasty is a common surgical procedure with extremely low infection rates. We present the case of a healthy middle-aged woman who experienced years of chronic infection after chin implantation due to a fractured mandibular canine root, which is exceedingly rare. Awareness of this potential complication will reduce patient morbidity.

An unusual complication after augmentation genioplasty: odontogenic infection requiring implant removal

Tania Hassanzadeh, MD[1] and Arnold S. Lee, MD[1]

[1]*Otolaryngology – Head and Neck Surgery, Tufts Medical Center, Boston, MA, USA*

Corresponding author:

Tania Hassanzadeh

Tufts Medical Center, Department of Otolaryngology-HNS

800 Washington Street, Box 850

Boston, MA 02111

thassanzadeh@tuftsmedicalcenter.org

310-872-7377

Manuscript word count: 720 words

Key Clinical Message

Odontogenic infection can result in adverse outcomes following augmentation genioplasty and uncommonly may require implant removal. Comprehensive pre-operative dental evaluation is recommended to prevent undue patient morbidity.

Abstract

Augmentation genioplasty is a common surgical procedure with extremely low infection rates. We present the case of a healthy middle-aged woman who experienced years of chronic infection after chin implantation due to a fractured mandibular canine root, which is exceedingly rare. Awareness of this potential complication may reduce patient morbidity.

Keywords

- Ear, nose and throat

Posted on Authorea 22 Nov 2021 — The copyright holder is the author/funder. All rights reserved. No reuse without permission. — https://doi.org/10.22541/au.163757117.76864751/v1 — This a preprint and has not been peer reviewed. Data may be preliminary.

- Dentistry
- Infectious diseases
- Health maintenance

Introduction

Microgenia may be corrected through augmentation or osseous (sliding) genioplasty. Alloplastic implantation is often performed using solid silicone (Silastic) and high-density porous polyethylene (Medpor). Infection rates are exceedingly rare, with incidences less than 1% reported in the literature[1,2]. We describe a case of augmentation genioplasty complicated by chronic infection from an odontogenic source, leading to implant removal several years after the initial surgery.

Case Report

The patient is a 54-year-old healthy woman who presented in January 2016 to discuss revision rhinoplasty and augmentation genioplasty (Figure 1). The surgery was performed in September 2016 without complication. A sublabial incision was used for the approach, and a medium-sized Medpor implant was inserted using aseptic technique. No anatomic abnormality of the mandible or dentition was identified. The patient was discharged on antibiotic prophylaxis. She was pleased with the aesthetic outcome and had a benign immediate postoperative examination (Figure 1).

Waxing and waning right-sided chin swelling and tenderness began in October 2016. With a presumed diagnosis of surgical wound infection, she was treated with multiple courses of oral antibiotics in an attempt to salvage the chin implant. She reported no dental pain or dental symptoms at the time. In July 2017 she experienced intraoral abscess formation requiring drainage at a local emergency room. Cultures grew mixed bacterial flora. Despite multiple antibiotic courses and chlorhexidine oral rinse, her symptoms did not resolve completely. Recommendations were made to remove the implant, but she declined.

Surgical exploration of the chin implant site was first performed in the clinic in August 2019. Granulation tissue and a scant amount of purulent drainage were encountered. The granulation tissue was excised, and the area was copiously irrigated with antibiotic saline solution. She had temporary resolution of her symptoms until January 2020, when a repeat incision and drainage was required. Despite initial improvement, the infection persisted. Implant removal was again advised, but the patient expressed reluctance. In July 2020 her dentist identified an infected left mandibular molar that was drilled, but there was no concern for odontogenic disease directly adjacent to the implant. CT facial bones was subsequently obtained without evidence of odontogenic infection, fluid collection, or neoplasm (Figure 2).

She ultimately agreed to proceed with surgical removal in February 2021. Intraoperative findings were notable for an area around tooth #27 that was open and exposed. Purulence was encountered and drained. Copious granulation tissue was discovered underlying the implant on removal, which was found to be originating from the root of tooth #27. This was fractured and had eroded through the buccal cortex of the mandible (Figure 3). The implant was removed and she was referred to her dentist for further treatment. She has done well since, remaining infection-free.

Discussion

This case highlights a complicated course following augmentation genioplasty ultimately requiring implant removal. A fracture of tooth #27 was found to be the culprit, but this was not evident on oral examination, dental evaluation, CT scan, and two surgical explorations. Only two reports exist in the literature describing odontogenic infection with direct extension to an alloplastic chin implant[3,4]. In both cases, the implant was removed[3,4]. Although a rare problem, the associated morbidity of surgical site infection, adverse antibiotic reactions and resistance, and surgical failure are significant. We suggest comprehensive preoperative dental evaluation prior to augmentation genioplasty with an alloplastic implant. Osseous genioplasty may be considered as an alternative given lower reported infection rates and morbidity[1].

Conclusion

Posted on Authorea 22 Nov 2021 — The copyright holder is the author/funder. All rights reserved. No reuse without permission. — https://doi.org/10.22541/au.163757117.76864751/v1 — This a preprint and has not been peer reviewed. Data may be preliminary.

We present an unusual case of augmentation genioplasty complicated by an odontogenic infection. The nidus was a fracture of the root of tooth #27 eroding through the cortex of the mandible, which was only discovered at the time of implant removal. Preoperative dental evaluation and consideration of osseous over augmentation genioplasty may minimize infection risk and patient morbidity in the setting of dental disease.

Authorship List:

Tania Hassanzadeh: Conception of project, preparation of manuscript, critical revisions

Arnold Lee: Conception of project, preparation of manuscript, critical revisions

Both authors contributed equally to this project and agree to the by-line as listed.

Acknowledgements:

None

Ethical Statement:

The authors report no conflicts of interest. No funding was received for this project. Patient consent was obtained and anonymity has been preserved. This project was exempt from Institutional Review Board (IRB) review, and documentation confirming this policy has been provided.

Patient Consent:

Informed consent was signed and collected from the patient in accordance with the journal's patient consent policy.

References

1. Baus, A., Rem, K., Revol, M., Cristofari, S. (2018). Prosthetic genioplasty versus osseous genioplasty in aesthetic chin augmentation: Literature review and knowledge update. *Annales de chirurgie plastique esthétique* : 63: 255-261.
2. Rojas, Y.A., Sinnott, C., Colasante, C., Samas, J., Reish, R.G. (2018). Facial implants: Controversies and Criticism. A comprehensive review of the current literature. *Plastic and Reconstructive Surgery.* 142(4): 991-999.
3. Hasson, O., Gideon, L., Conley, R. (2007). Late infections associated with alloplastic facial implants. *Journal of Oral and Maxillofacial Surgery.* 65: 321-323.
4. Hoffman, S. (1981). Loss of a silastic chin implant following a dental infection. *Annals of Plastic Surgery.* 7(6): 484-486.

Figure Legends

Figure 1: Pre-operative (left) and post-operative (right) comparison photographs status-post revision rhinoplasty and augmentation genioplasty.

Figure 2: CT Facial Bones from July 2020 demonstrating the chin implant in position with overlying soft tissue attenuation and fat stranding, but without a discrete fluid collection, mass, or odontogenic infection.

Figure 3: Intraoperative photograph at time of implant removal demonstrating a fracture of the root of tooth #27 eroding through the buccal cortex of the mandible (indicated by arrow).

Posted on Authorea 22 Nov 2021 — The copyright holder is the author/funder. All rights reserved. No reuse without permission. — https://doi.org/10.22541/au.163757117.76864751/v1 — This a preprint and has not been peer reviewed. Data may be preliminary.

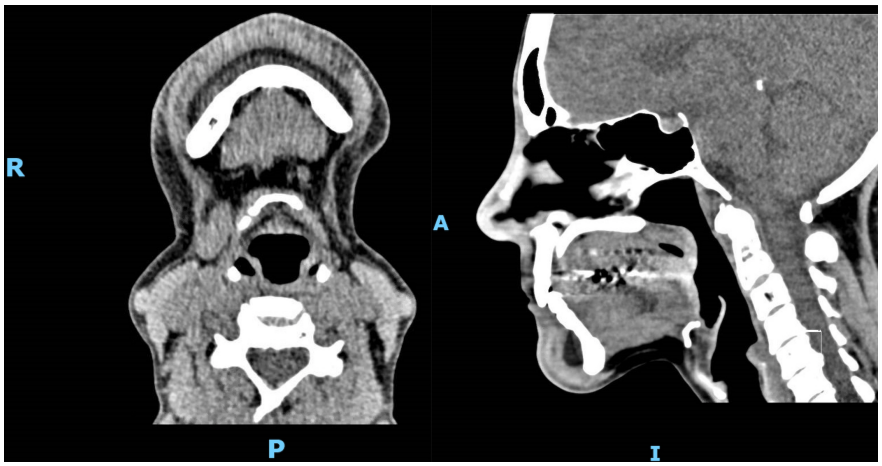

Posted on Authorea 22 Nov 2021 — The copyright holder is the author/funder. All rights reserved. No reuse without permission. — https://doi.org/10.22541/au.163757117.76864751/v1 — This a preprint and has not been peer reviewed. Data may be preliminary.