

Cavitary Lung Lesions in a Neonate: Potential Manifestation of COVID-19 related Multisystem Inflammatory Syndrome

anish bakhle¹, kavita sreekumar¹, bonny baracho¹, sanjay sardesai¹, and M.P. Silveira¹

¹Goa Medical College

March 07, 2024

Abstract

Background: The hyperinflammatory state of Multisystem inflammatory syndrome in children (MIS-C) predisposes to thromboembolic complications. We report a neonate with multiple cavitary lesions in lung, which we suspect could be a manifestation of MIS following maternal COVID-19 infection during pregnancy. **Case report:** 8 day old neonate was referred with fever and fast breathing. Mother was positive for COVID-19 in 29th week. COVID-19 RT-PCR was negative, however, antibodies were positive. He had increased leucocyte count, and elevated levels of C-Reactive protein(CRP), Procalcitonin, Ferritin, Lactate dehydrogenase(LDH), and D-dimer along with bilateral reticulonodular opacities on chest radiograph and multiple nodules with evidence of cavitation in both lungs on Chest Tomography. All cultures were negative. A possible diagnosis of MIS was made. Infant was treated with Intravenous Immunoglobulin (IVIG) which he responded to with resolution of symptoms. **Conclusion:** Neonates exposed to COVID-19 should be evaluated for thromboembolic complications and IVIG can be one of the treatment modalities.

TITLE: Cavitary Lung Lesions in a Neonate: Potential Manifestation of COVID-19 related Multisystem Inflammatory Syndrome

Anish Bakhle^a, Kavita Sreekumar^{a*}, Bonny Baracho^a, Sanjay Sardesai^b, M.P. Silveira ^a

^a Department of Pediatrics, Goa Medical College, Bambolim, Goa, India

^b Department of Radiodiagnosis, Goa Medical College, Bambolim, Goa, India

* Corresponding Author:

Dr. Kavita Sreekumar,

Associate Professor,

Department of Pediatrics

Goa Medical College

Bambolim

Panaji, Goa, 403202, India

Tel: (+91) 9422454850

E-mail: kantakum@yahoo.com

ORCID ID: 0000-0002-7824-5839

Funding: None

Disclosure statement : None to be declared

Consent to publish statement : written informed consent was obtained from parents for publication of the details of their child's case.

Cavitary Lung Lesions in a Neonate: Potential Manifestation of COVID-19 related Multisystem Inflammatory Syndrome

ABSTRACT:

Background: The hyperinflammatory state of Multisystem inflammatory syndrome in children (MIS-C) predisposes to thromboembolic complications. We report a neonate with multiple cavitary lesions in lung, which we suspect could be a manifestation of MIS following maternal COVID-19 infection during pregnancy.

Case report : 8 day old neonate was referred with fever and fast breathing. Mother was positive for COVID-19 in 29th week. COVID-19 RT-PCR was negative, however, antibodies were positive. He had increased leucocyte count, and elevated levels of C-Reactive protein(CRP), Procalcitonin, Ferritin, Lactate dehydrogenase(LDH), and D-dimer along with bilateral reticulonodular opacities on chest radiograph and multiple nodules with evidence of cavitation in both lungs on Chest Tomography. All cultures were negative. A possible diagnosis of MIS was made. Infant was treated with Intravenous Immunoglobulin (IVIG) which he responded to with resolution of symptoms.

Conclusion: Neonates exposed to COVID-19 should be evaluated for thromboembolic complications and IVIG can be one of the treatment modalities.

Keywords : COVID-19, Neonate, thromboembolism, Pulmonary cavities, Multisystem Inflammatory syndrome

INTRODUCTION:

In December of 2019, a new strain of Corona virus emerged in Wuhan, China which resulted in the COVID-19 pandemic¹. Among the children infected by the virus, most are asymptomatic and only few, especially infants and those with co-morbid conditions, have severe disease². However, MIS-C, is a more severe form of disease occurring 4-5 weeks after the infection, and capable of causing multiorgan failure³. The hyperinflammatory state of MIS-C predisposes to a prothrombotic coagulopathy known as thrombo-inflammation making patients prone to thromboembolic complications including Pulmonary thromboembolism (PTE)⁴. Winant et al³ observed segmental pulmonary emboli in patients of MIS-C on thoracic imaging and recommended to have high suspicion of embolism in these patients. There are now emerging reports of Neonatal MIS-C (MIS-N), mainly presenting with cardiac manifestations, ground glass opacities in the lungs and elevated inflammatory markers^{5,6,7,8,9}. PTE is not common among the neonatal population and is a consequence of imbalance between procoagulant and anticoagulant systems¹⁰. Indwelling central lines, fluid instabilities, sepsis, liver dysfunction, congenital heart disease, occult malignancy, and systemic inflammation contribute to the risk profile for thromboembolism in critical neonates^{10,11}.

Here we report a rare case of a neonate born to a mother with COVID 19 infection during pregnancy, who presented to us with respiratory distress, raised inflammatory markers and having cavitary and nodular lesions in the lung, which we suspect could have resulted from thromboembolic complication of MIS-N.

CASE REPORT:

An 8-day old male born at 37weeks by Caesarean section to Primigravida mother was referred to our unit with fever, lethargy, and respiratory distress. Mother was diagnosed with SARS-CoV2 infection at 29 weeks of gestation which was mild and had received symptomatic treatment. The total leukocyte count was 31200/cu.mm with 54% neutrophils, positive CRP, raised procalcitonin, and bilateral reticulonodular opacities involving middle and upper zones of lungs on chest radiograph (Table 1, Fig 1a). The neonate was

initiated on broad spectrum antibiotics and nasal prong oxygen. Real-time reverse transcription polymerase chain reaction test (RT-PCR) for SARS- CoV2 was negative. Two Blood Cultures were sterile; Cerebrospinal fluid and urine cultures were normal. The infant continued to have fever spikes along with respiratory distress and oxygen requirement. Given the maternal history of COVID infection, nonspecific radiographic findings, with all cultures being sterile, additional investigations were carried out for presence of inflammatory markers, COVID antibodies, D-Dimer levels, 2D Echocardiogram and HRCT (Table 1, Fig 1b,c). High resolution Chest Tomography (HRCT) showed multiple nodules of varying sizes, conglomerate at places noted in both lungs. Majority of the nodules showed evidence of cavitation. Upon doing an interval scan, some nodules which were solid on the earlier scan showed evidence of cavitation. Imaging findings were suggestive of septic embolization of the lungs. Ultrasonography of the abdomen and contrast enhanced CT of whole body was done. Multiorgan affection with similar cavitory lesions or any malignant focus was ruled out. In view of the lab reports suggestive of inflammatory syndrome (leucocytosis, elevated CRP and Procalcitonin, and reactive COVID-19 antibodies) with non-resolving symptoms, a decision was taken to administer Intravenous Immunoglobulin (IVIG) at 1g/kg/day for 3 days following which the child became asymptomatic and was off oxygen support. In view of the cavitory lesions, investigation for active Tuberculosis was carried out in the neonate and the parents which were also negative. To rule out the possibility of malignancy other tumour markers like β - Human Chorionic Gonadotropin (HCG) and Alpha Feto Protein were done, which were within normal limits. Post IVIG, fever spikes subsided, distress gradually settled and neonate was discharged on breast feeds. On follow up, child is developmentally normal with adequate weight gain.

DISCUSSION:

Vertical transmission of the virus may be rare due to low placental expression of the canonical receptors necessary for viral entry¹². However, placentas from infected mothers have shown thrombotic and vascular changes, which suggests that SARS-CoV2 is a highly procoagulant infection and even in the absence of fetal viral infection, it can trigger an inflammatory response, leading to multiorgan damage¹³. There are multiple case reports of neonates presenting majorly with cardiac manifestations of shock, arrhythmias, thrombosis, Persistent pulmonary hypertension, as well as respiratory failure, neurological abnormalities and hematological manifestations^{5,6,7,8,9,14}. All these neonates had history of exposure to maternal COVID-19 infection during pregnancy, positive SARS-CoV2 antibodies and elevated inflammatory and prothrombotic laboratory markers. In a case series of 20 neonates with MIS-N, reported by Pawar et al⁵, they used diagnostic criteria modified from Centre of Disease Control criteria for MIS-C and interim guidance from American Academy of Pediatrics to accommodate lack of fever in neonates and source of primary infection (mother, instead of the child). The neonate described by us fulfilled these modified criteria. Coagulation abnormalities and thromboembolic phenomenon are listed as one of potential complications of MIS-C¹⁵. D-dimer levels have been stated to be the best test for evaluating hemostatic variations associated with COVID-19⁴. Such thromboembolic phenomena are also reported among infants. In a retrospective cohort study by Whitworth et al¹⁵, out of all children aged 0-<21 years admitted with SARS-CoV2 infection or MIS-C, 20 patients were identified with thromboembolism with an incidence of 6.5% in MIS-C patients, out of which 3 patients had pulmonary embolism. 1 patient was <1year of age and had lower extremity deep vein thrombosis. Perveen et al¹⁶, reported a neonate born with an ischemic limb to a COVID-19 positive mother. Although, COVID antibodies were found in the newborn, the coagulation workup was normal. The thromboembolic event was thought to be a vascular effect of the COVID infection¹⁶. In another case reported by Engert et al⁷, a moderate preterm infant had petechial bleeds, intracranial haemorrhage and periventricular leukomalacia with elevated D-dimer levels and low platelet counts. The authors hypothesised this to be secondary to maternal hyperinflammatory response following SARS-CoV2 infection during 2nd trimester of pregnancy⁷. In the case series of 20 neonates, Pawar et al described one neonate with a cardiac thrombus⁵. Mamishi et al¹⁷ studied the CT findings in 24 children with SARS-CoV2 infection. Atypical findings were seen in 58% of the patients which included nodular and cavitory lesions. They suggested that atypical findings may be indicative of disease progression caused due to cytokine storm¹⁷. The HRCT in our case showed nodular lesions with central cavitation. In spite of an extensive investigative work up, we could not find a causal relationship of the CT scan findings to any of the conditions that could have caused it like bacterial or fungal

sepsis, tuberculosis, congenital lung anomalies or malignancy¹⁸. Endothelial injury by SARS-CoV-2 and the hypercoagulability caused by the intense inflammatory response is capable of causing the PTE^{4,11}. The presence of in-utero exposure to COVID 19 virus, raised inflammatory markers and elevated D-dimer levels lead us to conclude that our case could have had pulmonary thromboembolic phenomenon as a consequence of MIS-N which resulted in the rare CT picture of nodular and cavitary lung lesions. However, due to lack of adequate evidence regarding its use in neonates with MIS-N, we did not give antithrombotic medications. The neonate responded to IVIG and had complete recovery of his clinical symptoms. Due to this favourable response, we chose to not give steroids as is recommended in MIS-C.

Considering the potential possibility of the pulmonary lesions in our case to be secondary to MIS-N, we suggest that, clinical and laboratory evaluation to diagnose thromboembolic complications should be carried out in all symptomatic neonates exposed to SARS-CoV2 infection. Also, future research should be planned to study the use of antithrombotic prophylaxis in neonates exposed to the virus.

CONCLUSION:

MIS-N is no longer a hypothesis, but an actual disease entity with multiple reports available in literature. This disease is ever-evolving with widening scope of symptomatology. Thromboembolic complications secondary to inflammatory response after SARS-CoV2 exposure should be considered in infants and children. It is essential for the neonatologists to consider the possibility of MIS-N in neonates with in-utero exposure for early diagnosis and management as well as share the data for better understanding of the disease and framing the best treatment practices. Diagnostic criteria and management strategies for MIS-N as well as thromboembolism in MIS-N should be developed, distinct from those currently available for children.

REFERENCES:

1. Zhu N, Zhang D, Wang W, Li X, Yang B, Song J, et al. A Novel Coronavirus from Patients with Pneumonia in China, 2019. *N Engl J Med*. 2020;382(8):727–33.
2. Dong Y, Dong Y, Mo X, Hu Y, Qi X, Jiang F, et al. Epidemiology of COVID-19 among children in China. *Pediatrics*. 2020;145(6).
3. Winant AJ, Blumfield E, Liszewski MC, Kurian J, Foust AM, Lee EY. Thoracic Imaging Findings of Multisystem Inflammatory Syndrome in Children Associated with COVID-19: What Radiologists Need to Know Now. *Radiol Cardiothorac Imaging*. 2020;2(4):e200346.
4. Carneiro JDA, Ramos GF, de Carvalho WB, Johnston C, Delgado AF. Proposed recommendations for antithrombotic prophylaxis for children and adolescents with severe infection and/or multisystem inflammatory syndrome caused by SARS-CoV-2. *Clinics (Sao Paulo)*. 2020;75:e2252.
5. Maternal P, Series S-AC, Pawar R, Gavade V, Patil N, Girwalkar A. Neonatal Multisystem Inflammatory Syndrome (MIS-N). 2021;(May):1–15.
6. Kappanayil M, Balan S, Alawani S, Mohanty S, Leeladharan SP, Gangadharan S, et al. Multi-system inflammatory syndrome in a neonate, temporally associated with prenatal exposure to SARS-CoV-2: a case report. *Lancet Child Adolesc Heal Internet*. 2021;5(4):304–8. Available from: [http://dx.doi.org/10.1016/S2352-4642\(21\)00055-9](http://dx.doi.org/10.1016/S2352-4642(21)00055-9)
7. Engert V, Siau C, Stock A, Rehn M, Wöckel A, Härtel C, et al. Severe Brain Damage in a Moderate Preterm Infant as Complication of Post-COVID-19 Response during Pregnancy. *Neonatology*. 2021;1–4.
8. McCarty KL, Tucker M, Lee G, Pandey V. Fetal inflammatory response syndrome associated with maternal SARS-CoV-2 infection. *Pediatrics*. 2021;147(4).
9. Khaund Borkotoky R, Banerjee Barua P, Paul SP, Heaton PA. COVID-19-Related Potential Multisystem Inflammatory Syndrome in Childhood in a Neonate Presenting as Persistent Pulmonary Hypertension of the Newborn. *Pediatr Infect Dis J*. 2021;40(4):E162–4.

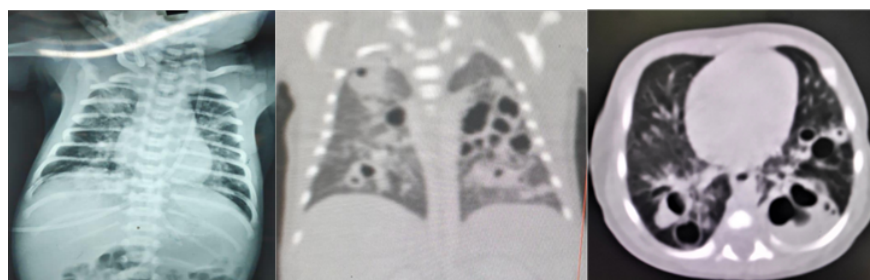
10. Paes BA, Nagel K, Sunak I, Rashish G, Chan AK. Neonatal and infant pulmonary thromboembolism: A literature review. *Blood Coagul Fibrinolysis*. 2012;23(7):653–62.
11. Haley KM. Neonatal Venous Thromboembolism. *Front Pediatr*. 2017;5(June):1–6.
12. Pique-Regi R, Romero R, Tarca AL, Luca F, Xu Y, Alazizi A, et al. Does the human placenta express the canonical cell entry mediators for sars-cov-2? *Elife*. 2020;9:1–15.
13. Prochaska E, Jang M, Burd I. COVID-19 in pregnancy: Placental and neonatal involvement. *Am J Reprod Immunol*. 2020;84(5):1–9.
14. Ramanathan K, Antognini D, Combes A, Paden M, Zakhary B, Ogino M, et al. Since January 2020 Elsevier has created a COVID-19 resource centre with free information in English and Mandarin on the novel coronavirus COVID- research that is available on the COVID-19 resource centre - including this for unrestricted research re-use a. 2020;(January):19–21.
15. Whitworth HB, Sartain SE, Kumar R, Armstrong K, Ballester L, Betensky M, et al. Rate of thrombosis in children and adolescents hospitalized with COVID-19 or MIS-C. *Blood*. 2021;
16. Perveen S, Millington KA, Acharya S, Garg A, Boyar V. Neonate born with ischemic limb to a COVID-19 positive mother: management and review of literature. *Case Reports Perinat Med*. 2021;10(1):1–6.
17. Mamishi S, Heydari H, Aziz-Ahari A, Shokrollahi MR, Pourakbari B, Mahmoudi S, et al. Novel coronavirus disease 2019 (COVID-19) outbreak in children in Iran: Atypical CT manifestations and mortality risk of severe COVID-19 infection. *J Microbiol Immunol Infect Internet*. 2020;2019(xxxx). Available from: <https://doi.org/10.1016/j.jmii.2020.07.019>
18. Odev K, Guler I, Altinok T, Pekcan S, Batur A, Ozbiner H. Cystic and cavitory lung lesions in children: Radiologic findings with pathologic correlation. *J Clin Imaging Sci*. 2013;3(1).

Figure 1 a.

Chest radiograph showing bilateral reticulonodular opacities in the middle and upper zones of the lungs

Figure 1 b,c.

HRCT Coronal and Axial view showing bilateral, multiple, nodular and cavitory lesions in the lungs



Hosted file

Table 1.docx available at <https://authorea.com/users/437160/articles/711694-cavitory-lung-lesions-in-a-neonate-potential-manifestation-of-covid-19-related-multisystem-inflammatory-syndrome>