

Peripheral T-cell Lymphoma of the oral cavity: a case report

Amirali Asadi¹, Hamed Mahmoudi¹, abbas mofidi², Masoud Mortezaadeh¹, and Alireza hadizadeh¹

¹Tehran University of Medical Sciences

²Iran University of Medical Sciences

September 25, 2021

Abstract

In this article, we report a 34-year-old man who presented with a buccal progressive ulcerated lesion which through histopathologic and IHC findings diagnosed as Peripheral T-cell lymphoma.

Introduction:

Lymphoma is a cancer of the lymphatic system which is classified as Hodgkin's lymphoma (HL) and non-Hodgkin's lymphoma (NHL).

Oral lymphomas are the third most common malignancies after squamous cell carcinoma in the oral cavity which accounts for 3% of all lymphomas.[1]

Primary Extranodal lymphoma represents 25-40 % of all non-Hodgkin lymphoma (NHL) [2]

In addition, 2% to 3% of these extranodal cases derive primarily in the oral cavity [3]

And most commonly affects the Waldeyer's ring and only 2% of these tumors are located on the buccal floor. [4]

The most common lineage of lymphomas are B cells (98%), and the majority of these B cells are histologically subtyped as diffuse large B cell lymphoma.[3]

Oral Peripheral T-cell lymphomas (PTCLs) are uncommon subtypes of non-Hodgkin lymphoma (NHL) that only a few cases have been reported in the literature but it should always be considered in the differential diagnosis of oral cavities.

Herein, we describe an extremely rare case of peripheral T-cell lymphoma which derives primarily from buccal mucosa in a 34-year-old patient.

The patient was diagnosed as a PTCLs based on a biopsy and immunohistochemistry and was referred to the oncology department for chemoradiotherapy.

Case presentation:

A 34-year-old man was admitted to the Maxillofacial Surgery department, for evaluation of facial asymmetry due to a painful large lesion over the right cheek which was first noticed by the patient 12 months ago.

The lesion started as a small painful lesion in the right buccal mucosa which progressed gradually and extended to the nasal cavity.

Some local anti-inflammatory and antibiotic treatments which were previously prescribed by general practitioners did not bring the expected therapeutic effect.

The patient denied any B symptoms (fever, weight loss, and night sweats).

His past medical history was unremarkable except opium ingestion a few years ago which through epidemiologic data on that time the oral opiums in Iran were mostly contaminated with lead.

The local examination revealed a firm subcutaneous mass on the right side of the face which was non-mobile and tender on palpation.

Intraoral examination showed an ulceroproliferative lesion in the right buccal mucosa which had an ill-defined, indurated margin and was tender on palpation and also covered with whitish pseudomembrane.

On neck examination, few cervical lymph nodes also were palpable on both sides of the neck.

His blood investigations showed white blood cell (WBC) count 3700/ μ l (neutrophils 87.0% ,lymph 10.0 %); hemoglobin (Hgb) 14.5 g/dl; platelet count (Plt) 1.96×10^4 / μ l, (ESR) 47 mm/h , lactate dehydrogenase (LDH) 420 IU/l (normal range 150–500 U/L)

The patient underwent computed tomography (CT) scan of the oral cavity and neck which revealed

Destructive and expansive soft tissue density with central necrosis in right maxillary sinus extending to the nasal cavity and right ethmoid sinus with the destruction of the lateral wall of maxillary sinus and extension to cheek and buccal area, secretions were also seen in the right sphenoid sinus.

No intraorbital invasion was seen, bilateral mildly enlarged cervical lymph nodes were seen. (figure1)

Due to characteristic features of the imaging and clinical history of the patient's deep cheek (buccal mucosa), a biopsy was performed, and histopathologic and IHC findings were in favor of a rare diagnosis of Peripheral T-cell lymphoma, not otherwise specified (PTCL-NOS). (figure 2)

Immunohistochemical results were as following: LCA+, CD3+, CD7+, CD5 -, CD20 -,CD30- and Ki67 was around 70–80%. (figure 2)

A whole-body bone and CT scan were performed for staging, and imaging findings did not reveal mediastinal or retroperitoneal lymphadenopathy or visceral involvement.

Bone marrow biopsy and cerebrospinal fluid cytology were negative for malignant cells.

Using the Ann Arbor staging, the patient was staged at the I EA level of the disease.

The patient received CHOEP (cyclophosphamide, adriamycin, vincristine, etoposide, prednisone) following radiotherapy.

Discussion :

10 to 15 percent of all patients with NHL have a T-cell lymphoma subtype and Peripheral T-cell lymphomas are one of the uncommon and aggressive subtypes of the NHL.

Despite our Case, PTCLs are most common among people older than 60 years.[5]

The etiology of PTCLs is unknown but some studies demonstrate the possibility of the association between exposure to specific viruses, such as the Epstein-Barr virus (EBV) and the human T-cell leukemia virus-1 (HTLV-1) with PTCLs.[6]

In our case, the blood test results were negative for all HIV Ab, HTLV-1 Ab, EBV VCA-IgM, and IgG.

Rachel S. Kelly, a study showed evidence of an increased risk of NHL or multiple myeloma with exposure to lead, our case also had a history of oral opium ingestion which was highly suspected for contamination with lead. [7]

In contrast to our current case, the most common site of oral lymphoma involvement was the gingiva, and the most frequent symptoms were pain, swelling, ulceration, paresthesia, and palpable lymph nodes. [8]

The International Prognostic Index (IPI) is a scoring system for predicting overall survival which evaluates the patient by age, stage, lymph node involvement, serum lactate dehydrogenase level, and performance status. According to this scoring system, our patient scored 1 point which was identified as a low-intermediate risk. [9]

Despite the IPI low-intermediate risk, the overall 5-year survival rate of PTCL patients is less than 20% and PTCL is considered as an aggressive type of lymphoma.[10]

The recommended regimen for localized extranodal T-cell lymphoma is anthracycline-based

Chemotherapy and radiotherapy, our case also received a CHOEP regimen following radiotherapy.

Therapeutic responses to this approach have been neither adequate nor durable and followed by poor prognosis, so in recent years newer agents like monoclonal antibodies such as alemtuzumab are being investigated for PTCL treatment.[11]

Conclusion:

In brief, our case highlighted the importance of including PTCL in a differential diagnosis of oral malignant lesions, and early identification and prompt referral for Histopathology and immunohistochemistry investigation can lead to early diagnosis and appropriate treatment.

Declarations:

1. Acknowledgements : The authors would like to thank Elham Nazar for her cooperation from pathology department.
2. Funding: Not applicable
3. Conflicts of interest/Competing interests: The authors declare that there is no conflict of interest to declare.
4. Ethics approval: In this study, We reported the retrograde standard treatment process of the patient. We maintained the patient's privacy, and his written consent was obtained.
5. Consent to participate: The patient has consented to the participation of this case report.
6. Consent for publication: The participant has consented to the publication of this case report.
7. Availability of data and material: The data that support the findings of this study are available from the corresponding author, [AM], upon reasonable request.
8. Code availability (Not applicable)
9. Authors' contributions: A.A, A.M., and M.M. contributed to data collection, writing, drafting of the manuscript, and critical appraisal of the manuscript. A.H and H.M contributed to scientific writing and final revision

References :

1. Vigouroux A, Lillo F, Donoso F. Peripheral T-Cell Lymphoma not otherwise specified with oral manifestation: A Case Report. *Journal of Oral Research* 2020(6):516-21%V 9 doi: 10.17126/joral-res.2020.098[published Online First: Epub Date]].
2. Krol AD, le Cessie S, Snijder S, Kluin-Nelemans JC, Kluin PM, Noordijk EM. Primary extranodal non-Hodgkin's lymphoma (NHL): the impact of alternative definitions tested in the Comprehensive Cancer Centre West population-based NHL registry. *Ann Oncol* 2003;**14** (1):131-9 doi: 10.1093/annonc/mdg004[published Online First: Epub Date]].
3. Kemp S, Gallagher G, Kabani S, Noonan V, O'Hara C. Oral non-Hodgkin's lymphoma: review of the literature and World Health Organization classification with reference to 40 cases. *Oral Surg Oral Med Oral*

Pathol Oral Radiol Endod 2008;**105** (2):194-201 doi: 10.1016/j.tripleo.2007.02.019[published Online First: Epub Date]].

4. Slootweg PJ, Wittkamp AR, Kluin PM, de Wilde PC, van Unnik JA. Extranodal non-Hodgkin's lymphoma of the oral tissues. An analysis of 20 cases. *J Maxillofac Surg* 1985;**13** (2):85-92 doi: 10.1016/s0301-0503(85)80022-9[published Online First: Epub Date]].

5. Imamura H, Kashima Y, Hattori M, Mori K, Takeshige K, Nakazawa H. Unexplained recurrent shock in peripheral T-cell lymphoma: A case report. *Clinical Case Reports* 2021;**9** (8):e04612 doi: <https://doi.org/10.1002/ccr3.4612>[published Online First: Epub Date]].

6. Bibas M, Antinori A. EBV and HIV-Related Lymphoma. *Mediterr J Hematol Infect Dis* 2009;**1** (2):e2009032-e32 doi: 10.4084/MJHID.2009.032[published Online First: Epub Date]].

7. Kelly RS, Lundh T, Porta M, et al. Blood erythrocyte concentrations of cadmium and lead and the risk of B-cell non-Hodgkin's lymphoma and multiple myeloma: a nested case-control study. *PLoS One* 2013;**8** (11):e81892-e92 doi: 10.1371/journal.pone.0081892[published Online First: Epub Date]].

8. Tseng C-H, Wang W-C, Chen C-Y, Hsu H-J, Chen Y-K. Clinical manifestations of oral lymphomas – Retrospective study of 15 cases in a Taiwanese population and a review of 592 cases from the literature. *Journal of the Formosan Medical Association* 2021;**120** (1, Part 2):361-70 doi: <https://doi.org/10.1016/j.jfma.2020.05.025>[published Online First: Epub Date]].

9. Gallamini A, Stelitano C, Calvi R, et al. Peripheral T-cell lymphoma unspecified (PTCL-U): a new prognostic model from a retrospective multicentric clinical study. *Blood* 2004;**103** (7):2474-9 doi: 10.1182/blood-2003-09-3080[published Online First: Epub Date]].

10. Santos H, Alves C, Mattos R, Curi D, Leite-Ribeiro P, Sarmiento V. Peripheral T-cell non-Hodgkin lymphoma manifesting as a primary lesion on the lip: A rare case report. *Special Care in Dentistry* 2018;**38** doi: 10.1111/scd.12333[published Online First: Epub Date]].

11. Zhang Y, Xu W, Liu H, Li J. Therapeutic options in peripheral T cell lymphoma. *J Hematol Oncol* 2016;**9** :37-37 doi: 10.1186/s13045-016-0267-0[published Online First: Epub Date]].

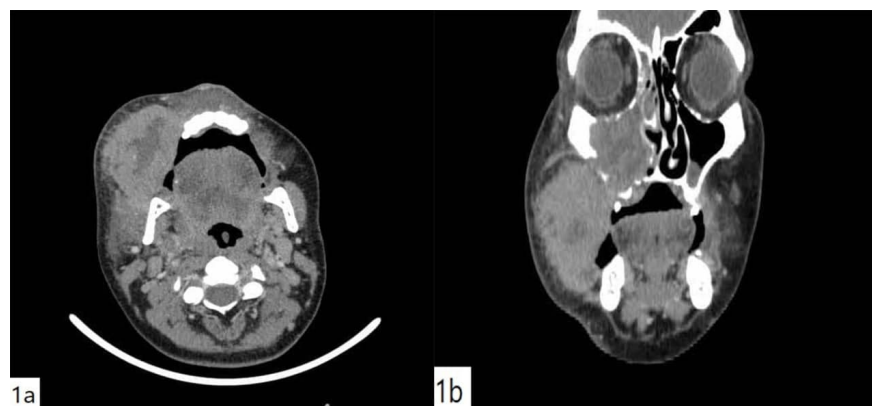


Figure 1: CT scan imaging showed Destructive and expansive mass with central necrosis with extension to maxillary and ethmoid sinuses .

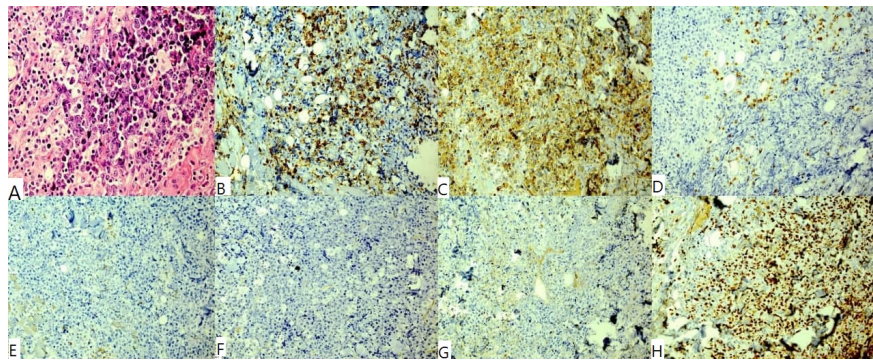


Figure 2 : Pathology and IHC of Peripheral T-cell lymphoma, not otherwise specified (PTCL-NOS) , (A)H&E , (B)LCA+, (C) CD3+, (D)CD7+, (E)CD5- , (F) CD20-, (G)CD30-, (H)Ki67 :70-80%



