

Cytarabine-induced pericarditis confirmed using cardiac MRI after inconclusive echocardiography: A case report

Tony Dong¹, Tarek Chami¹, Beshar Chami², Sadeer Al-Kindi¹, and Brian Hoit¹

¹University Hospitals of Cleveland

²University of Aleppo Faculty of Medicine

March 5, 2021

Abstract

Pericarditis is a rare but debilitating complication of cytarabine therapy. While echocardiography can aid with the diagnosis, cardiac MRI has superior accuracy in establishing the diagnosis. In this case, we describe a 65-year-old patient receiving cytarabine as part of induction chemotherapy for acute myeloid leukemia who developed acute pericarditis. Her cardiac MRI revealed pericardial edema on T2-weighted STIR imaging and pericardial late gadolinium enhancement which confirmed the diagnosis.

Introduction:

Cytarabine is a cytosine analogue chemotherapy agent often used in the treatment of leukemias and lymphomas. Commonly reported side-effects include myelosuppression, gastrointestinal toxicity, and neuropathy. There have been reported cases of cytarabine induced pericarditis, although it is not typically thought to be cardiotoxic. Here, we present a case of cytarabine induced pericarditis diagnosed with cardiac magnetic resonance (CMR).

Case Presentation:

A 65-year-old previously healthy woman presented to an outside hospital for scheduled left hip replacement surgery. An incidental finding of leukocytosis, anemia, and thrombocytopenia led to a bone marrow biopsy, which revealed acute myeloid leukemia with monocytic differentiation. She was transferred to University Hospitals Cleveland Medical Center for induction of chemotherapy. Prior to the initiation of chemotherapy, an echocardiogram showed an LV ejection fraction of 65-70%, global longitudinal strain of -20.4%, concentric remodeling, and impaired diastolic filling. Idarubicin and cytarabine were started at standard doses and midostaurin was started on day 8 of induction chemotherapy as part of the 7+3 regimen (which consists of 7 days of cytarabine at 100 mg/m² of IV continuous infusion, and 3 days of idarubicin at 12 mg/m² of IV bolus). The hospital course was complicated by culture negative neutropenic fevers on day 8 and day 12. On day 13, the patient developed constant pleuritic chest pain radiating to the mid-back. A transient friction rub was auscultated on exam. Electrocardiogram (EKG) showed widespread ST-segment elevation and PR depression (Figure 1). Troponin was 0.02 ng/ml (reference range: 0.00-0.03 ng/ml). For definitive diagnosis, a CMR was performed, which revealed preserved LV and RV function with pericardial edema on T2-weighted Short Tau Inversion Recovery (STIR) images as well as pericardial late gadolinium enhancement on Phase Sensitive Inversion Recovery (PSIR) images, consistent with pericarditis (Figure 2, 3). The patient had been

receiving solumedrol and morphine, and his symptoms resolved within 24 hours of onset. He was started on colchicine 0.6 mg daily for the remainder of the hospital course and was discharged on colchicine on hospital day 21, finished a 3-month course, and remained symptom-free at follow-up clinic visits without recurrence of pericarditis.

Discussion:

Cytarabine-induced pericarditis is a rare but serious complication that may occur especially with high doses. The incidence of this condition remains unknown, but several case reports have described this syndrome occurring sub-acutely between 3- and 28-days following initiation of chemotherapy (1). We reviewed nine case reports published in PubMed (7-15), all of which arrived at the diagnosis using echocardiography, with 3 patients also requiring diagnostic pericardiocentesis and 1 patient requiring endomyocardial biopsy (Table 1). To our knowledge, there have been no cases of cytarabine-induced pericarditis that have been confirmed by CMR.

CMR is a valuable tool for investigating pericardial disease, with class I indications for evaluating pericardial inflammation, constriction, and congenital anomalies (2). In our patient, the index of suspicion was very high for pericarditis given the pleuritic chest pain, pericardial rub, and diffuse ST segment elevation. Pericarditis may be associated with no or trivial pericardial effusions in about 40% percent of patients (5, 6). We decided to proceed with CMR for a more definitive assessment of the patient's chest pain, as cytarabine is an uncommon cytotoxic agent and the concern for myocardial involvement. Further evaluation with CMR revealed diagnostic findings of pericardial edema and late gadolinium enhancement, which confirmed the diagnosis of pericarditis with no apparent myocardial injury, most likely secondary to cytarabine toxicity given the temporal proximity to its dispensation. Echocardiography is appropriate as the initial imaging modality in the diagnosis of pericarditis, as it is highly sensitive for identifying pericardial effusions and excluding other pathologies. However, CMR can play a role in further workup, especially in the absence of a clear pericardial effusion and inconclusive echocardiographic findings. CMR has several advantages in that it can detect small pericardial effusions that may be missed on echocardiography and characterize the fluid composition (4). Other characteristic findings of pericarditis on CMR include pericardial thickening, pericardial edema, and pericardial inflammation. The sensitivity of late gadolinium enhancement detection of pericardial inflammation has been reported to be as high as 94-100% (14,15).

Conclusion:

We present a case of a 65-year-old woman with cytarabine induced pericarditis that was confirmed with CMR. CMR is a sensitive imaging modality for detection of pericarditis in cases when echocardiography is inconclusive despite a strong clinical suspicion. The use of CMR in the setting of cytarabine induced pericarditis has not been published in the literature, so this case presentation may offer valuable insight for other practitioners.

References:

1. Pai, V. B., & Nahata, M. C. (2000). Cardiotoxicity of Chemotherapeutic Agents. *Drug Safety*, 22(4), 263–302.
2. Leiner, T., Bogaert, J., Friedrich, M.G. et al. SCMR Position Paper (2020) on clinical indications for cardiovascular magnetic resonance. *J Cardiovasc Magn Reson* **22**, 76 (2020).
3. Imazio, M., Demichelis, B., Parrini, I., Giuggia, M., Cecchi, E., Gaschino, G., ... Trinchero, R. (2004). Day-hospital treatment of acute pericarditis. *Journal of the American College of Cardiology*, 43(6), 1042–1046.
4. Klein, A. L., Abbata, S., Agler, D. A., Appleton, C. P., Asher, C. R., Hoit, B., ... White, R. D. (2013). American Society of Echocardiography Clinical Recommendations for Multimodality Cardiovascular

- Imaging of Patients with Pericardial Disease. *Journal of the American Society of Echocardiography*, 26(9), 965–1012.e15.
5. Yang, X., Liu, W., Lyons, A., Song, Z., Zhai, S., & Hu, K. (2017). Pericarditis associated with cytarabine therapy for acute myelocytic leukemia: a case report. *European Journal of Clinical Pharmacology*, 74(2), 181–182.
 6. Mikolich J, Kley J, Boniface N et al. Are new diagnostic criteria for pericarditis needed? *J Am Coll Cardiol*. 2014;63(12_S).
 7. Reykdal, S., Sham, R., & Kouides, P. (1995). Cytarabine-induced pericarditis: A case report and review of the literature of the cardio-pulmonary complications of cytarabine therapy. *Leukemia Research*, 19(2), 141–144.
 8. Yamada T, Tsurumi H, Hara T, Sawada M, Oyama M, Moriwaki H. [Cytarabine-induced pericarditis]. *Rinsho Ketsueki*. 1998 Nov;39(11):1115-20. Japanese. PMID: 9866424.
 9. Gähler, A., Hitz, F., Hess, U., & Cerny, T. (2003). Acute Pericarditis and Pleural Effusion Complicating Cytarabine Chemotherapy. *Oncology Research and Treatment*, 26(4), 348–350.
 10. Woods T, Vidarsson B, Mosher D, Stein JH. Transient effusive-constrictive pericarditis due to chemotherapy. *Clin Cardiol*. 1999 Apr;22(4):316-8.
 11. Hermans, C., Straetmans, N., Michaux, J.-L., & Ferrant, A. (1997). Pericarditis induced by high-dose cytosine arabinoside chemotherapy. *Annals of Hematology*, 75(1-2), 55–57.
 12. Hengel, C. L., Russell, P. A., Gould, P. A., & Kaye, D. M. (2006). Subacute Anthracycline Cardiotoxicity. *Heart, Lung and Circulation*, 15(1), 59–61.
 13. Sato M and Park M: Case Report: Cytarabine-Induced Pericarditis and Pericardial Effusion. *The Medicine Forum* 2017; 10
 14. Young PM, Glockner JF, Williamson EE, Morris MF, Araoz PA, Julsrud PR, Schaff HV, Edwards WD, Oh JK, Breen JF. MR imaging findings in 76 consecutive surgically proven cases of pericardial disease with CT and pathologic correlation. *Int J Cardiovasc Imaging*. 2012 Jun;28(5):1099-109.
 15. Taylor AM, Dymarkowski S, Verbeke EK, Bogaert J. Detection of pericardial inflammation with late-enhancement cardiac magnetic resonance imaging: initial results. *Eur Radiol*. 2006 Mar;16(3):569-74.

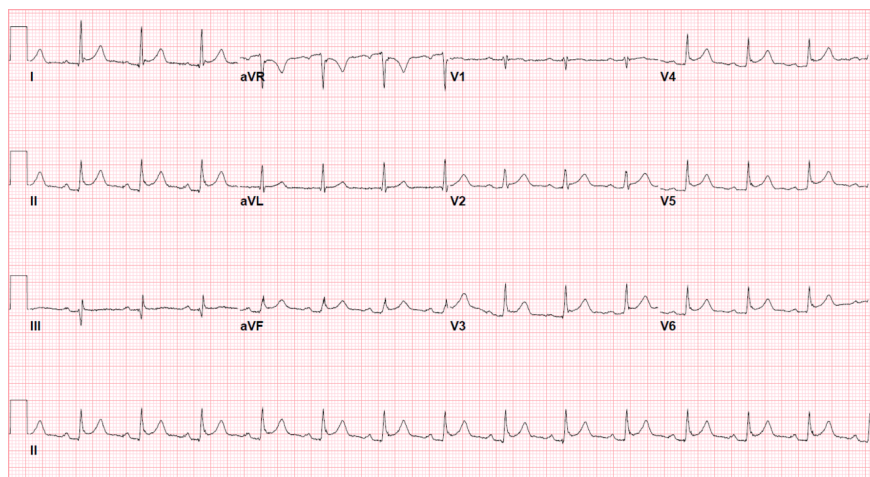


Figure 1. EKG obtained at the onset of chest pain showing widespread ST elevation (blue arrows) and PR depression (red arrows).

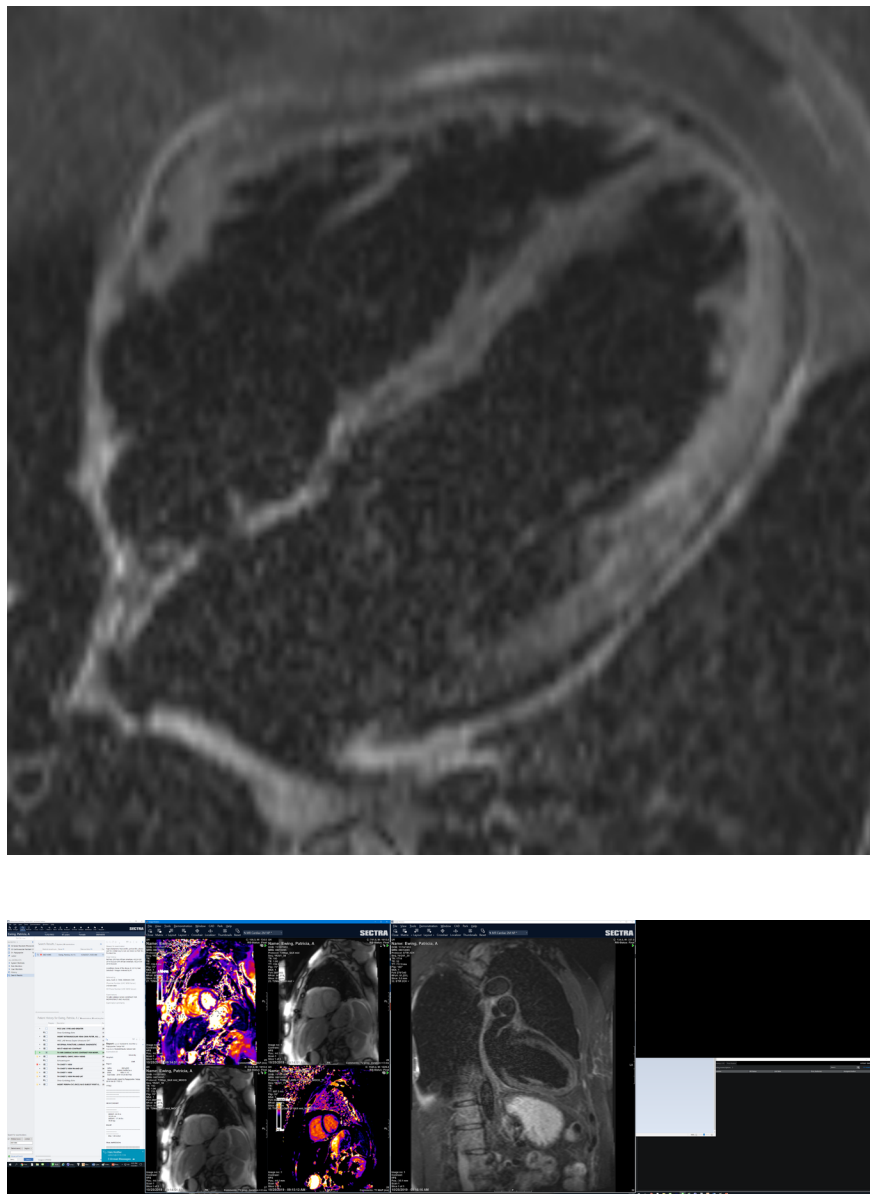
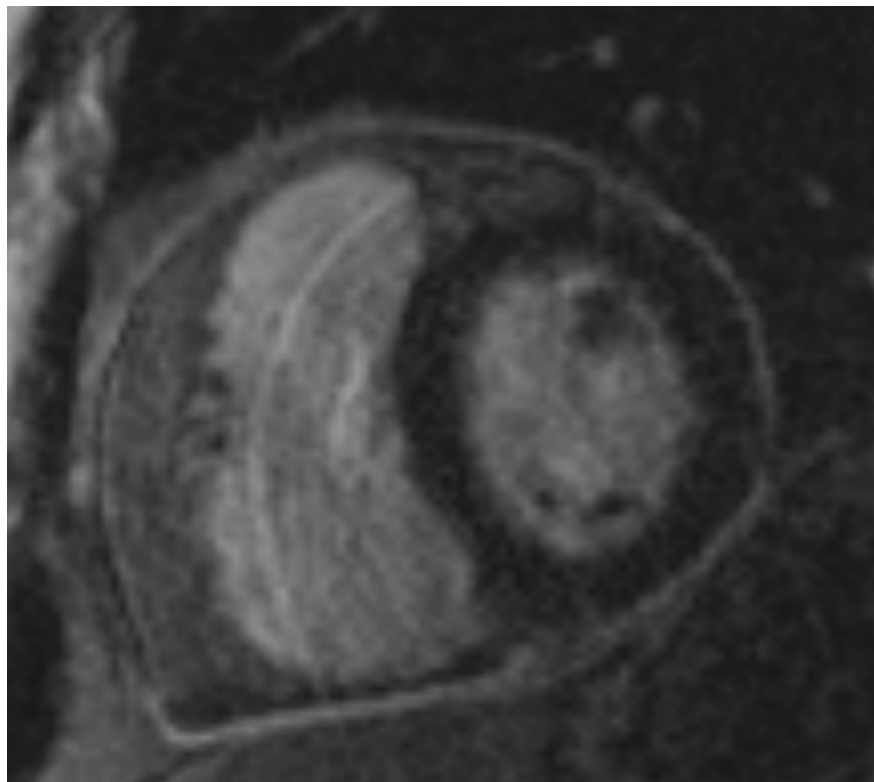


Figure 2. CMR STIR T2-weighted images showing pericardial edema (white arrows).



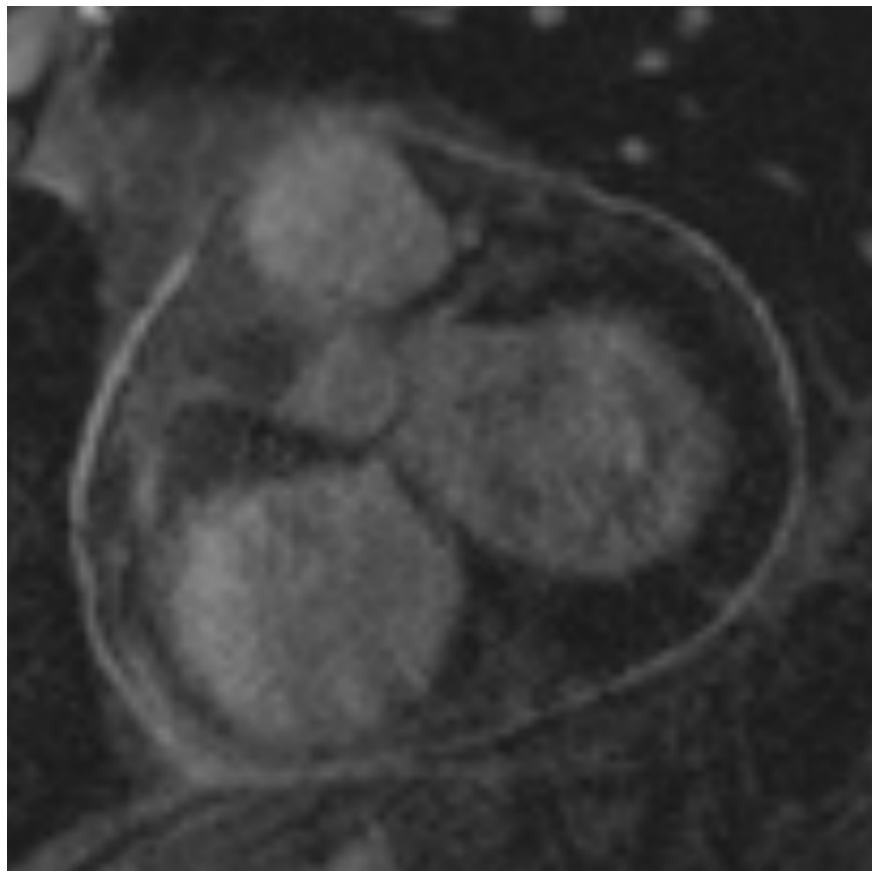


Figure 3. CMR PSIR images showing pericardial late gadolinium enhancement (white arrows).