

# Incidental diagnosis of haemophilia: a report of three cases following voluntary medical male circumcision in South Africa

Donna Jacobs<sup>1</sup>, Carla Visser<sup>2</sup>, Freck Dikgale<sup>1</sup>, Ngoanamathiba Molepo<sup>3</sup>, Raymond Mabuse<sup>1</sup>, and James Ndirangu<sup>4</sup>

<sup>1</sup>University Research Co LLC

<sup>2</sup>RTI International

<sup>3</sup>Department of Health

<sup>4</sup>University of the Free State Faculty of Health Sciences

May 18, 2020

## Abstract

Medical male circumcisions have been scaled-up for HIV prevention. Three 16-year-old clients were diagnosed with Haemophilia post-VMC services. Greater emphasis on advocacy, training and placement of qualified health care workers for peri-operative screening and a high index of suspicion for pre-operative diagnosis and appropriate referral for bleeding disorders is essential.

## Hosted file

Hemophilia\_VMMC\_manuscript\_revised.docx available at <https://authorea.com/users/323443/articles/452143-incident-diagnosis-of-haemophilia-a-report-of-three-cases-following-voluntary-medical-male-circumcision-in-south-africa>

## Hosted file

Tables 1-3.docx available at <https://authorea.com/users/323443/articles/452143-incident-diagnosis-of-haemophilia-a-report-of-three-cases-following-voluntary-medical-male-circumcision-in-south-africa>

Figure 1: Number of VMs reported (May 2017-September 2018)

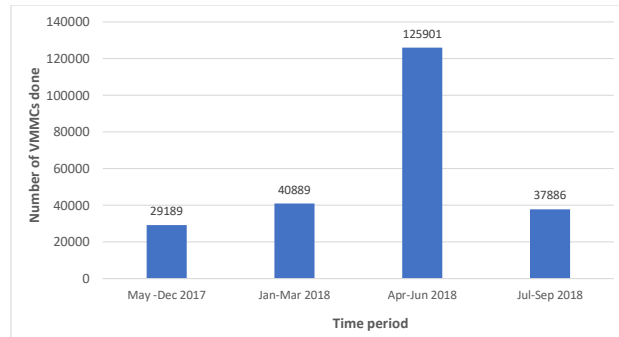


Figure 2: Management of intra-operative and immediate post-operative bleeding

