

En bloc resection of a T4B stage cancer of the hepatic flexure of the colon invading the liver, gall bladder, and pancreas/duodenum – a case report

meng linghou¹, mo xianwei¹, liu jungang¹, lai hao¹, zuo hongqun¹, huang zigao¹, liao jiankun¹, and lin yuan¹

¹Affiliation not available

May 12, 2020

Abstract

Colon cancer is a highly prevalent disease worldwide, and approximately 15% of patients present with locally advanced tumors (T4 stage). En bloc resection of the tumor is of pivotal importance and is associated with a highly significant improvement in 5-year survival.

Introduction

Colon cancer is a highly prevalent disease worldwide, with approximately 15% of patients presenting with locally advanced tumors (T4 stage) [1]. Resection of a T4 colon cancer can be difficult if the tumor directly invades other organs or structures (T4B stage) [2]. T4B hepatic flexures of colon cancer most commonly invade the liver, gall bladder, and pancreas/duodenum, and radical surgery is the only way to cure this disease[3].

The en bloc resection for a T4B hepatic flexure of colon cancer is associated with a high perioperative mortality and morbidity[4]. The decision to perform an en bloc resection is often made during the operation, due to the lack of exact preoperative data. Therefore, these resections are challenging, even for an experienced colorectal surgeon.

The aim of this study was to determine the immediate surgical outcome and recovery of bowel function following a D3 expanded right hemicolectomy + pancreaticoduodenectomy + sectional VI and VII hepatic segmentectomy for a T4B hepatic flexure of colon cancer that had invaded the liver, gall bladder, and pancreas/duodenum.

Case report

A 54-year-old man was admitted to the Affiliated Hospital of Guangxi Medical University in August 2018, presenting with a 2-month history of hypodynamics accompanied by poor appetite and weight loss (15 kg). The patient had no significant medical history and no family history of cancer, and he was a non-smoker. A physical examination revealed no deep tenderness at the left lower quadrant of the abdomen and no rebound tenderness on palpation. Laboratory data revealed glandular tumor markers: (CEA) 7.3 ng/ml; (AFP) 1.74 ng/ml; (CA125) 12.3 U/ml; (CA15-3) 15.1 U/ml; and (CA19-9) 180.7 U/ml. Histopathology revealed hepatic curve ascending colon (5 points), tubular-villous adenoma, partial regional carcinogenesis, and highly differentiated intramucosal adenocarcinoma. Computed tomography (CT) of the abdomen revealed the possibility of colorectal cancer invading the liver, gall bladder, and pancreas/duodenum (Figure1). Colonoscopy

identified a tumor located in the hepatic flexure of the colon (Figure 2). The diagnosis of colon cancer was confirmed by histopathological examination.

The patient underwent four rounds of chemotherapy, subsequent to 4 months of follow up examinations by CT and colonoscopy. The tumor exhibited stabilized disease (SD). However, an abdominal X-ray revealed an incomplete ileus (Figure 3).

Laboratory tests revealed the following blood and routine liver and kidney function data: (WBC) $3.02 \times 10^9/L$;* (RBC) $3.41 \times 10^{12}/L$;* (HGB) 80 g/L; (HCT) 25.5%;* (MCV) 74.6 fL;* (MCH) 23.5 pg;* (MCHC) 315 g/L; (IBIL) 4.3 $\mu\text{mol}/L$; (TRF) 1.5 g/L;* (TP) 51 g/L;* (ALB) 29.9 g/L;* (GLO) 21.1 g/L; and (RBP) 15.3 mg/L. The following glandular tumor markers were detected: (CEA) 7.77 ng/ml; (AFP) 2.33 ng/ml; (CA125) 32.5 U/ml; (CA15-3) 15.2 U/ml; (CA19-9) 357.3 U/ml; and (PA): 108.9 mg/L. Preoperative examination showed that the patient had poor nutritional status and an intestinal obstruction. Preoperative supplementation with human serum albumin and parenteral nutrition improved the nutritional status of the patient, and he eventually underwent surgery.

Surgical procedures

The tumor was located in the hepatic flexure of the colon, with adhesion to the right side of the descending part of the duodenum, and had invaded the right lobe of the liver. We could not resect the tumor using a common procedure. We dissected the right side of the hepatoduodenal ligament, and opened the hepatogastric ligament beside hepatoduodenal ligament, from left to right by using a thumb, to determine if the tumor had invaded the right side of the portal vein. We then we opened the ascending colon paracolic sulci, dissected the portal vein beside the pancreas/duodenum and Toldt's fascia, and confirmed that the tumor had not invaded post cava.

We then dissected the right hemicolon Toldt's fascia, beside the ileocolonic vessels and in front of the superior mesenteric artery, and confirmed that the tumor had not invaded the superior mesenteric vein.

We performed a D3 expanded right hemicolectomy + pancreaticoduodenectomy + sectional VI and VII hepatic segmentectomy en-bloc resection on this patient (Figure 4). During the procedure, we paid attention to whether the tumor had invaded the superior mesenteric vein and post cava. Postoperative amylase levels were continuously monitored in the abdominal drainage tube and t-tube drainage fluid for 5 days.

The information regarding the abdominal drainage tube is listed in table 1. Postoperative pathology: 1. (right semicolon) medium-poorly differentiated tubular adenocarcinoma, mass infiltration type, size $6 \times 5 \times 4.5$ cm, carcinoma tissue had infiltrated the whole layer of the intestinal wall and had broken through the serosal layer; carcinoma tissue had invaded the liver, gallbladder, pancreas, and duodenum; Microscopy examination revealed a partial necrosis and focal calcification, as well as a vascular carcinoma thrombus and nerve invasion. Chronic inflammation of the colonic mucosa was noted. The samples of the stomach, ileum, and appendix showed chronic inflammation of the mucosa, but no cancer. 2. The pancreatic resection margin was positive. The liver, stomach, duodenum, ileum, and colon were all negative. 3. Four of four lymph nodes (12 groups) and 13 of 22 lymph nodes (mesenteric lymph nodes) were examined for metastatic carcinoma with a maximum diameter of 1.3cm; an additional 2 nodules of carcinoma were noted.

The recovery of the patient was uneventful after 3 months of follow-up.

Discussion

En bloc resection is sometimes required to cure T4B stage colorectal cancer[5]. Many investigators have reported that this resection for colorectal cancer has acceptable morbidity and mortality rates and a fair long-term prognosis; therefore, they have emphasized the benefits of this procedure[4]. However, a highly extended operation like an en bloc resections is also recognized to increase morbidity and mortality. Some large tumors that have invaded neighboring organs, such as the pelvic organs and pancreas, are unresectable because of the dangers posed by high surgical stress[6].

To date, several studies have reported the En bloc resection for T4B colorectal cancer that has invaded adjacent organs, such as the urinary bladder[7], anal sphincter[8], and liver[9]. However, very few studies have reported the MVR for T4B colorectal cancer that has invaded the right hepatic lobe, gastric antrum, and duodenum. Our study showed that performing a right hemicolectomy and pancreaticoduodenectomy was safe for these patients.

The combination of the analyzed factors associated with the MVR or other factors related to the MVR, such as the number of anastomoses and width of dissection, could be speculated to affect the occurrence of complications. Reducing the mortality and morbidity rate is challenging. Some studies have showed that en bloc resections increased the rates of infectious complications and ileus, but not other noninfectious complications[10]. Other studies have showed that tumor size and depth of invasion, both of which were associated with en-bloc resection, are independent risk factors, although in combination they might influence morbidity[11]. In our study, we found no postoperative morbidity, anastomotic leakage, or postoperative infection.

For T4B colorectal cancer, we emphasize that en-bloc resection of the tumor and the adjacent infiltrated organs is advisable in suitable patients, in order to avoid jeopardizing complete tumor excision in a patient who has a realistic chance of cure.

In conclusion, to achieve better oncologic outcome, en bloc colorectal cancer resection should be performed. Admittedly, some patients may be over treated by this aggressive approach; however, when practiced by experienced surgeons, en bloc resection usually carries no added morbidity and guarantees a better oncologic outcome.

Conclusions

In order to achieve a better oncologic outcome, en bloc multivisceral resections should be performed for T4B stage colorectal cancer, and this procedure should be undertaken by experienced surgeons.

Abbreviations

CT: Computed Tomography;

SD: Stabilized Disease;

CEA: Carcinoembryonic Antigen;

AFP: Alpha Fetoprotein;

CA125: Carbohydrate Antigen 125;

CA19-9: Carbohydrate Antigen 19-9;

CA15-3: Carbohydrate Antigen 15-3;

Acknowledgments

This study was funded by Guangxi department of science and technology project (GuikeAB16380202).

Authors' contributions

All authors were involved in the preparation of this manuscript. LH M and JX wrote the manuscript. DL collected the tissue sample. HL performed the histopathological investigations. and revised the manuscript. XW M, JG L, HQZ and YL has performed clinical supervision of the case and revised the manuscript. All authors read and approved the final manuscript.

Availability of data and materials

The datasets used and/or analyzed during the current study are available from the corresponding author on reasonable request.

Ethics approval and consent to participate

Ethical approval was obtained from the ethics committee of Guangxi Cancer Hospital to report a case to describe En bloc resection of a T4B stage cancer of the hepatic flexure of the colon invading the liver, gall bladder, and pancreas/duodenum (register number LW2019047). Informed consent was obtained from the patient for case description and photo material.

Consent for publication

We obtained the patient's consent for publication.

Competing interests

The authors declare that they have no competing interests.

Reference

1. Bray F, Ferlay J, Soerjomataram I, Siegel RL, Torre LA, Jemal A: **Global cancer statistics 2018: GLOBOCAN estimates of incidence and mortality worldwide for 36 cancers in 185 countries.** *CA Cancer J Clin* 2018, **68**: 394-424.
2. Osseis M, Esposito F, Lim C, Doussot A, Lahat E, Fuentes L, Moussallem T, Salloum C, Azoulay D: **Impact of postoperative complications on long-term survival following surgery for T4 colorectal cancer.** *BMC Surg* 2018, **18**: 87.
3. Park JS, Huh JW, Park YA, Cho YB, Yun SH, Kim HC, Lee WY, Chun HK: **Clinically suspected T4 colorectal cancer may be resected using a laparoscopic approach.** *BMC Cancer* 2016, **16**: 714.
4. Yang ZF, Wu DQ, Wang JJ, Lv ZJ, Li Y: **Short- and long-term outcomes following laparoscopic vs open surgery for pathological T4 colorectal cancer: 10 years of experience in a single center.** *World J Gastroenterol* 2018, **24**: 76-86.
5. Huh JW, Kim HR: **The feasibility of laparoscopic resection compared to open surgery in clinically suspected T4 colorectal cancer.** *J Laparoendosc Adv Surg Tech A* 2012, **22**: 463-467.
6. Chen YG, Liu YL, Jiang SX, Wang XS: **Adhesion pattern and prognosis studies of T4N0M0 colorectal cancer following en bloc multivisceral resection: evaluation of T4 subclassification.** *Cell Biochem Biophys* 2011, **59**: 1-6.
7. van den Heijkant F, Vermeer TA, Vrijhof E, Nieuwenhuijzen GAP, Koldewijn EL, Rutten HJT: **Psoas hitch ureteral reimplantation after surgery for locally advanced and locally recurrent colorectal cancer: Complications and oncological outcome.** *Eur J Surg Oncol* 2017, **43**: 1869-1875.
8. Mahteme H, Pahlman L: **Good colorectal cancer surgery.** *Tech Coloproctol* 2005, **9**: 1-7.
9. Kishiki T, Lapin B, Matsuoka H, Watanabe T, Takayasu K, Kojima K, Sugihara K, Masaki T: **Optimal Surveillance Protocols After Curative Resection in Patients With Stage IV Colorectal Cancer: A Multicenter Retrospective Study.** *Dis Colon Rectum* 2018, **61**: 51-57.
10. Zhang XM, Fournel L, Lupo A, Canny E, Bobbio A, Lasry S, Regnard JF, Sailhan F, Alifano M: **En-bloc resection of thoracic tumors invading the spine: a single-center experience.** *Ann Thorac Surg* 2019.
11. Chapelier A, Fadel E, Macchiarini P, Lenot B, Le Roy Ladurie F, Cerrina J, Darteville P: **Factors affecting long-term survival after en-bloc resection of lung cancer invading the chest wall.** *Eur J Cardiothorac Surg* 2000, **18**: 513-518.

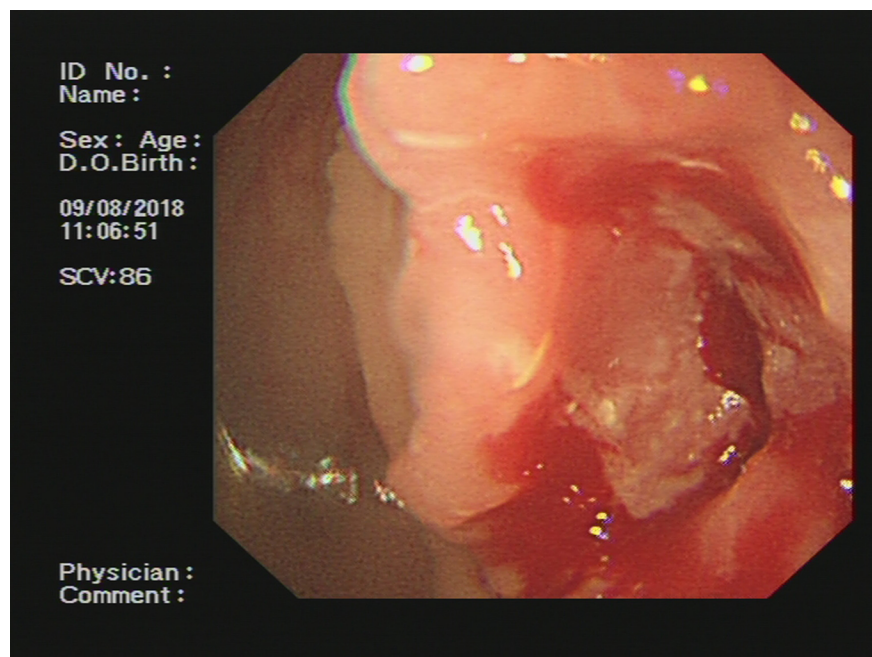
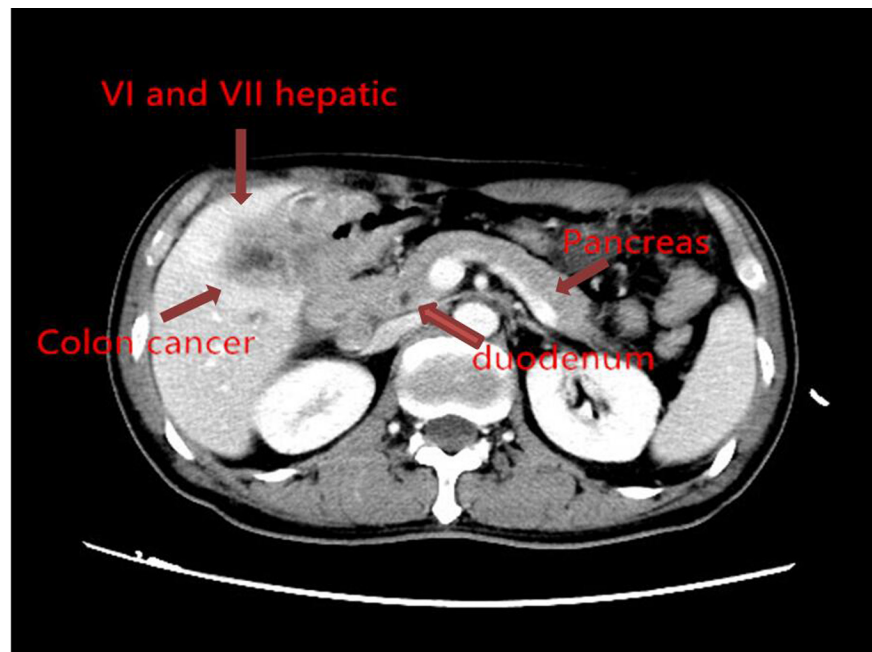
Figure legends

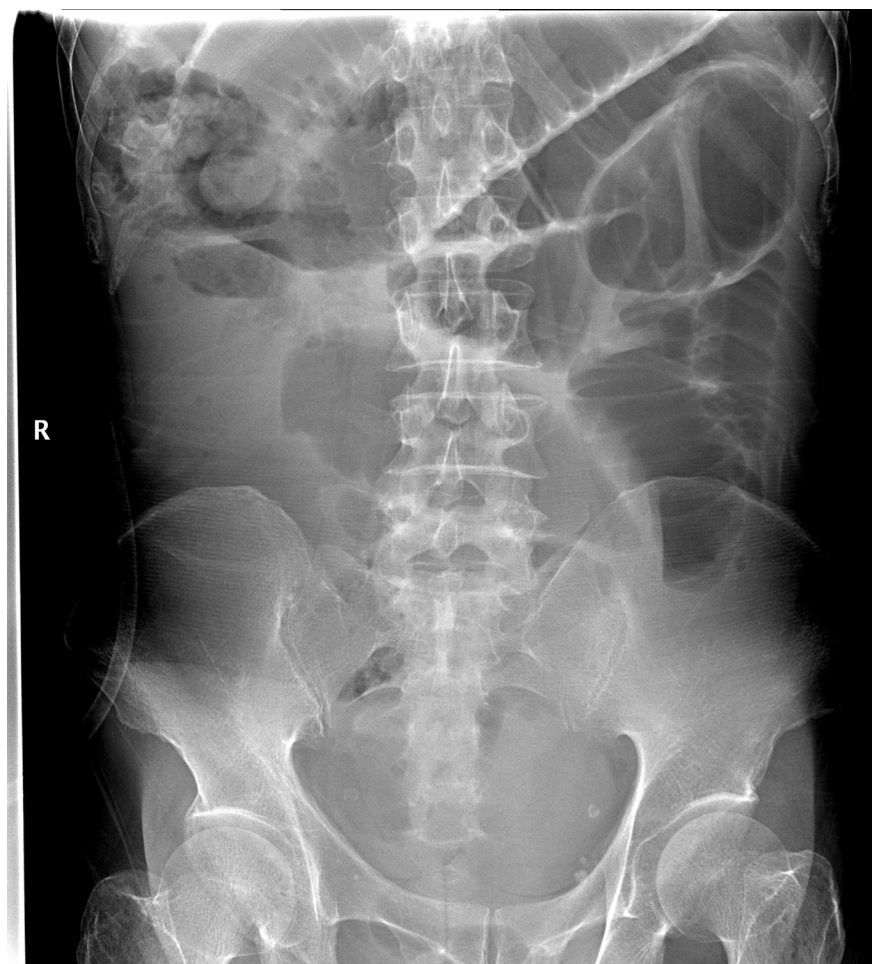Figure 1. Colorectal cancer invading the liver, gall bladder, and pancreas/duodenum;

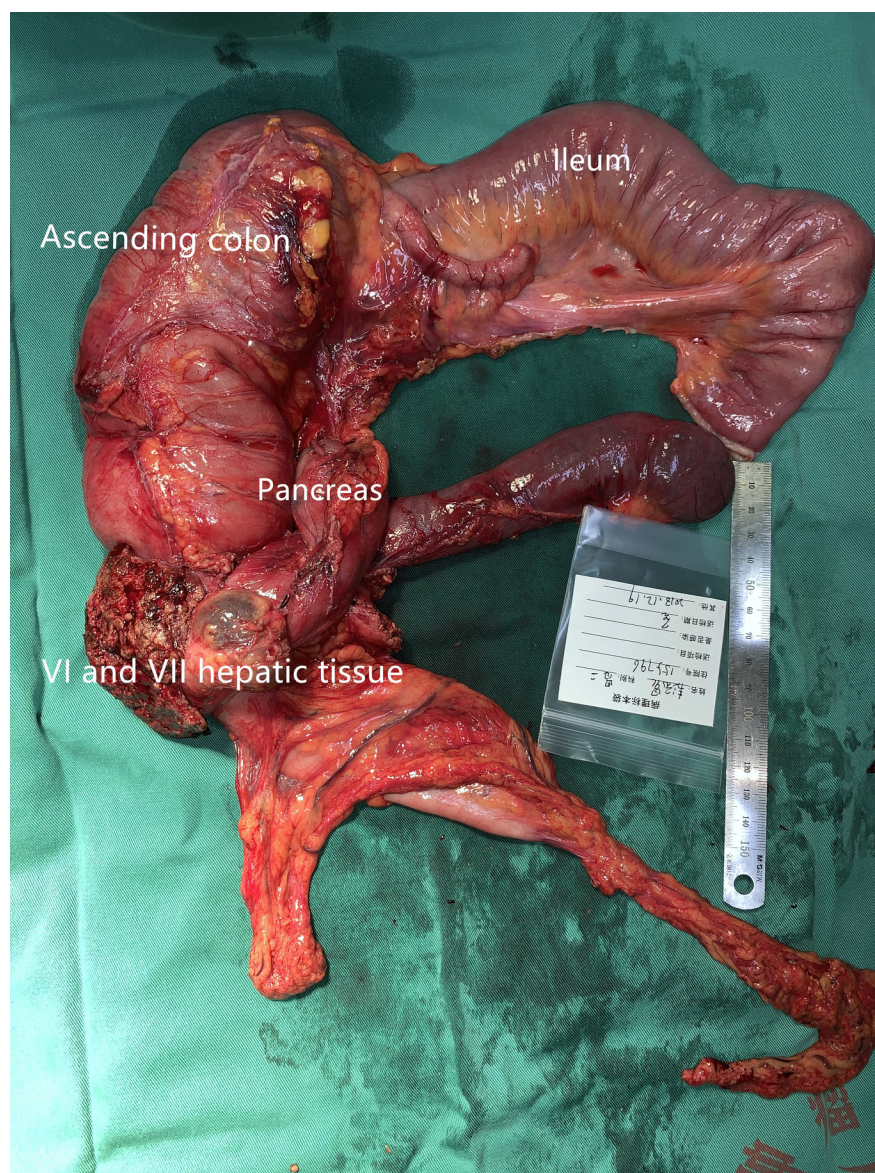
Figure 2. Colonoscopy identified a tumor located in the hepatic flexure of the colon;

Figure 3. Abdominal X-ray revealed an incomplete ileus;

Figure 4. En-bloc resection the tumor







Hosted file

Table 1.docx available at <https://authorea.com/users/321000/articles/450365-en-bloc-resection-of-a-t4b-stage-cancer-of-the-hepatic-flexure-of-the-colon-invading-the-liver-gall-bladder-and-pancreas-duodenum-a-case-report>