

A Case of a Supercharged Compound Flap for Necrotizing Soft Tissue Infection

Kiichi Furuse¹, Motoi Kato¹, Yuya Morishita¹, Tomoyo Kumagai¹, Shuichi Nakatsukasa¹, and Tomoyuki Kuwata¹

¹Asahi General Hospital

May 7, 2020

Abstract

In this report, we present a case of the Superficial circumflex iliac perforator-intercostal artery perforator (SCIP-ICAP) compound flap after extensive debridement of the upper extremity with necrotizing soft tissue infection (NSTI). There has been no previous report of the SCIP-ICAP compound flap applied for the upper extremity with NSTI.

Hosted file

YH.doc available at <https://authorea.com/users/319258/articles/448981-a-case-of-a-supercharged-compound-flap-for-necrotizing-soft-tissue-infection>

Fig. 1

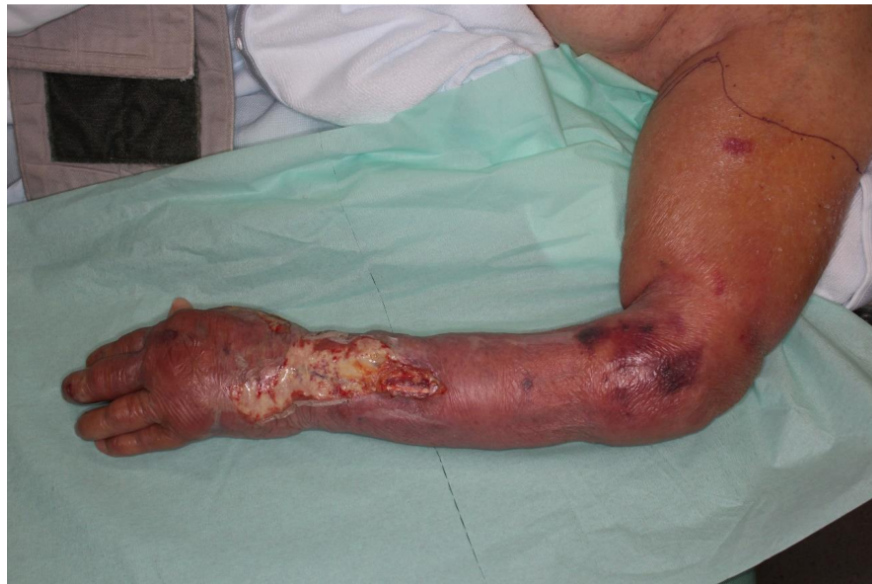

Fig. 2

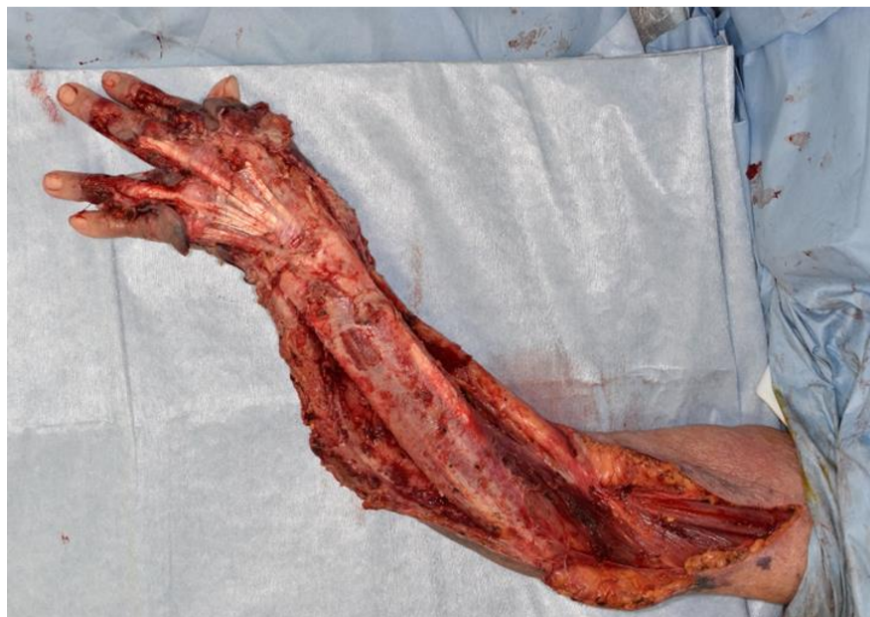

Fig. 3

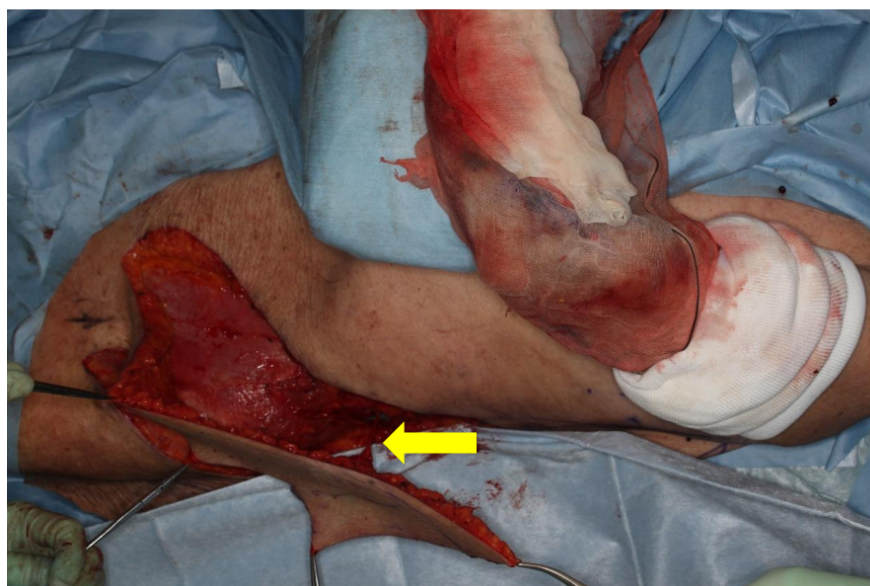


Fig. 4

